

Calcifying cystic odontogenic tumor accompanied by a dentigerous cyst: A case report

SHOKO GAMOH¹, HIRONORI AKIYAMA¹, CHISATO FURUKAWA², YUKI MATSUSHIMA², TOMIO ISEKI²,
MASAHIRO WATO³, AKIO TANAKA³, SHOSUKE MORITA² and KIMISHIGE SHIMIZUTANI¹

¹Department of Oral Radiology; ²First Department of Oral and Maxillofacial Surgery, Osaka Dental University, Osaka 540-0008; ³Department of Oral Pathology, Osaka Dental University, Osaka 573-1121, Japan

Received December 29, 2015; Accepted July 5, 2017

DOI 10.3892/ol.2017.6993

Abstract. A calcifying cystic odontogenic tumor (CCOT) is a proliferation of odontogenic epithelium and scattered nests of ghost cells and calcifications that may form the lining of a cyst, or present as a solid mass. It was previously described by Gorlin *et al* in 1962 as a calcifying odontogenic cyst. Dentigerous cysts are developmental odontogenic jaw cysts, commonly manifesting in the second and third decades of life. The present study reports an asymptomatic case in a 13-year-old boy who was referred to the outpatient clinic of the Osaka Dental University Hospital (Osaka, Japan) for additional investigation of an area of radiolucency in the lower right jaw. X-ray demonstrated a unilocular, well-circumscribed, radiolucent lesion in the mandible, which measured 30x20 mm, with radiopaque structures within it. Enucleation of the lesion with tooth extraction was performed, which histopathologically revealed features of a CCOT and a cyst. To the best of our knowledge, the occurrence of such a lesion has not been previously identified. The present study examined the significance of the case with a brief review of the literature.

Introduction

Calcifying cystic odontogenic tumor (CCOT) is a novel classification of calcifying odontogenic cyst (COC) that was recommended by the 2005 classification of the World Health Organization (WHO) (1). COC was first described as a likely analogue of the calcifying epithelioma of Malherbe (also termed pilomatricoma or pilomatrixoma) in a study by Gorlin *et al* in 1962 (2); therefore, the eponym of 'Gorlin cyst' is frequently used (3,4). The histopathological features

of this pathological entity are the most notable, including a cyst lining demonstrating characteristic 'ghost' epithelial cells with a propensity to calcify, and the occasional association of this observation with certain odontogenic tumors, including odontoma and ameloblastoma (5). An association is often found between COC and impacted or displaced adjacent teeth. By contrast, dentigerous cysts (DC) are the second most common type of odontogenic cyst, following radicular cysts (6). DCs form at a frequency of 1.44/100 unerupted teeth, representing ~17.1% of all true jaw cysts (7). According to the WHO classification of jaw cysts, DC is defined as an epithelial developmental odontogenic cyst (8). As for CCOT and DC, certain studies have observed recurrent cases with subsequent malignant transformation (9,10). The present study describes the case of a 13-year-old boy who exhibited CCOT and DC within the same cavity, an occurrence that, to the best of our knowledge, has not been previously identified in the literature. Although they may have arisen coincidentally, the presence of two odontogenic lesions in the same cavity in the same patient, one of which is categorized as a neoplasm and the other as a cyst, raises the question regarding their origin and growth process. These issues are investigated in the present study, with a brief review of the literature.

Case report

A 13-year-old asymptomatic Japanese boy was referred to the outpatient clinic of the Osaka Dental University Hospital (Osaka, Japan) on March 23rd, 2015 by a dentist for additional investigation of an area of radiolucency in the lower right molar area. The lesions were first detected on conventional radiographs at a local dental clinic that the patient had visited for dental checkups. Clinical examination revealed slight facial asymmetry and no intra-oral swelling (Fig. 1). The initial conventional radiograph was obtained using panoramic equipment (Super Veraview X500 AE; J Morita Manufacturing Corp., Kyoto, Japan) at 78 kV, 9 mA, and conventional equipment (UD150B-10; Shimadzu Corp., Kyoto, Japan) at 60 kV, 200 mA; this revealed the presence of a well-defined, unilocular, radiolucent lesion with a smooth margin associated with impacted lower right second and third molars. The outline of the whole lesion encompassed an area of scalloping between the two impacted molars, although none of the observations

Correspondence to: Dr Shoko Gamoh, Department of Oral Radiology, Osaka Dental University, 1-5-17 Otemae, Chuo, Osaka 540-0008, Japan
E-mail: gamo-s@cc.osaka-dent.ac.jp

Key words: calcifying cystic odontogenic tumor, dentigerous cyst, simultaneous, septum, pediatric, panoramic radiography, computed tomography

were indicative of the presence of a septum inside the lesion. Large and small radio-opaque bodies formed a perimeter in the lesion around the impacted lower right second molar, which are characteristics specifically observed in CCOT. Radio-opaque bodies were thinly spaced in the distal portion of the lesion. Root resorption or displacement of the lower right first molar was indistinct, although the lesion was located close to the distal side of the first molar. The mandibular canal was shifted downward due to pressure from the lesion (Fig. 2). The quality of the intraoral radiograph was poor as the X-ray sensor induced the patient's gag reflex.

Computed tomography (CT) images were obtained using a CT scanner (BrightSpeed Elite; GE Healthcare, Chicago, IL, USA) at 120 kV. The electrical current was automatically optimized for the object thickness (maximum, 120 mA). In addition, the CT was performed according to the following parameters: Slice thickness, 0.65 mm; pitch and tube voltage, 0.625:1; and field of view, 16.8 cm². CT images revealed a 20-mm sized, elliptical, well-defined, unilocular expanding lesion with thinned buccolingual cortical plates in the right mandible molar area (Fig. 3). Lower right second and third molars were impacted underneath the bulk of the lesion, near the inferior margin of the mandible. Large and small radio-opaque bodies lined the margin of the mesial lesion around the impacted lower right second molar. Radio-opaque bodies were poorly detected in the distal portion around the impacted third molar. The mandibular canal near the lesion was shifted downward. There were no observations that indicated the existence of a septum. These results were consistent with those of the panoramic radiograph, providing additional information concerning buccolingual bony expansion. The CT value of the radiolucency inside the lesion was 30 HU, representing fluid, and that of the radio-opaque bodies was ~1,200 Hounsfield units, suggesting that they were tooth-like masses.

Overall, the imaging diagnosis was of a CCOT. The lesion was judged to be a single mass due to the absence of a septum. It was hypothesized that the CCOT had displaced or prevented the eruption of molars, as the development of CCOT and tooth eruptions occurred concurrently.

Following fenestration and incisional biopsy, histopathological examinations were performed. The specimens were fixed in 10% formalin solution and embedded in paraffin at room temperature for 24 h. Samples were sliced into 2- μ m-thick sections, deparaffinized in 1-limonene (Hemo-D, FALMA Co., Ltd., Tokyo, Japan) and dehydrated through a graded ethanol series (80, 90, 95 and 100%). Antigen retrieval was performed by autoclaving at 121°C for 15 min in retrieval buffer (pH 6.0; Mitsubishi Kagaku Iatron, Tokyo, Japan). Subsequent to autoclaving, slides were allowed to cool down to room temperature. The endogenous peroxidase activity was blocked with 3% hydrogen peroxidase, and non-specific reactions were blocked with 2% normal horse serum (Vector Laboratories, Inc., Burlingame, CA, USA). The section was incubated with anti-human B-cell lymphoma-2 (Bcl-2) oncoprotein mouse monoclonal antibody (1:100, clone 124, cat. no. M0887, lot no. 00056477, Dako; Agilent Technologies, Inc., Santa Clara, CA, USA). This antibody was incubated for 60 min at room temperature. Subsequently, the section was incubated with peroxidase conjugated anti-mouse antibody

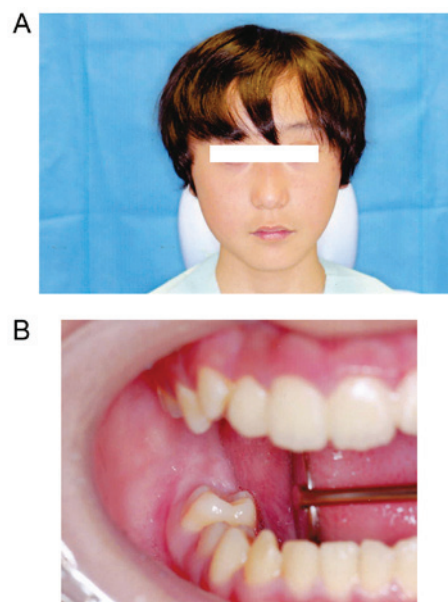


Figure 1. Images at initial clinical examination. (A) Front face view and (B) intra-oral view demonstrating no extra-oral asymmetry or intra-oral swelling, respectively.

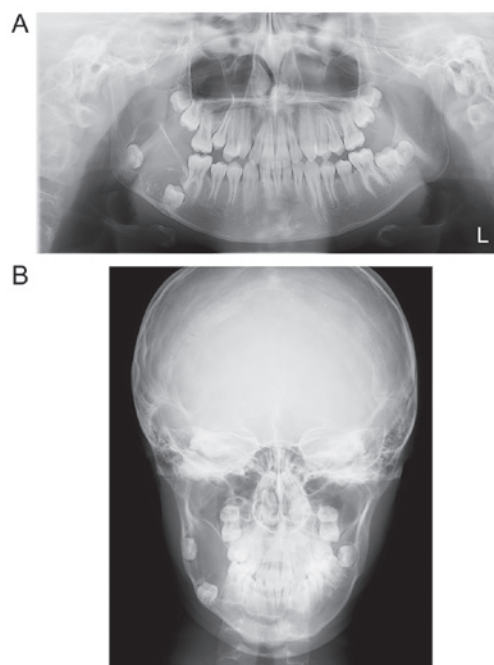


Figure 2. Initial conventional radiographs. (A) Panoramic and (B) postero-anterior radiographs revealing the presence of a well-defined, unilocular, radiolucent lesion with a smooth margin associated with impacted lower right second and third molars. L, left side.

(1:1, cat. no. 10037259, Dako; Agilent Technologies, Inc.) for 30 min at room temperature. The section was visualized by 3,3'-diaminobenzidine-tetrahydrochloride and counterstained with 1% hematoxylin at room temperature for 60 min. As a negative control, a non-immunized antibody [mouse immunoglobulin G (cat. no. X0943, lot no. 012C013; dilution, 1:1,000 Dako; Agilent Technologies, Inc.)] was used instead of primary antibodies. The specimen was independently interpreted by two pathologists without using any software. If decisions

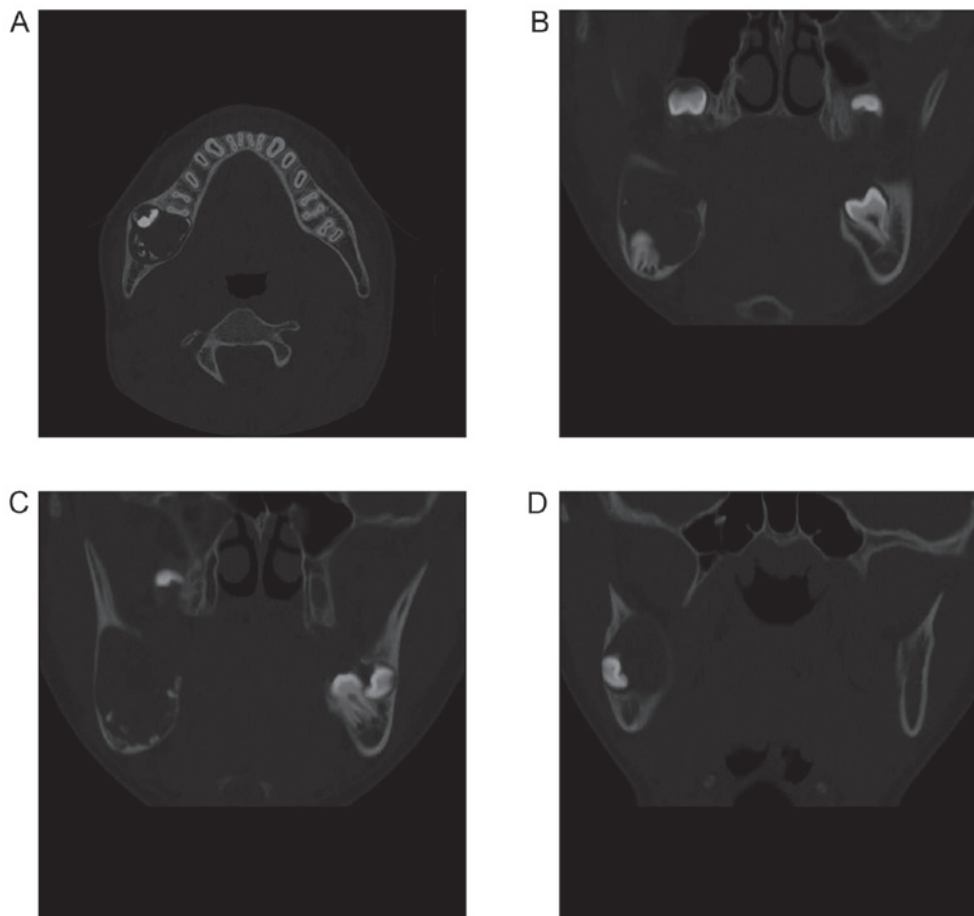


Figure 3. Initial computed tomography images. (A) Axial view and (B) coronal view demonstrating an impacted lower right second molar. (C) Coronal view illustrating the radio-opaque bodies lined up along the margin of the mesial lesion. (D) Coronal view demonstrating the impacted lower right third molar. Images revealed a 20-mm, elliptic, well-defined, unilocular expanding lesion with thinned buccolingual cortical plates in the right mandible molar area.

between the pathologists differed, agreement was reached by consensus decision-making.

The histopathological results demonstrated that the lesion may have been an odontogenic fibroma with odontogenic epithelium. CT was performed 3.5 months after the initial CT and it was observed that the calcification inside the lesion had increased in the interval between the fenestration and the tumor excision (Fig. 4).

With a tentative diagnosis of a benign odontogenic tumor of the mandible, surgical enucleation under general anesthesia was performed. The patient underwent surgical treatment with extensive bone curettage and extraction of the lower right second and third molars 4 months after the fenestration.

Histopathological examination of the whole-mount section of the excisional biopsy specimens, sectioned in a mesiodistal direction (Fig. 5A). In the mesial portion around the lower right second molar, the cystic wall was lined by an ameloblastomatous epithelium with dentin-like structures, 'ghost cells' and numerous calcified particles (Fig. 5B). Only this portion of the specimen was stained by an antibody against Bcl-2 protein, the presence of which distinguishes tumors from other pathologies and is associated with the mechanism of apoptosis (11,12), which confirmed the existence of tumor cells (Fig. 5C). Conversely, in the distal portion around the third molar, the cystic lesion was lined by unkeratinized stratified squamous epithelia that

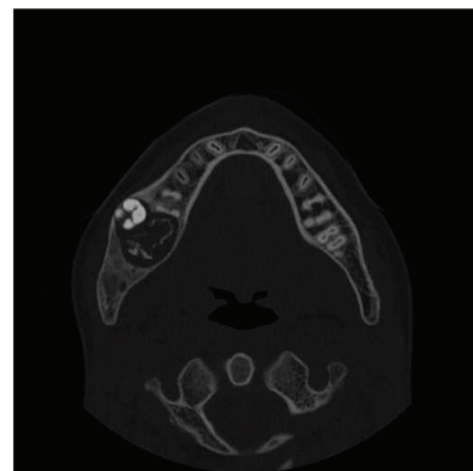


Figure 4. Computed tomography image obtained subsequent to fenestration. Calcification inside the lesion was noted to be increased 3.5 months after the procedure.

included an area of proliferation due to inflammation caused by the fenestration (Fig. 5D). This portion did not demonstrate any expression of Bcl-2 protein (Fig. 5E). These histopathological results supported the diagnoses of a CCOT and DC. A thick layer of collagen fiber was also observed between the two different histopathological entities.

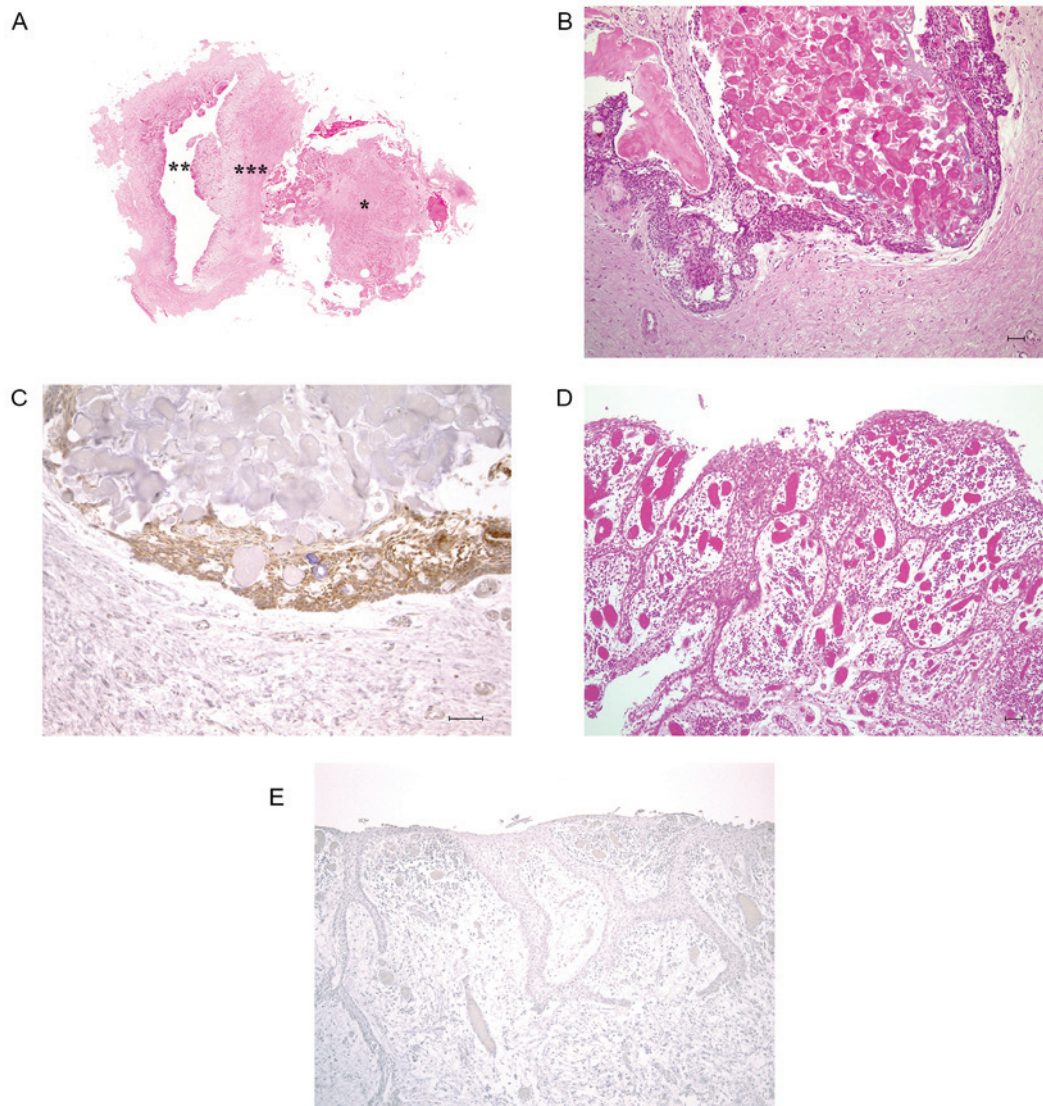


Figure 5. Histopathological data. (A) Image demonstrating the synchronism of the two aspects of the lesion. Hematoxylin and eosin staining; *, the mesial portion indicating calcifying cystic odontogenic tumor; **, the distal portion indicating a dentigerous cyst; ***, a thick layer of collagen fibers. Granulation tissue accompanied by cholesterol gap occupies the ex-cystic space due to inflammation potentially caused by fenestration. However, a remaining cyst cavity may be observed near to the cyst wall surrounding the granulation tissue. (B) Image obtained from the mesial portion of the specimen. The cystic wall was lined by an ameloblastomatous epithelium with 'ghost cells' and numerous calcified particles. The dentin-like hard tissue was visible (scale bar, 50 μ m; original magnification, x100). (C) The same tissue portion as (B) was stained by an antibody against Bcl-2 protein, which confirmed that this portion consisted of tumor cells (scale bar, 50 μ m; original magnification, x100). (D) Image obtained from the distal portion of the specimen. The cystic lesion was lined by unkeratinized stratified squamous epithelia (scale bar, 50 μ m; original magnification, x100). (E) The same portion as (D) was stained by an antibody against Bcl-2 protein (original magnification, x100). Bcl-2, B-cell lymphoma-2.

The results of the surgery were consistent with the radiological data (Fig. 6A) and the mandibular canal existed just underneath the impacted teeth (Fig. 6B). The enucleated material exhibited a solid structure with calcification in the thick wall. No recurrence or postoperative complications were observed during a 2-year follow-up period. Written informed patient consent was obtained for the publication of this study.

Discussion

The current case presents two important clinical points, namely that CCOT and DC may occur simultaneously and adjacently in a single cavity of the same jaw, and that CT is useful in evaluating the result of the fenestration by visualizing the change in the total size of the tumor.

The present study reports a case of the simultaneous occurrence of CCOT and DC in the mandible of a patient. To the best of our knowledge, the synchronous occurrence of CCOT and DC as distinct lesions has not been previously identified. In the present case, the diagnoses reached from the imaging and histopathological studies were inconsistent. The presence of a single mandibular radiolucent lesion led to the suspected diagnosis of a CCOT. However, the definitive diagnosis of the two pathologically distinct entities of CCOT and DC was made by pathologists based on the excisional biopsies. CCOT may occasionally be an aggressive and recurrent tumor (1,13), therefore close post-surgical follow-up is preferable.

In general, odontogenic lesions containing calcifications are particularly difficult to diagnose based only on histopathological data. X-rays are occasionally crucial to reach

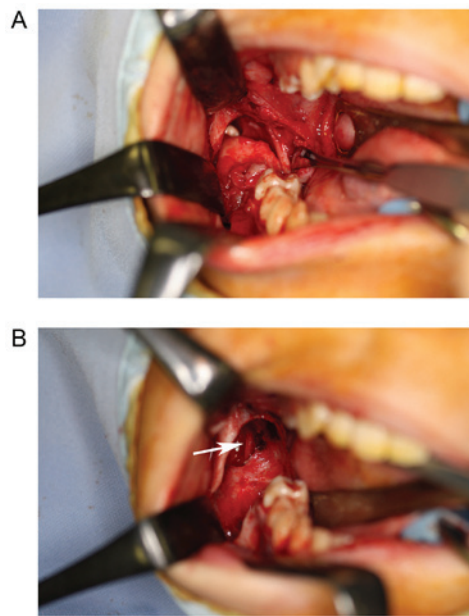


Figure 6. Intraoperative images. (A) Image demonstrating the impaction of the lower third molar following the extraction of the lower second molar with calcifying cystic odontogenic tumor. (B) Image demonstrating the naked mandibular canal (arrow). The cystic lesion was easily separated from the surrounding bone.

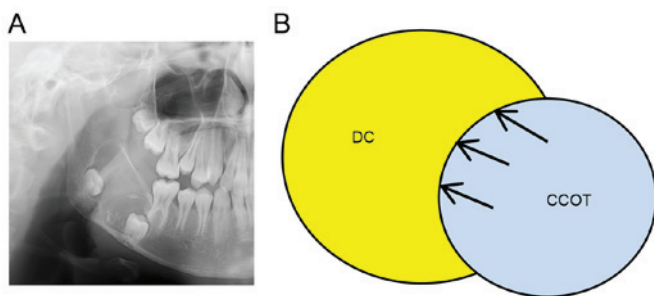


Figure 7. (A) X-ray of the lesion. (B) Schematic view of the two lesions and the possible pressure (arrows) produced as a result of unequal growth. DC, dentigerous cyst; CCOT, calcifying cystic odontogenic tumor.

the definite diagnosis. However, regarding the present case, it was important to consider potential explanations for the difficulty in achieving the diagnosis based on X-ray images alone, which were not able to detect the existence of DC. Considering the X-ray and histopathological data, two different types of soft tissues were estimated to be adjacent to each other in a single hard-tissue cavity. Previous literature has described the simultaneous occurrence of odontogenic lesions as hybrid or distinct lesions (3,14-18). Among these studies, Chindasombatjaroen *et al* (17) described the case of a patient with CCOT associated with an odontoma, a supernumerary tooth, and DC that simultaneously occurred at varying maxillary locations. By contrast, the present study described the occurrence of two independent lesions that existed concomitantly in a single cavity. The characteristic feature of the case in the present study was that the CT images did not demonstrate any indication of the existence of a septum; only a bundle of collagen fibers separated the two lesions.

It was also found that CT is useful not only for diagnosing the disease, but for evaluating the issue of fenestration. From

a radiological viewpoint, the focus was directed towards the internal structure of the lesion. The CT images demonstrated that the calcification inside the lesion had increased in the interval between fenestration and enucleation. The following two assumptions about this observation could be made: The development of the CCOT was accelerated by stimulation caused by the fenestration, and the ossification as part of the healing process occurred inside the lesion. Neither assumption was correct in the present case. It was important to focus on the fact that the whole lesion had decreased in size following the fenestration, which indicated that sound healing was obtained subsequent to surgical intervention. According to the surgeon, additional development or ossification inside the CCOT may occur over the years following initial downsizing, due to surgical decompression or fenestration. This issue highlighted the unforeseen difference of viewpoints between radiologists and surgeons.

CCOT generally appears as a unilocular lesion with a well-defined margin (5,19). The tumor may resemble a calcifying epithelial odontogenic tumor, odontoma, adenomatoid odontogenic tumor, ossifying fibroma or fibrous dysplasia. The lining of COC consists of ameloblastic epithelium and 'ghost cells', which undergo dystrophic calcification (20). In the early developmental stages, COCs will appear completely radiolucent. During maturation, calcifications develop that produce a well-circumscribed, mixed radiolucent-radiopaque appearance (4). In the case of the present study, well-defined unilocular forms and regular margins were observed on conventional radiographs and CT images. Unexpectedly, the CT images did not demonstrate any indications of the slightly scalloped outline and septum-like structure that was observed on the panoramic radiograph. The reason for this may be associated with the projection geometry peculiar to conventional radiographs, termed the 'eggshell effect'. Conventional radiographs that project a three-dimensional volume onto a two-dimensional receptor may produce an eggshell effect of corticated structures. The septum-like structure that was present only on the panoramic radiograph was a key result in the interpretation of the case, as it was present in a single lesion. It suggested that there was a difference in the potential doubling time between the two lesions. Considering the nature of tumors and cysts, the growth of the CCOT was potentially quicker compared with that of the DC, which could result in pressure from the CCOT on the side of the DC. Fig. 7 demonstrates the schematic view of the two lesions being exposed to an X-ray beam.

CCOT rarely presents in association with other odontogenic tumors, including ameloblastic fibro-odontoma, ameloblastic fibroma, odontoameloblastoma and odontogenic myxofibroma (16,21,22). DC, ameloblastic fibro-odontoma, adenomatoid odontogenic tumors and calcifying epithelial odontogenic tumors are all included in the differential diagnosis of a CCOT. A definitive diagnosis may be reached histologically (16,23). In the X-ray investigation of the present case, ameloblastic fibro-odontoma was ruled out, as radiopacity was not observed in the central region of the tumor, the density of which resembled that of dental hard tissue, as observed in odontomas (24). A calcifying epithelial odontogenic tumor was also ruled out, as the radiolucent margin was clearly demarcated from the normal bone at the periphery.

By definition, a DC encloses the crown of an unerupted tooth as a result follicular expansion, and it is attached to the cement-enamel tooth junction. The peak incidence for DCs is within the second and third decades of life, with the mandibular third molars being the most frequently involved teeth (24). The histological appearance of the lesion is of a thin myxoid-appearing fibrous tissue wall, lined by non-keratinizing stratified squamous epithelium, which is actually a derivative of reduced enamel epithelium (25). Radiologically, a well-circumscribed cyst that contains the crown of the tooth is observed. As the cyst grows, it pulls the unerupted tooth with it. A small DC is unilocular. Large cysts may be multilocular, and the confined tooth may be displaced from its normal location (20,26).

In the present case, achieving a diagnosis based on radiology was challenging for the following reasons: The suspected entities of CCOT and DC are occasionally associated with impacted or unerupted teeth (20) and no septum-like structure was observed on the CT images. In this regard, it is possible that resorption of the septum occurred due to the skeletal growth of the patient. However, the amount of calcification was markedly different between the portions around the second and third molars. The existence of considerable differences between the two portions was confirmed by CT.

In conclusion, the present case demonstrated that CCOT and DC may be present simultaneously in a single cavity. Additionally, CT was important in evaluating the healing process in detail. The present case may serve as a valuable warning that CCOT, which may recur and transform into malignancy if improperly treated, may be present in such lesions.

Acknowledgements

The authors would like to thank Dr Kaname Tsuji (First Department of Oral and Maxillofacial Surgery, Osaka Dental University, Osaka, Japan) for providing support to the study, and ThinkSCIENCE Inc. (Tokyo, Japan) for providing language editing services.

References

- Utumi ER, Pedron IG, da Silva LP, Machado GG and Rocha AC: Different manifestations of calcifying cystic odontogenic tumor. *Einstein (Sao Paulo)* 10: 366-370, 2012 (In English, Portuguese).
- Gorlin RJ, Pindborg JJ, Odont, Clausen FP and Vickers RA: The calcifying odontogenic cyst-a possible analogue of the cutaneous calcifying epithelioma of Malherbe. *An analysis of fifteen cases. Oral Surg Oral Med Oral Pathol* 15: 1235-1243, 1962.
- Basile JR, Klene C and Lin YL: Calcifying odontogenic cyst with odontogenic keratocyst: A case report and review of the literature. *Oral Surg Oral Med Oral Pathol Oral Radiol Endod* 109: e40-e45, 2010.
- Menat S, Md S, Attur K and Goyal K: Ameloblastomatous CCOT: A case report of a rare variant of CCOT with a review of the literature on its diverse histopathologic presentation. *Case Rep Dent* 2013: 407656, 2013.
- Iida S, Fukuda Y, Ueda T, Aikawa T, Arizpe JE and Okura M: Calcifying odontogenic cyst: Radiologic findings in 11 cases. *Oral Surg Oral Med Oral Pathol Oral Radiol Endod* 101: 356-362, 2006.
- Son HJ, Jeong YJ, Jeong JS and Kang DY: An inflammatory dentigerous cyst shows rim uptake on bone scan: A case report. *Nucl Med Mol Imaging* 48: 79-81, 2014.
- Narang RS, Manchanda AS, Arora P and Randhawa K: Dentigerous cyst of inflammatory origin-a diagnostic dilemma. *Ann Diagn Pathol* 16: 119-123, 2012.
- Sumbh B, Sumbh SG, Jain P and Pagare J: Classification of odontogenic cysts: A review. *IOSR J Dental Med Sci* 16: 79-82, 2017.
- Mokhtari S, Mohsenifar Z and Ghorbanpour M: Predictive factors of potential malignant transformation in recurrent calcifying cystic odontogenic tumor: Review of the literature. *Case Rep Pathol* 2013: 853095, 2013.
- Zapała-Pośpiech A, Wyszyńska-Pawełec G, Adamek D, Tomaszewska R, Zaleska M and Zapała J: Malignant transformation in the course of a dentigerous cyst: A problem for a clinician and a pathologist. Considerations based on a case report. *Pol J Pathol* 64: 64-68, 2013.
- Cheung TH, Chung TK, Lo KW, Yu MY, Krajewski S, Reed JC and Wong YF: Apoptosis-related proteins in cervical intraepithelial neoplasia and squamous cell carcinoma of the cervix. *Gynecol Oncol* 86: 14-18, 2002.
- Murakami M, Sakai H, Kodama A, Mori T, Maruo K, Yanai T and Masegi T: Expression of the anti-apoptotic factors Bcl-2 and survivin in canine vascular tumours. *J Comp Pathol* 139: 1-7, 2008.
- Daniels JS: Recurrent calcifying odontogenic cyst involving the maxillary sinus. *Oral Surg Oral Med Oral Pathol Oral Radiol Endod* 98: 660-664, 2004.
- Hisatomi M, Asami J, Konouchi H, Yanagi Y and Kishi K: A case of glandular odontogenic cyst associated with ameloblastoma: Correlation of diagnostic imaging with histopathological features. *Dentomaxillofac Radiol* 29: 249-253, 2000.
- Shimamoto H, Kishino M, Okura M, Chindasombatjaroen J, Kakimoto N, Murakami S and Furukawa S: Radiographic features of a patient with both cemento-ossifying fibroma and keratocystic odontogenic tumor in the mandible: A case report and review of literature. *Oral Surg Oral Med Oral Pathol Oral Radiol Endod* 112: 798-802, 2011.
- Chindasombatjaroen J, Kakimoto N, Akiyama H, Kubo K, Murakami S, Furukawa S and Kishino M: Computerized tomography observation of a calcifying cystic odontogenic tumor with an odontoma: Case report. *Oral Surg Oral Med Oral Pathol Oral Radiol Endod* 104: e52-e57, 2007.
- Chindasombatjaroen J, Poomsawat S and Klongnoi B: Calcifying cystic odontogenic tumor associated with other lesions: Case report with cone-beam computed tomography findings. *Oral Surg Oral Med Oral Pathol Oral Radiol* 113: 414-420, 2012.
- Fregnani ER, da Cruz Perez DE, Soares FA and Alves FA: Synchronous ameloblastoma and orthokeratinized odontogenic cyst of the mandible. *J Oral Pathol Med* 35: 573-575, 2006.
- Uchiyama Y, Akiyama H, Murakami S, Koseki T, Kishino M, Fukuda Y, Shimizutani K and Furukawa S: Calcifying cystic odontogenic tumour: CT imaging. *Br J Radiol* 85: 548-554, 2012.
- Som PM and Brandwein MS: Tumors and tumor-like conditions. In: *Head and Neck Imaging*. Som PM and Curtin HD (eds). 4th edition. Mosby, St. Louis, pp345-346, p352, p9385, 2003.
- Yoon JH, Kim HJ, Yook JI, Cha IH, Ellis GL and Kim J: Hybrid odontogenic tumor of calcifying odontogenic cyst and ameloblastic fibroma. *Oral Surg Oral Med Oral Pathol Oral Radiol Endod* 98: 80-84, 2004.
- Lin CC, Chen CH, Lin LM, Chen YK, Wright JM, Kessler HP, Cheng YS and Ellis E III: Calcifying odontogenic cyst with ameloblastic fibroma: Report of three cases. *Oral Surg Oral Med Oral Pathol Oral Radiol Endod* 98: 451-460, 2004.
- McGowan RH and Browne RM: The calcifying odontogenic cyst: A problem of preoperative diagnosis. *Br J Oral Surg* 20: 203-212, 1982.
- Koenig LJ: Mandible and maxilla. In: *Diagnostic Imaging Oral and Maxillofacial*. Koenig LJ, Tamimi D, Petrikowski CG, Harnsberger HR, Ruprecht A, Benson BW, Van Dis ML, Hatcher D and Perschbacher SE (eds). Amirsys, Milwaukee, WI, pp50-53, pp100-1032, 2012.
- Shephard M and Coleman H: Simultaneous adenomatoid odontogenic and keratocystic odontogenic tumours in a patient with Gorlin-Goltz syndrome. *Aust Dent J* 59: 121-124, 2014.
- Verbin RS and Barnes L: Cysts and cystlike lesions of the oral cavity, jaws and neck. In: *Surgical Pathology of the Head and Neck*. 1st edition. Barnes L (ed). Marcel Dekker, Inc., New York, NY, pp1233-1307, 1985.