

Diagnosis and treatment of a carotid body tumor: A case report of a rare bilateral tumor

QIANG SUN^{1,2*}, CHENLU XIE^{1*}, ZHIXING NIU¹, LEI SU^{3*}, XI WANG¹, ZHENG FANG¹,
JUNFANG ZHAO¹, SHUAI CHEN¹, XINMING LI¹ and MINGLEI SUN¹

¹Department of Stomatology; ²Institute of Clinical Medicine; ³Department of Radiology,
The First Affiliated Hospital of Zhengzhou University, Zhengzhou, Henan 450052, P.R. China

Received November 21, 2015; Accepted April 27, 2017

DOI: 10.3892/ol.2017.7101

Abstract. In the present case report, a rare bilateral carotid body tumor (CBT) and the imaging and pathological features of a CBT are described. In the present report, a rare case of bilateral carotid body tumor, which developed in the bifurcation of the common carotid artery, and the clinical manifestations, imaging and pathological features of this CBT are summarized. The imaging cannot validate the diagnosis; however, imaging identified that the tumor exhibited an intact envelope. Immunohistochemical staining revealed that the tumor cells were strongly positive for cluster of differentiation 56, Syn and protein S-100, moderately positive for transcription factor E3, negative for cytokeratin and epithelial membrane antigen, and partial cells were weakly positive for Desmir (<5%). In view of the clinical and pathological features of the carotid body tumor, surgery is hypothesized to be the optimal treatment and may enable the tumor to be resected completely. Refined surgical techniques provide the security of safe resection and decrease the risk of complications occurring.

Introduction

Paragangliomas occur along the human body's sympathetic and parasympathetic chains, and this type of neoplasm may develop in various anatomical locations, with the head and neck region being the primary site. Carotid body tumors (CBTs) derive from the neural crest and are a relatively rare type of neck tumor (1). A CBT located in the upper cervical

region is typically considered to be benign and develops slowly (2); however, CBTs are challenging for surgeons due to the spatial locations and abundant blood supply of this type of neoplasm (3). The occurrence of CBT exhibits sporadic or familial traits. Between 5 and 10% of bilateral CBT cases have been reported to be of the sporadic type (4), and ≤30% of bilateral CBT cases are of the familial form (5); however, the specific etiology of CBT remains unknown. Previous studies have described a mutation in six specific genes (including RET proto-oncogene, von Hippel-Lindau tumor suppressor, neurofibromin 1 and mitochondrial complex II: Succinate dehydrogenase subunits) (6,7) which is associated with CBT.

Between January 2009 and May 2015, 37 patients presenting to The First Affiliated Hospital of Zhengzhou University (Zhengzhou, China) were diagnosed with CBT (Table I). The present case report describes a typical patient with bilateral CBT which was surgically removed with minimal blood loss and temporary neurological loss. In addition, the clinical manifestations and the imaging and pathological features of CBT were summarized. The present case report revealed that preoperative preparation and proper surgical technique are required to improve treatment outcome.

Case report

Materials and methods. Formalin-fixed paraffin-embedded tissues were cut into sections of 4 μm thickness. The avidin-biotin complex (ABC) technique was used, according to the Vectastain Elite ABC kit (Vector Laboratories, Inc., Burlingame, CA, USA). Tissue sections were deparaffinized in xylene, rehydrated in graded ethanol, treated with Tris-EDTA buffer for antigen retrieval and quenched in H₂O₂. Tissue sections were blocked with 2.5% normal serum at room temperature for 1 h and incubated overnight at 4°C with the following primary antibodies: Cluster of differentiation (CD)56 (dilution, 1:400; cat. no. 3576; Cell Signaling Technology, Inc., Danvers, MA, USA) Syn (dilution, 1:400; cat. no. ab32127; Abcam, Cambridge, MA, USA), transcription factor E3 (TFE3; dilution, 1:250; cat. no. ab179804; Abcam), S-100 (dilution, 1:500; cat. no. ab97051; Abcam), cytokeratin (CK; dilution, 1:500; cat. no. ab97051; Abcam), epithelial membrane antigen (EMA; dilution, 1:150; cat. no. ab156947; Abcam) and Demin (dilution, 1:500; cat. no. ab97051; Abcam).

Correspondence to: Dr Minglei Sun or Dr Xinming Li, Department of Stomatology, The First Affiliated Hospital of Zhengzhou University, 1 East Jian She Road, Zhengzhou, Henan 450052, P.R. China
E-mail: sunmlsuccess@sina.com
E-mail: 85244275@qq.com

*Contributed equally

Key words: carotid body tumor, paraganglioma, chemoreceptor tumors, common carotid artery bifurcation

Table I. Clinical parameters of carotid body tumors (n=37).

Characteristic	Patients, n (%)
Age, years	
≥60	3 (8.2)
<60	34 (91.8)
Sex	
Male	17 (45.9)
Female	20 (54.1)
Treatment method	
Observation	13 (35.1)
Surgery	21 (56.8)
External carotid artery ligation	7 (33.3)
Internal carotid artery ligation	3 (14.3)
Common artery ligation	3 (14.3)
CBT completely resection	8 (28.1)
Missing	3 (8.1)
Site	
Left side of neck	15 (40.6)
Right side of neck	16 (43.2)
Bilateral of neck	3 (8.1)
Missing	3 (8.1)
Smoking history	
Non-smoker	29 (78.4)
Smoker	3 (8.1)
Missing	5 (13.5)
Alcohol consumption	
Non-drinker	30 (81.1)
Drinker	2 (5.4)
Missing	5 (13.5)

Missing refers to the number of cases of unknown patient data. CBT, carotid body tumor.

Subsequently, sections were incubated at room temperature for 1 h with biotinylated secondary antibody (dilution, 1:400; cat. no. 8125; Cell Signaling Technology, Inc.) and with ABC reagent. Diaminobenzidine was used as chromogen and counterstained with Mayer's hematoxylin (Sigma-Aldrich; Merck KGaA, Darmstadt, Germany), the results were observed using a light microscope (magnification, x200). The present study was approved by the Institutional Ethics Committee Office of The First Affiliated Hospital of Zhengzhou University. Written informed consent was obtained from the patient for the publication of the present case report and accompanying images.

Patient case. A 22-year-old female presented with a 4-year history of a left side neck tumor and occasional pain when cold. The skin of the upper neck was free of the tumor. Type-B ultrasonic revealed a 40x25 mm solid nodule in the upper neck area with a clear boundary, irregular shape and an uneven internal echo, and the Type-B ultrasonic imaging identified the abundant blood flow signals. Enhanced computed tomography (CT) revealed two irregular solid nodules on the left

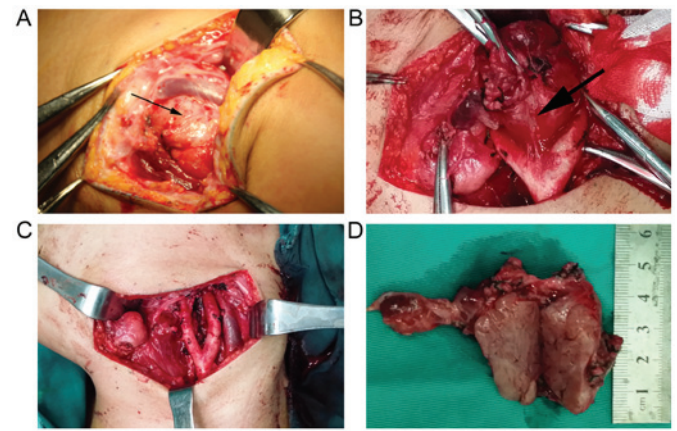


Figure 1. Surgery images. (A) The arrow identifies the carotid body tumor and the carotid artery bifurcation was widened. (B) The tumor mass was stripped out at the carotid bifurcation. (C) Preserved carotid arteries following resection of the carotid body tumor. (D) The size of the tumor was 5x2.5x1.5 cm and the section is gray-red and soft.

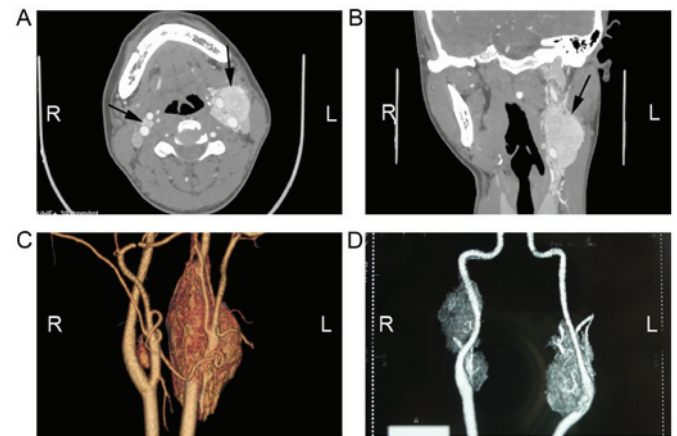


Figure 2. CT images. (A) Enhanced CT scan, plain image. (B) Enhanced CT scan, coronal scan image. (C) Three-dimensional imaging demonstrating bilateral CBT. (D) An additional bilateral CBT; however, the patient abandoned treatment. CT, computed tomography; CBT, carotid body tumor.

and right carotid artery bifurcation. The patient described that the foreign body sensation had recently become serious and therefore surgery was decided upon following the patient's first visit to oral and maxillofacial surgery. The border of the tumor was relatively evident and the tumor had an intact envelope that bled easily, so no biopsy was performed. On the basis of these clinical characteristics and radiographic results, the tumor was identified as a benign CBT, although the possibility of metastatic cancer was not excluded. The tumor occupied the overall carotid artery bifurcation which oppressed the internal carotid artery, therefore it was decided that the tumor was resectable by transverse incision. There was no obvious connection between the tumor and surrounding tissue, and the tumor was resected completely. The common carotid artery, internal carotid artery and external carotid artery remained intact (Fig. 1).

Imaging characteristics. Enhanced CT revealed two irregular solid nodules, consisting of 5.7x2.4x2 and 1x0.8x0.7 cm soft tissue density located in the left and right carotid artery

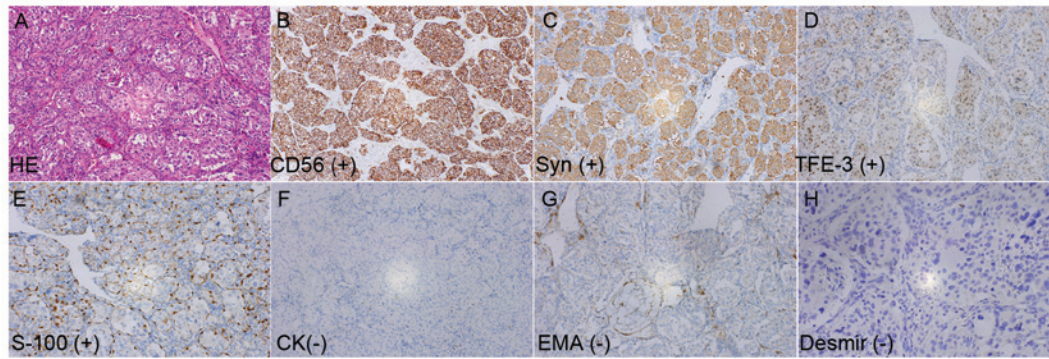


Figure 3. H&E staining and immunohistochemical images of the tumor. (A) H&E staining of the operative specimen center section (magnification, x400). (B) Tumor cells positive for CD56. (C) Tumor cells positive for Syn. (D) Tumor cells positive for TFE3. (E) Tumor cells negative for protein S-100. (F) Tumor cells negative for CK. (G) Tumor cells negative for EMA. (H) Tumor cells negative for Desmir (magnification, x400). CD56, cluster of differentiation 56; TFE-3, transcription factor E3; CK, cytokeratin; EMA, epithelial membrane antigen; H&E, hematoxylin and eosin.

bifurcation, respectively. Additionally, CT demonstrated heterogeneous reinforcement. The left mass surrounded the internal carotid artery and external carotid artery; however, the boundary between the CBT and carotid artery was clear. The CBT was demonstrated to be rich in blood vessels (Fig. 2). These were identified to be possible bilateral CBTs.

Surgical specimens and pathological features. The size of surgical specimens were 5.5x2x1.5 cm which was identified as solid and pinkish-gray, following cutting through the mass. The mass was soft and coated by an envelope. The first pathology report indicated that the tumor may be a paraganglioma, which required validation by immunohistochemical tests. The immunohistochemical report indicated that the tumor cells were strongly positive to CD56, Syn and protein S-100, moderately positive to TFE3, negative to CK and EMA, and partial cells were weakly positive to Desmir (<5%). This confirmed diagnosis of paraganglioma of the carotid body (Fig. 3).

Discussion

The carotid body tumor is located at the common carotid artery bifurcation and was reported by Kapoor *et al* (7). The carotid body contains chemoreceptors that are sensitive to hypoxia, hypercapnia and acidosis, and functions to maintain homeostasis and blood pressure in the human body. In the present case report, CBT primarily occurred in individuals <60 years old, and whether a history of smoking and consumption of alcohol are associated with CBT remains unknown. CBT is a type of paraganglioma arising from the carotid body and is located at the carotid bifurcation (8). Chronic hypoxia is considered to be one of the reasons for CBTs; however, in the present case report, the patient lived in low altitude area where there was no hypoxia and the hypoxia cannot explain the pathogenesis of the case. In the present case report, the majority of CBTs were benign and slow-growing tumors; therefore, the CBTs may have been misdiagnosed as lymph nodes. Owing to the rarity and lack of clinical features of CBTs, diagnosis may be difficult and clinicians may be mistakenly diagnosed as branchial cleft cyst (9), vascular malformation (10), lymph node and arterial aneurysm (11), when the mass is small. Ultrasonography and

CT scans may be enable preoperative diagnosis and treatment plan. Ultrasonography may identify whether the mass is solid and exhibits a rich blood flow, whereas CT scans or magnetic resonance imaging are improved methods for the diagnosis of CBTs (12,13). In the present case report, the CT angiograph (CTA) was required for preoperative diagnosis, which may improve the identification of the dimensions and anatomical association with important blood vessels, including the internal carotid, external carotid artery and common carotid artery. Furthermore, the CTA may indicate the 'feeding artery' which may supply important information for surgery. Fine needle aspiration has been used to improve the diagnosis accuracy of CBT (1), but this technique poses risks.

For patients with bilateral CBTs, surgery may not be performed all at once in order to avoid serious complications, including vascular or cranial nerve lesions. There are a number of patients who are not suitable for surgery, for instance clinically unstable patients, including elderly patients or those with a certainty of stroke. Conservative treatment, including chemotherapy and radiotherapy is ineffective for CBT (14-17). Embolization is one effective palliative treatment, but the vascular complications and cranial nerve deficits may occur in ~33% of the patients (3,18).

Surgical treatment is considered to be the optimal treatment choice for CBTs. Of those patients who underwent surgery at The First Affiliated Hospital of Zhengzhou University, only 1 case exhibited recurrence 2 months after surgery. The tumors may be dissected in the sub-adventitial avascular plane of the artery (19). Shamblin CBT groups II and III may require removal with arteriectomy or internal carotid artery ligation (8). Occasionally, anastomosis may be required between the internal and common carotid arteries or vascular reconstruction with grafts may be required (18,20). Occurrences of technical complications in anastomoses between the common and internal carotid arteries following resection of the carotid body have been reported in a previous study (21). These cases evolved with a number of hematomas and, in a limited number of cases, with cerebral ischemia-reperfusion (21). Of those patients who underwent surgery at The First Affiliated Hospital of Zhengzhou University, only 1 case required vascular repair, and in order to improve and assess the tolerance of unilateral carotid blood

supply, the Matas test and the balloon test occlusion of internal carotid artery are required prior to surgery (22). If the vascular compensatory function exhibited is satisfactory in the total cerebral angiogram and BOT, surgery may be performed. During surgery, the tumor is stripped away from the surface of the blood vessel and damage to the artery walls is avoided. If the walls of the internal carotid and common carotid artery are damaged during surgery, ligation of the internal carotid or common carotid artery may be performed, to avoid postoperative complications.

Improved diagnostic methods are useful for the treatment of CBT. The CTA and Digital Subtraction Angiography may identify the border and the supply artery. Ligation of the supply artery may markedly decrease during the surgery. The Matas test and the BOT of internal carotid artery are required to evaluate the surgery indication. Refined surgical technologies or skills may provide security of safety resection and decrease the occurrence of complications.

Acknowledgements

The present case report was supported by the National Natural Science Foundation of China (grant no. 81402231), the Basic and Frontier Technology Research Projects by Science and Technology Department of Henan (grant no. 142300410315) and the Youth Foundation of The First Affiliated Hospital of Zhengzhou University, and the Oral and Maxillofacial Surgery Academician Workstation of Zhengzhou (grant no. 152PYSZG040).

References

- Casarim AL, Tincani AJ, Del Negro A, Aguiar CG, Fanni RV and Martins AS: Carotid body tumor: Retrospective analysis on 22 patients. *Sao Paulo Med J* 132: 133-139, 2014.
- Nora JD, Hallett JW Jr, O'Brien PC, Naessens JM, Cherry KJ Jr and Pairolero PC: Surgical resection of carotid body tumors: Long-term survival, recurrence, and metastasis. *Mayo Clin Proc* 63: 348-352, 1988.
- Wieneke JA and Smith A: Paraganglioma: Carotid body tumor. *Head Neck Pathol* 3: 303-306, 2009.
- Sanghvi VD and Chandawarkar RY: Carotid body tumors. *J Surg Oncol* 54: 190-192, 1993.
- Brown JS: Glomus jugulare tumors revisited: A ten-year statistical follow-up of 231 cases. *Laryngoscope* 95: 284-288, 1985.
- Offergeld C, Brase C, Yaremchuk S, Mader I, Rischke HC, Gläsker S, Schmid KW, Wiech T, Preuss SF, Suárez C, *et al*: Head and neck paragangliomas: Clinical and molecular genetic classification. *Clinics (Sao Paulo)* 67 (Suppl 1): S19-S28, 2012.
- Kapoor R, Saha MM, Das DK, Gupta AK and Tyagi S: Carotid body tumor initially diagnosed by fine needle aspiration cytology. *Acta Cytol* 33: 682-683, 1989.
- Lim JY, Kim J, Kim SH, Lee S, Lim YC, Kim JW and Choi EC: Surgical treatment of carotid body paragangliomas: Outcomes and complications according to the shamblin classification. *Clin Exp Otorhinolaryngol* 3: 91-95, 2010.
- Williams MD, Phillips MJ, Nelson WR and Rainer WG: Carotid body tumor. *Arch Surg* 127: 963-968, 1992.
- Zhao FY, Gao Y, Wu MJ, Luo QF, Liu Y and Xu ZQ: Diagnosis and therapy on hemangiomas and vascular malformation in view of the new classification. *Beijing Da Xue Xue Bao* 41: 21-27, 2009 (In Chinese).
- Muhm M, Polterauer P, Gstöttner W, Temmel A, Losert H, Richling B, Undt G, Niederle B, Staudacher M, Kretschmer G and Ehringer H: Glomus caroticum chemodectoma. Review on current diagnosis and therapy. *Wien Klin Wochenschr* 112: 115-120, 2000 (In German).
- Demattè S, Di Sarra D, Schiavi F, Casadei A and Opocher G: Role of ultrasound and color Doppler imaging in the detection of carotid paragangliomas. *J Ultrasound* 15: 158-163, 2012.
- Arya S, Rao V, Juvekar S and Dcruz AK: Carotid body tumors: Objective criteria to predict the Shamblin group on MR imaging. *AJNR Am J Neuroradiol* 29: 1349-1354, 2008.
- Ruby R, Gullane PJ and Mintz D: Chemodectomas of the head and neck. *J Otolaryngol* 10: 126-136, 1981.
- Liapis C, Gougoulakis A, Karydakis V, Verikokos C, Doussaitou B, Skandalakis P, Gogas J and Sechas M: Changing trends in management of carotid body tumors. *Am Surg* 61: 989-993, 1995.
- Pellitteri PK, Rinaldo A, Myssiorek D, Gary Jackson C, Bradley PJ, Devaney KO, Shaha AR, Netterville JL, Manni JJ and Ferlito A: Paragangliomas of the head and neck. *Oral Oncol* 40: 563-575, 2004.
- Kasper GC, Welling RE, Wladis AR, CaJacob DE, Grisham AD, Tomsick TA, Gluckman JL and Muck PE: A multidisciplinary approach to carotid paragangliomas. *Vasc Endovascular Surg* 40: 467-474, 2006.
- Lack EE, Cubilla AL and Woodruff JM: Paragangliomas of the head and neck region. A pathologic study of tumors from 71 patients. *Hum Pathol* 10: 191-218, 1979.
- Anand VK, Alemar GO and Sanders TS: Management of the internal carotid artery during carotid body tumor surgery. *Laryngoscope* 105: 231-235, 1995.
- Gardner P, Dalsing M, Weisberger E, Sawchuk A and Miyamoto R: Carotid body tumors, inheritance, and a high incidence of associated cervical paragangliomas. *Am J Surg* 172: 196-199, 1996.
- Mitchell RO, Richardson JD and Lambert GE: Characteristics, surgical management, and outcome in 17 carotid body tumors. *Am Surg* 62: 1034-1037, 1996.
- Qin RF, Shi LF, Liu YP, Lei DL, Hu KJ, Feng XH, Nie X and Mao TQ: Diagnosis and surgical treatment of carotid body tumors: 25 years' experience in China. *Int J Oral Maxillofac Surg* 38: 713-718, 2009.