

Application of the da Vinci surgical robot system in presacral nerve sheath tumor treatment

FEIFEI PU¹, ZHICAI ZHANG¹, ZHAOHUI CHEN², KAILIN CAI³, BAICHUAN WANG¹,
QIANG WU¹, DEYAO SHI¹, JIANXIANG LIU¹ and ZENGWU SHAO¹

Departments of ¹Orthopedics, ²Urology and ³Gastrointestinal Surgery, Union Hospital, Tongji Medical College, Huazhong University of Science and Technology, Wuhan, Hubei 430022, P.R. China

Received March 25, 2020; Accepted July 8, 2020

DOI: 10.3892/ol.2020.11984

Abstract. The aim of the present study was to investigate the feasibility of da Vinci robotic surgery in the treatment of presacral tumors, and to observe its efficacy and safety. Between March 2016 and April 2019, 12 patients with presacral nerve sheath tumors underwent da Vinci robotic surgery, and the integrity of the tumor resection, surgical duration, pre- and postoperative visual analog scale (VAS) score, intra- and postoperative blood losses, postoperative bedtime, hospital stay and complications were observed. The tumor was completely removed in all 12 patients, the surgical duration ranged between 76 and 245 min (mean, 106.08 min) and the intraoperative blood loss was 76-145 ml (mean, 101.67 ml). The average preoperative VAS score of the patients was 3.25, and the average VAS score at 1 week, 1 month and 3 months post operation were 1.08, 0.42 and 0.08, respectively. All patients were out of bed on the second day after surgery, and the postoperative drainage was 10-50 ml (mean, 33.50 ml). The patients were hospitalized for 3-5 days (mean, 3.92 days). No complications occurred peri- or postoperatively, and wound pain was the main source of postoperative discomfort. In conclusion, the da Vinci robot can be applied to presacral nerve sheath tumors with high surgical safety, low-level bleeding, a rapid recovery and a short hospital stay, making it worthy of further study.

Introduction

Primary presacral tumors are relatively rare tumors occurring in the space between the sacrum and the

rectum; in 1985, the records at the Mayo Clinic in the USA indicate that presacral lesions occurred in 1 out of 40,000 registrations (1,2). The surgical boundaries of the presacral tumor include the fascia propria of the rectum anteriorly and the presacral fascia posteriorly, while the endopelvic fascia, the bilateral ureter and iliac vessels may also adhere to the tumor (3). The majority of sacrococcygeal tumors have a long onset time and relatively insidious clinical symptoms; pain occurs when the tumor grows and the nerves are compressed by the tumor (1,2). The main types of primary presacral tumor in adults are chordoma, schwannoma, paraganglioma, liposarcoma and chondrosarcoma (4,5).

Due to the complex anatomical location of presacral tumors, the inconsistent pathological type of the tumors and the difficulty of surgery, it is extremely difficult for orthopedic surgeons to diagnose and treat presacral tumors (2,3). Surgical treatment is the treatment of choice; in the past, open surgery was mostly adopted, but in recent years, laparoscopic technology has developed rapidly (2). In previous studies, laparoscopic resection has been considered a safe, feasible and effective treatment for retroperitoneal and presacral tumors (6,7).

The da Vinci robotic surgical system was developed to overcome the limited movement of abdominal endoscopic instruments in a limited space, the amplification of hand tremors, the lack of two-dimensional imaging and the movement of instruments. Surgeons hope to overcome the limitations of endoscopic abdominal surgery using this innovative product. The da Vinci surgical system is widely used in rectal, urological and ovarian cancer types, as it has several advantages (8-10). For example, it provides 3D vision and visual magnification to improve the accuracy of tumor resection. In addition, the da Vinci surgical system consists of 3 or 4 robotic arms that mimic the movements of a human wrist, providing a high degree of freedom. However, there are few reports on da Vinci robot-assisted surgical resection of presacral tumors (11).

The present study summarizes the experience of 12 patients undergoing surgical resection assisted by the da Vinci surgical system for the treatment of presacral tumors, in the hope of providing a new alternative for the surgical treatment of these tumors.

Correspondence to: Professor Jianxiang Liu or Professor Zengwu Shao, Department of Orthopedics, Union Hospital, Tongji Medical College, Huazhong University of Science and Technology, 1277 Jiefang Avenue, Wuhan, Hubei 430022, P.R. China
E-mail: liujianxiangljx@163.com
E-mail: 1985xh0536@hust.edu.cn

Key words: da Vinci, surgery, robot, presacral tumor, nerve sheath tumor

Materials and methods

Ethical approval and consent to participate. The present study was conducted with the approval of the Ethics Committee of Union Hospital, Tongji Medical College, Huazhong University of Science and Technology (Wuhan, China), and in line with the Declaration of Helsinki. The surgical procedure and the collection of tissue specimens were approved by the aforementioned ethics committee. All patients and legal guardians were informed of the surgical operation requirements and regulations on the use of clinical samples, and provided written informed consent for the collection of human tissue specimens used in the present study.

Patients. Between March 2016 and April 2019, 12 patients with presacral tumors were treated using the da Vinci robotic surgery system. This group included 5 males and 7 females, aged 26-49 years (median, 43 years). All patients were pathologically diagnosed with a nerve sheath tumor following surgery. A total of 9 patients with a presacral tumor attended the Wuhan Union Hospital (Wuhan, China) due to lower back pain and lower limb numbness, 1 case was identified in routine health screening and the other 2 cases were identified using imaging examination due to other diseases. Preoperative bloodwork, chest x-ray, electrocardiography findings, blood glucose levels, and liver and kidney function were normal in all patients. None of the patients had a previous history of surgery or serious diseases, or contraindications to surgery.

A total of 19 patients with presacral tumors who were admitted to the Orthopedics Department of Wuhan Union Hospital from March 2016 to April 2019 were also included. This group included 7 males and 12 females, aged between 25 and 62 years (median age, 46 years). These patients received open surgical treatment and were used as the control group for comparison with the da Vinci surgery group. The tumor volume of the included patients was $<5 \times 5 \times 5$ cm (length \times height \times width), and patients with oversized tumors were excluded. Postoperative pathological analysis of the tumors of these patients revealed they were all schwannomas.

Surgical procedure. Preoperatively, the robotic arm, auxiliary channel and camera were placed and marked according to the tumor location and preoperative imaging data (Fig. 1). The patient received general anesthesia and was placed in a Trendelenburg position (12). Following routine disinfection, the mechanical arm system was pushed to a suitable position beside the bed, a small opening ~ 1 -cm long was made on the umbilicus and a trocar was inserted. To begin with, the endoscopic imaging system was inserted and connected to the video screen, and an artificial pneumoperitoneum was formed. The two robotic arms and auxiliary channels were implanted under video monitoring. The intraoperative trocar placement should meet the '20-10-5' principle, whereby the distance between the lens point and the surgical target center is 10-20 cm, the instrument arm trocar is 8-10 cm away from the optimal position of the lens arm trocar, the line between the two points are at an angle of 15-30 to the horizontal position, the distance between instrument arm trocar and auxiliary hole trocar is >5 cm, and the lens arm, center column of the patient cart and patient surgical target are in a straight line (Fig. 2).

After the channel was established, only one instrument nurse and assistant were left next to the operating table, and the surgeon operated the surgical robot system on the table. Following observation of the overall structure of the pelvic cavity, the retroperitoneum was cut open to identify the ureter and iliac vessels. The mechanical arm was operated on the workbench to separate the ureter and iliac vessels, and the assistant on the platform assisted with pulling and retracting to expose the tumor (Fig. 3). If bleeding occurred during the operation, this was stopped by electrocoagulation using the mechanical arm. The blood vessels clearly visible under the microscope were dissociated first and cut off once a blood vessel clip had been used to clamp the blood vessels via the auxiliary channel. Following complete tumor resection, the stump was closed and removed by auxiliary channels, which can be expanded when a tumor is large. The wound was rinsed, the bleeding carefully stopped, and the camera and mechanical arm removed. Drainage was applied and the incision was sutured. All tissue specimens were fixed in 10% buffered-formalin for 24 h at 25°C, embedded in paraffin and cut into 4- μ m-thick sections. Hematoxylin and eosin (H&E) staining was performed for 20 min at 37°C and then observed using an Olympus BX51 light microscope (magnification, $\times 100$; Olympus Corporation). Immunohistochemical staining was performed to aid the diagnosis of some patients to detect S100 (monoclonal mouse anti-human antibody; 1:500; cat. no. 5529; Cell Signaling Technology, Inc.) and vimentin (monoclonal rabbit antibody; 1:500; cat. no. 5741; Cell Signaling Technology, Inc.). Antigen retrieval was performed using 0.01 mol/l citrate buffer at 98°C for 10 min, endogenous peroxidase activity was blocked using 0.3% hydrogen peroxide in methanol for 15 min at room temperature and non-specific binding was blocked using 10% normal goat serum (Wuhan Servicebio Technology Co., Ltd.) at 37°C for 30 min. Subsequently, overnight incubation at 4°C was performed using the aforementioned primary antibodies against S100 and vimentin, followed by a 30-min incubation at 37°C with a horseradish peroxidase-labeled anti-rabbit IgG antibody (1:500; cat. no. NL004; R&D Systems, Inc.) and a horseradish peroxidase-labeled goat anti-mouse IgG antibody (1:500; cat. no. GB23301; Wuhan Servicebio Technology Co., Ltd.). Postoperative pathology was confirmed by two independent pathologists.

Outcome assessment. The perioperative outcomes, surgical duration, visual analog scale (VAS) score pre-operatively and at 1 week, 1 and 3 months postoperatively, blood loss, time to liquid intake, hospitalization time and complications of the 12 patients were calculated. Data on postoperative outcomes, a functional assessment (motor and sensory function), tumor recurrence and metastasis (radiography and MRI) were examined every 3 months for the first 2 years and every 6 months in the third year.

Results

The characteristics of the 12 included patients are presented in Table I. All 12 patients underwent successful surgery and had stable intraoperative vital signs. Postoperatively, the patients were extubated and returned to the ward. All tumors were completely excised, and the postoperative pathological results

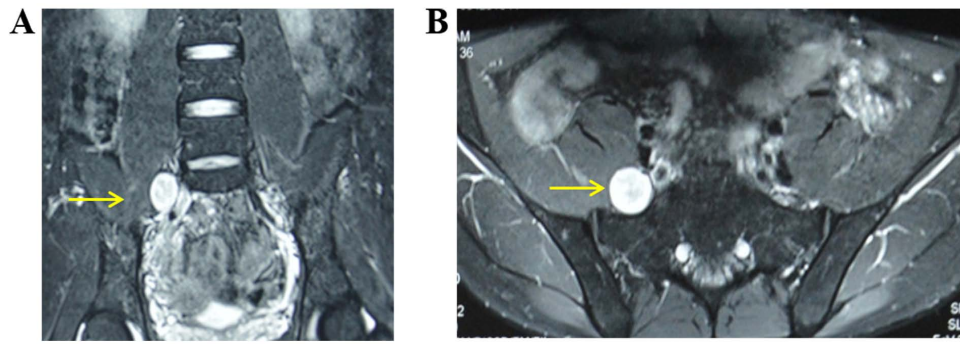


Figure 1. Preoperative pelvic magnetic resonance imaging plain scan and enhancement. The right L5 nerve root was 2.1x2.4x2.0 cm in (A) the coronal plane and (B) the transverse plane, with a clear boundary located at the medial edge of the psoas major, suggesting the high possibility of a nerve sheath tumor. Arrows indicate the area of the tumor.

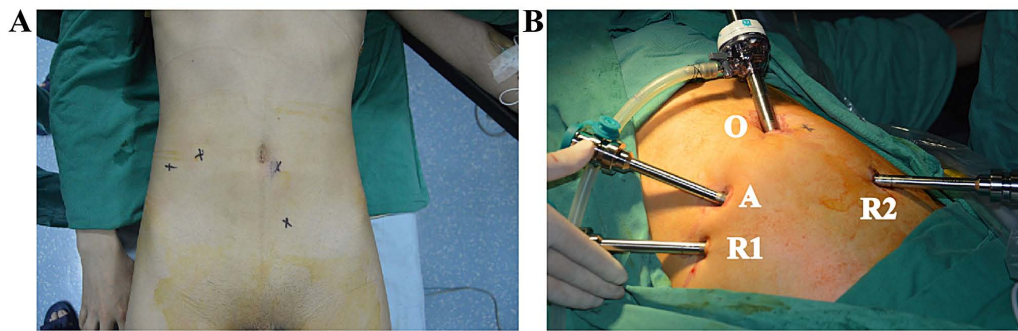


Figure 2. Surgical position and trocar placement. (A) The patient was placed in a modified Lloyd Davis position. (B) Instrumentation of each robotic arm with port positions. O, optic port; R1, robotic right arm; R2, robotic left arm; A, assistant port.

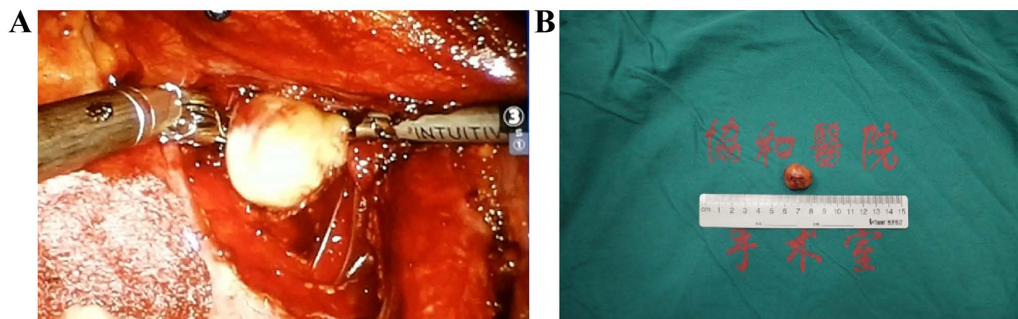


Figure 3. Operative images of the presacral nerve sheath tumor obtained before and after resection. (A) Image of a tumor that was exposed during surgery. (B) Image of the mass removed by resection.

all revealed schwannomas. H&E staining was observed under the microscope, revealing that the spindle cells were arranged in fascicles with red cytoplasm and uniform nucleus size, and there were small thick-walled blood vessels in the stroma (Fig. 4A). A typical palisading pattern was also displayed (Fig. 4B). The tumor was completely removed in all 12 patients, the surgical duration ranged between 76 and 245 min (mean, 106.08 min), and the intraoperative blood loss was 76-145 ml (mean, 101.67 ml). The average preoperative VAS score of the patients was 3.25, and the average VAS score at 1 week, 1 and 3 months postoperatively was 1.08, 0.42 and 0.08, respectively. All patients were out of bed on the second day after surgery, and the postoperative drainage was 10-50 ml (mean, 33.50 ml). The drainage tube was removed on the first

day after the operation and the patient returned to bed activities. Normal daily activities were resumed on the second day after the operation. Postoperative bowel movements and food intake were restored in the patients at 24-72 h postoperatively. The postoperative hospital stay was 3-5 days (mean, 3.92 days). No patients died perioperatively. No cases of intestinal or ureteral injuries, adhesion obstruction, intestinal obstruction, incision infection or pulmonary infection occurred during the hospitalization. Of the patients, 2 reported wound pain that was relieved 2 days later following oral anti-inflammatory and analgesic drug administration. Follow-up continued for 16-41 months. During the follow-up period, a B-ultrasound or CT examination was performed; no cases of tumor recurrence or intestinal obstruction occurred.

Table I. Clinical characteristics of patients.

Case no.	Sex	Age, years	Tumor size, cm ^a	Surgical duration, min	Preoperative VAS	Postoperative VAS			Intraoperative blood loss, ml	Postoperative drainage, ml	Pathological diagnosis	Hospitalization, days	Tumor location
						1 week	1 month	3 month					
1	Male	26	3.2x2.1x1.7	116	4	2	1	0	76	17	Schwannoma	3	S1
2	Female	49	3.8x2.5x2.6	102	3	2	1	0	92	28	Schwannoma	4	S1-2
3	Female	30	4.2x3.5x2.9	90	4	1	1	0	131	45	Schwannoma	5	S2-4
4	Female	43	2.1x2.4x2.0	76	2	0	0	0	106	10	Schwannoma	4	L5
5	Male	41	4.1x2.3x1.6	89	3	1	1	0	95	40	Schwannoma	4	S1
6	Female	35	4.3x3.6x3.1	94	4	1	0	0	98	36	Schwannoma	3	S1-2
7	Female	47	3.5x3.3x2.8	85	2	0	0	0	87	42	Schwannoma	4	L5
8	Male	32	3.6x2.7x3.2	96	2	1	0	0	102	35	Schwannoma	4	S3
9	Female	36	4.0x3.6x2.8	103	1	0	0	0	94	25	Schwannoma	5	L5-S1
10	Male	29	4.6x3.6x3.4	92	5	2	0	0	108	45	Schwannoma	3	S2-3
11	Male	42	3.7x3.3x4.1	85	3	1	0	0	86	29	Schwannoma	4	S1
12	Male	46	L5, 1.1x0.8x1.2; S3, 4.3x3.2x3.4	245	6	2	1	1	145	50	Schwannoma	4	L5, S3

^aTumor size is presented as length x width x height. S, sacrum; L, lumbar; VAS, visual analog scale.

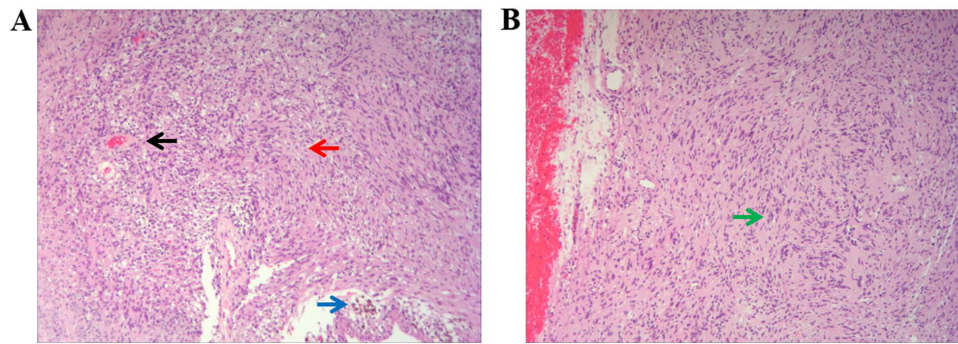


Figure 4. Pathological diagnosis of postoperative specimens. (A) Hematoxylin and eosin staining showing schwannoma with the spindle cells arranged in fascicles with red cytoplasm and uniform nucleus size (red arrow), small thick-walled blood vessels in the stroma (black arrow) and hemorrhagic cystic change (blue arrow) (magnification, x100). (B) Typical palisading pattern with hemosiderin deposition of hematoxylin and eosin staining (green arrow) (magnification, x100).

In the traditional open surgery control group, the results revealed that the surgical incision was 6-8 cm long, the average surgical duration was 160.24 min, the average intraoperative hemorrhage was 152 ml, the postoperative drainage volume was 93 ml and the hospital stay was 9 days; in addition, postoperative femoral nerve injury occurred in 1 patient during the open surgery (data not shown).

Discussion

Presacral tumors, also known as retrorectal tumors, are tumors occurring in the space of the sacrum and rectum. There is loose connective tissue in the anterior sacral space that contains various residual tissues of fetal embryos. The embryonic development process is extremely complex, with diverse tissue structures that are prone to tumorigenesis during the development process (3,4). Although schwannomas grow slowly and most patients have no pain or other clinical symptoms, it has been suggested that surgery may not be necessary for asymptomatic benign schwannomas. Choudry *et al* (13) followed up 8 cases of retroperitoneal schwannomas confirmed by biopsy but not operated upon, and followed them up for 13 to 63 months. After this time, imaging examination showed no change in tumor size. In the case of benign retroperitoneal schwannomas, malignancy rarely occurs; however, they are also capable of local destruction and surgical removal is required (1). Most orthopedic surgeons still believe that the mass effect of the presacral schwannomas should be included in the surgical indications (4). Schwannomas arise from nerve tissue, and it is important to prevent the injury of important nerves during surgery. Surgical resection of schwannomas is different from other benign tumors in that the tumor must be completely removed without damaging the nerve fibers (2). Therefore, the majority of scholars believe that the best treatment for primary retroperitoneal schwannoma is total resection of the tumor without serious or disabling complications, which is also consistent with the basic principles of tumor treatment (3-5). According to the literature, most of the asymptomatic patients or those with mildly painful symptoms are between 20 and 50 years old, and the majority are women (2,4). In the absence of symptoms, the probability of local tumor recurrence or distant metastasis is relatively low, and complete resection of the tumor is an ideal treatment. The

lack of invasive growth exhibited by these tumors and their thick capsular lining make presacral schwannomas amenable to complete resection (14).

At present, the standard treatment strategy for presacral tumors is complete surgical resection, which can reduce the symptoms of the tumor pressing on the surrounding organs, such as constipation and frequent urination, as well as pain in the waist and leg caused by the tumor pressing on the nerve root. According to a previous report, tumors in ~40% of patients are resected using the anterior surgical approach, tumors in 35% of patients are resected using the posterior surgical approach, and the tumors in the remaining patients are resected using an anterior combined with posterior surgical approach (15). The choice of surgical approach also depends on the experience of the orthopedic surgeon and the tumor size, location and morphology. In recent years, with the development of laparoscopic technology, there have been several cases of laparoscopic resection of presacral tumors internationally (14-16). The advantages of laparoscopic surgery are adequate exposure, minor trauma and quick recovery; compared with laparotomy, dissection provides a clearer surgical field, and the intraoperative blood loss is significantly reduced. However, laparoscopic surgery also has its limitations, such as poor flexibility of the instrument limiting the range of motion of the operator, narrow surgical vision, and the need for the operator to concentrate for a long time, which can cause fatigue (17,18).

The da Vinci robotic surgery system has the advantage of being minimally invasive, which makes up for its shortcomings and limitations. Since it was approved by the United States Food and Drug Administration in 2005, it has been widely used abroad, particularly in urological surgery and gynecological surgery (8-10). Robot-assisted surgical systems provide surgeons with greater dexterity and accuracy, and can reduce damage to the internal abdominal organs. The robotic surgery system has the following characteristics (8,9,18): i) The use of a 3D high-definition image that is magnified 10-15 times enables the clear identification of the anatomical structure, improving surgical accuracy; ii) the instrument arm mimics the movements of the surgeon with 7 degrees of freedom, making it more flexible and accurate; iii) the controller filters tremors automatically and is more stable than a manual tool; iv) the surgeon adopts a sitting posture, which is conducive to the completion of a long, complex

surgery; and v) the incidence of perioperative complications is decreased due to minor trauma, rapid recovery and a short hospital stay. Pacchiarotti *et al* (19) reported two cases of schwannomas, one in the posterior superior mediastinal sulcus and the other in the inferior thoracic sulcus, the removal of the schwannomas in these patients by conventional surgery is technically challenging. Robotic thoracoscopic surgery was used to completely remove the tumors, which suggests that simple anterior endoscopic surgery at extreme locations is safe and effective. Garzon-Muvdi *et al* (20) found that the use of a nerve stimulator and da Vinci's bipolar cauterizer were good choices for laparoscopic-assisted surgical resection of a presacral mass. During the surgery, the nerve adjacent to the tumor can be monitored and stimulated, and the surgeon can obtain the best surgical resection while understanding its anatomical structure and preserving the nerve function.

The present study also found certain advantages of robotic surgery in the surgical resection of presacral tumors. Robotic surgery has the spatial advantage of exposing the posterior tumor, and the robotic arm can pull the rectum and sacrum to increase clearance and better reveal the iliac vein, former sacral venous plexus and pelvic plexus, notably reducing intraoperative bleeding and damage to the surrounding tissues. Jun *et al* (21) reported the case of a young female patient with a large presacral schwannoma (originating from the right S2 nerve). The da Vinci surgical robotic system provides better visualization during deep pelvic surgery and provides two-wrist instrumental control, which is sufficient for the operator to successfully detach the tumor from the surrounding sensitive structures. Nerve stimulation during surgery can differentiate important nerves and avoid causing nerve damage. The patient suffered no complications, lost <75 ml of blood during the operation, was hospitalized for 3 days and returned to normal work within 2 weeks after the operation. The study suggested that for certain patients with presacral tumors, surgical resection assisted by da Vinci surgical robot has a greater advantage. In the present study, all tumors were completely excised, and the postoperative pathological results indicated all neurilemmomas. Intraoperative blood loss was 76-145 ml (mean, 101.67 ml) and postoperative drainage was 10-50 ml (mean, 33.50 ml). The drainage tube was removed on the first day after the operation and the patient returned to bed activities. Normal daily activities were resumed on the second day after the operation. The data of patients with retroperitoneal schwannoma previously resected by open surgery in the Orthopedics of Departments of Wuhan Union Hospital were compared and analyzed. In the traditional open surgery group, the length of the incision was longer, the operation time was prolonged, the average intraoperative bleeding and postoperative drainage volume were increased, while the hospital stay was shortened compared with in the da Vinci surgery group. In addition, postoperative femoral nerve injury occurred in 1 patient during the open surgery, while no complications were found in all the patients undergoing da Vinci surgery. The results of the present study are consistent with those reported in the literature (11); en bloc robot-assisted resection of presacral nerve sheath tumors was associated with limited procedure duration, minor blood loss and satisfying intra- and post-operative outcomes. da Vinci surgery can be used as

a safe surgical treatment for retroperitoneal schwannomas. However, traditional open surgery should be performed for patients with large tumors, which may not be malignant, or for patients whose economic conditions do not allow for the use of the robotic surgery system.

The da Vinci robot system consists of a doctor's console, a video system and a bedside arm tower. The console doctor can simultaneously operate the robotic arm to achieve electrocoagulation and perform other motions. The assistant on the operating table can achieve traction, suction and other auxiliary motions through the auxiliary channel. Therefore, a complicated operation can be performed by only one anesthesiologist, one instrument nurse, one doctor on the operating table and one doctor on the console, which can greatly save manpower and material resources. However, there are still some shortcomings of the whole operation system. To begin with, the da Vinci robotic surgery system is a mechanical operation device. In the whole operation process, there is visual perception but no tactile perception, and the operation process largely depends on the surgeon's anatomical knowledge and surgical skills. Additionally, although the flexibility of the operating system is greatly increased and it can largely improve the operation scale, the flexible operation requirements present a big challenge, probably as the requirements cause system overload and the lack of sensory feedback can lead to a mechanical arm-induced injury. Furthermore, the price of the whole surgical system is high, as are the maintenance and wear costs, which places a high economic burden on hospitals and patients. Finally, the da Vinci robotic surgery system can currently only be used in soft tissue systems, meaning that it cannot be used for orthopedic surgeries.

In summary, compared with traditional open surgery or laparoscopic surgery, the da Vinci robotic surgery system has unique advantages for presacral tumor surgery. However, the present study still has certain limitations. The main limitation is that the study is retrospective and the sample size included is relatively small. Therefore, a multi-center prospective study with a large sample size to will be performed in the future to compare and analyze the clinical effects of robot-assisted da Vinci surgery versus open surgery or thoracoscopic surgery in presacral tumor surgery. The da Vinci robotic surgery system is becoming more widely used in China, and its clinical value is being recognized by more surgeons. Although this system still has some shortcomings, the continuous progress of technology and the increasing familiarity of clinicians will bring benefits to more patients with different diseases in the near future.

Acknowledgements

Not applicable.

Funding

The present study was supported by The National Natural Science Foundation of China (grant no. 81904231), the China Postdoctoral Science Foundation (grant no. 2020M672369) and the PostDoctoral Innovation Practice Post in Hubei Province (grant no. 34).

Availability of data and materials

The datasets used and/or analyzed during the current study are available from the corresponding author on reasonable request.

Authors' contributions

FP, ZZ, QW and BW performed the experiments and wrote the manuscript. FP and DS made substantial contributions to conception and design of the study. ZZ and BW were responsible for the design of the experiments. ZC and KC analyzed the experimental data. ZC, KC, JL and ZS assisted with the statistical analysis. ZS and JL critically revised the manuscript, provided final approval of the version to be published and made substantial contributions to conception and design. All authors read and approved the final manuscript.

Ethics approval and consent to participate

The present study was conducted with the approval of the Ethics Committee of Union Hospital, Tongji Medical College, Huazhong University of Science and Technology (Wuhan, China), and in line with the Declaration of Helsinki. All patients and legal guardians provided written informed consent for the present study.

Patient consent for publication

Not applicable.

Competing interests

The authors declare that they have no competing interests.

References

- Gao XH, Zhang W, Fu CG, Liu LJ, Yu ED and Meng RG: Local recurrence after intended curative excision of presacral lesions: Causes and preventions. *World J Surg* 35: 2134-2142, 2011.
- Wolpert A, Beer-Gabel M, Lifschitz O and Zbar AP: The management of presacral masses in the adult. *Tech Coloproctol* 6: 43-49, 2002.
- Shenoy S: Diagnosis and management of presacral (retrorectal) tumors. *J Gastrointest Cancer* 49: 373-378, 2018.
- Dziki Ł, Włodarczyk M, Sobolewska-Włodarczyk A, Saliński A, Salińska M, Tchórzewski M, Mik M, Trzeciński R and Dziki A: Presacral tumors: Diagnosis and treatment-a challenge for a surgeon. *Arch Med Sci* 15: 722-729, 2019.
- Saxena D, Pandey A, Bugalia RP, Kumar M, Kadam R, Agarwal V, Goyal A, Kankaria J and Jenaw RK: Management of presacral tumors: Our experience with posterior approach. *Int J Surg Case Rep* 12: 3740, 2015.
- Ohsawa M, Miguchi M, Yoshimitsu M, Oishi K, Kohashi T, Hihara J, Mukaida H, Kaneko M, Egi H, Ohdan H and Hirabayashi N: Laparoscopic excision of a retroperitoneal schwannoma: A case report. *Asian J Endosc Surg* 12: 192-196, 2019.
- Jan H, Kapoor T and Ghai V: A stepwise approach to laparoscopic enucleation and excision of retroperitoneal cysts. *J Minim Invasive Gynecol* 26: 367-368, 2019.
- Atallah S, Parra-Davila E, Melani AGF, Romagnolo LG, Larach SW and Marescaux J: Robotic-assisted stereotactic real-time navigation: Initial clinical experience and feasibility for rectal cancer surgery. *Tech Coloproctol* 23: 53-63, 2019.
- Al Tinawi B, Jessop M and Salkini MW: Utilizing da Vinci® surgical system to treat challenging urinary stones. *Urol Ann* 11: 304-309, 2019.
- Yoo JG, Kim WJ and Lee KH: Single-site robot-assisted laparoscopic staging surgery for presumed clinically early-stage ovarian cancer. *J Minim Invasive Gynecol* 25: 380-381, 2018.
- Yin J, Wu H, Tu J, Zou C, Huang G, Xie X, He Y and Shen J: Robot-assisted sacral tumor resection: A preliminary study. *BMC Musculoskelet Disord* 19: 186, 2018.
- Hu H, Wang S and Shao Z: Robot-assisted excision of multiple retroperitoneal schwannomas: A case and literature review. *Int J Clin Exp Med* 12: 2833-2837, 2019.
- Choudry HA, Nikfarjam M, Liang JJ, Kimchi ET, Conter R, Gusani NJ and Staveley-O'Carroll KF: Diagnosis and management of retroperitoneal ancient schwannomas. *World J Surg Oncol* 7: 12, 2009.
- Emohare O, Stapleton M and Mendez A: A minimally invasive pericoccygeal approach to resection of a large presacral schwannoma: Case report. *J Neurosurg Spine* 23: 81-85, 2015.
- Pennington Z, Reinshagen C, Ahmed AK, Barber S, Goodwin ML, Gokaslan Z and Sciubba DM: Management of presacral schwannomas-a 10-year multi-institutional series. *Ann Transl Med* 7: 228, 2019.
- Näf F, Choschzick M and Melcher GA: Atypical case of a painful presacral tumor. *Am J Case Rep* 16: 760-762, 2015.
- Ye SP, Shi J, Liu DN, Jiang QG, Lei X, Qiu H and Li TY: Robotic-assisted versus conventional laparoscopic-assisted total gastrectomy with D2 lymphadenectomy for advanced gastric cancer: Short-term outcomes at a mono-institution. *BMC Surg* 19: 86, 2019.
- Bo T, Chuan L, Hongchang L, Chao Z, Huaxing L and Peiwu Y: Robotic versus laparoscopic rectal resection surgery: Short-term outcomes and complications: A retrospective comparative study. *Surg Oncol* 29: 71-77, 2019.
- Pacchiarotti G, Wang MY, Kolcun JPG, Chang KH, Al Maaieh M, Reis VS and Nguyen DM: Robotic paravertebral schwannoma resection at extreme locations of the thoracic cavity. *Neurosurg Focus* 42: E17, 2017.
- Garzon-Muvdi T, Belzberg A, Allaf ME and Wolinsky JP: Intraoperative Nerve monitoring in robotic-assisted resection of presacral ganglioneuroma: Operative technique. *Oper Neurosurg (Hagerstown)* 16: 103-110, 2019.
- Jun C, Sukumaran M and Wolinsky JP: Robot-assisted resection of pre-sacral schwannoma. *Neurosurg Focus* 45 (VideoSuppl): V1, 2018.



This work is licensed under a Creative Commons Attribution-NonCommercial-NoDerivatives 4.0 International (CC BY-NC-ND 4.0) License.