

Significance of desmoplastic reactions on tumor deposits in patients with colorectal cancer

TOSHINORI KOBAYASHI¹, MITSUAKI ISHIDA², HISANORI MIKI¹, MASAHIKO HATTA¹,
MADOKA HAMADA^{1,3}, YOSHINOBU HIROSE² and MITSUGU SEKIMOTO¹

¹Department of Surgery, Kansai Medical University, Hirakata, Osaka 573-1010; ²Department of Pathology, Osaka Medical and Pharmaceutical University, Takatsuki, Osaka 569-8686; ³Department of Gastrointestinal Surgery, Kansai Medical University Hospital, Hirakata, Osaka 573-1010, Japan

Received August 15, 2022; Accepted October 27, 2022

DOI: 10.3892/ol.2022.13587

Abstract. It has been well recognized that the tumor micro-environment serves important roles in the progression and invasion of cancer. The desmoplastic reaction (DR) is a fibrous tissue reaction around tumor cells, and the prognostic significance of DR in colorectal cancer (CRC) has been established. Tumor deposits (TD) are also an important prognostic indicator of CRC. Notably, immature type DR has been linked to poor prognosis. In addition, immature type DR is significantly associated with a higher pT stage, presence of lymphovascular invasion and lymph node metastasis; however, to the best of our knowledge, the association between DR and TD has not yet been examined. The present study aimed to clarify this association. This study included 443 consecutive patients with pT3 or pT4 CRC who underwent surgical resection. The histopathological features, including DR and TD, were evaluated. Statistical analyses of the presence of TD, DR and other clinicopathological parameters were performed. The present cohort included 205 female and 238 male patients; 293 (66.1%) and 150 (33.9%) patients were classified as pT3 and pT4, respectively. Immature, intermediate and mature DR were noted in 282 (63.7%), 91 (20.5%) and 70 patients (15.8%), respectively. TD was observed in 93 (21.0%) patients. Immature type DR was significantly associated with a higher pT stage ($P<0.0001$), presence of lymph node metastasis ($P<0.0001$), lymphatic ($P=0.0007$), venous ($P<0.0001$) and perineural invasion ($P<0.0001$), and higher tumor budding (TB) ($P<0.0001$). Moreover, immature type DR was significantly associated with the presence of TD ($P<0.0001$). The

present study demonstrated a significant association between immature type DR and the presence of TD, and suggested a close relationship between lymphovascular invasion, DR, TB and TD. Additional studies are required to analyze the detailed mechanism underlying the development of immature DR in CRC to define novel treatment strategies.

Introduction

Colorectal cancer (CRC) is one of the most common carcinomas worldwide, and its clinical and therapeutic management and prognostic stratification are important issues in oncology. It has been well recognized that the tumor microenvironment plays an important role in cancer progression and invasion in various types of carcinomas, including CRC (1,2). The fibrotic stroma response is histopathologically observed around carcinoma cell nests to a greater or lesser extent [i.e. desmoplastic reaction (DR)] in various types of carcinomas. In CRC, DR has received attention for its prognostic significance (3-10), and other prognostic indicators such as tumor budding (TB) (11) and tumor deposits (TDs) have similarly received attention (12). The prognostic significance of DR in patients with CRC was first reported by Ueno *et al* (13,14), and was classified into three categories: immature, intermediate, and mature DR. They clearly demonstrated that the presence of immature type DR indicated significantly poor overall and disease-free survival, following intermediate and mature types in patients with stage II and III CRC (4,6-10). Thus, DR has been used as a useful prognostic indicator in surgically resected CRC specimens, especially for determining the treatment strategy after surgical resection (3).

TD is also an important prognostic indicator in patients with CRC and is also called 'extramural tumor deposits without lymph node structures' (12,15). TD is defined as discrete macroscopic or microscopic nodules composed of carcinoma cells located in the extramural fatty tissue, discontinuous from the primary tumor, and without lymph node structures (15). The presence of TDs is significantly correlated with a higher incidence of liver and lung metastases and poorer disease-free and overall survival (12). Thus, according to the recent classification, the presence of TD is regarded to change lymph node status to pN1c, if all lymph nodes are negative for metastasis.

Correspondence to: Dr Toshinori Kobayashi, Department of Surgery, Kansai Medical University, 2-5-1 Shinmachi, Hirakata, Osaka, 573-1010, Japan
E-mail: kobayast@hirakata.kmu.ac.jp

Abbreviations: CRC, colorectal cancer; DR, desmoplastic reaction; TB, tumor budding; TD, tumor deposit

Key words: CRC, DR, TD, prognosis

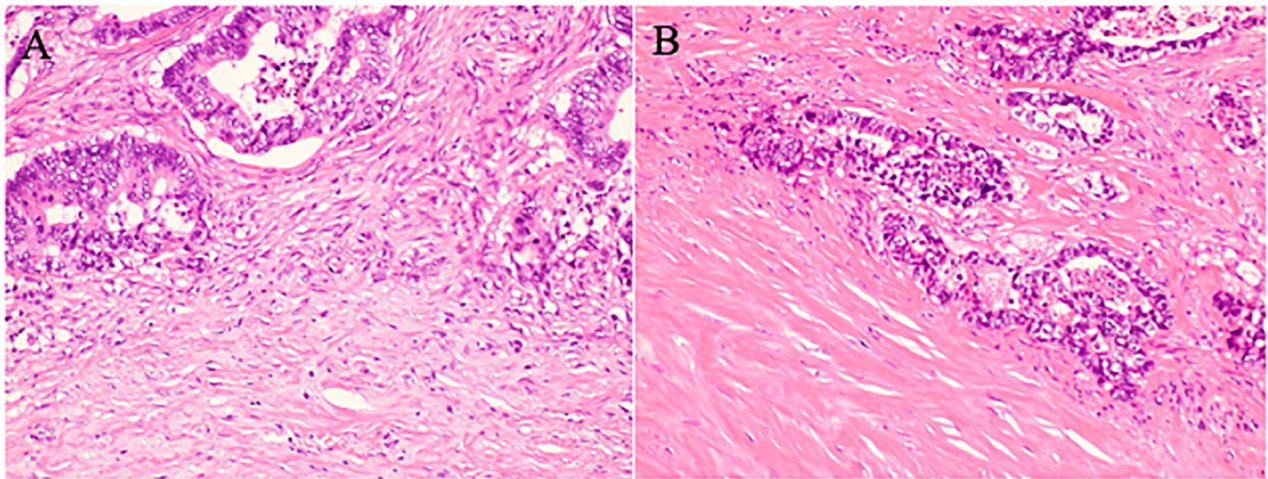


Figure 1. Histopathological features of desmoplastic reactions are shown for (A) immature type DR: myxoid stroma (lower portion) is observed in the invasive front of the carcinoma (upper portion). (B) Intermediate type: keloid-like collagen (left) is noted in the invasive front of the carcinoma (right) (hematoxylin and eosin, x200).

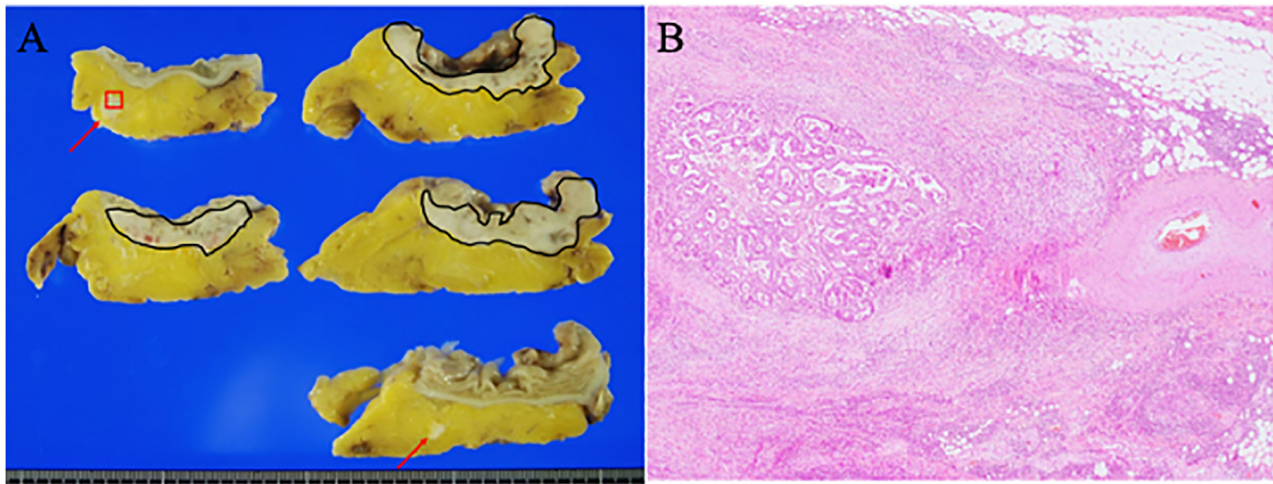


Figure 2. Histological features of the tumor deposits. (A) Macroscopic examination of the cut rectal cancer specimens shows that whitish nodules are present in the extramural rectal wall (red arrows) discontinuous from the main tumor (black circles). (B) Histopathological examination shows the presence of carcinoma cells in the extramural fatty tissue of the rectal wall (this figure is the portion of the red square of Fig. 2A) (hematoxylin and eosin, x40).

Although it has been reported that immature type DR is significantly correlated with higher pT stage, presence of lymphovascular invasion, and presence of lymph node metastases (7,10), the relationship between DR and TD in patients with CRC has not yet been examined. Thus, the present study aimed to clarify the relationship between DR type and the presence of TD.

Materials and methods

Patient selection. We selected consecutive patients with CRC who underwent surgical resection in the Department of Surgery at Kansai Medical University Hospital between January 2016 and December 2021. Patients with pT1 or pT2 were excluded from this study because DR was defined as tumors with pT3 or pT4 (3). Accordingly, 443 patients with pT3 or pT4 CRC were included in this study. Patients who had undergone neoadjuvant chemotherapy and/or radiation therapy were excluded from the study.

This retrospective, single-institution study was conducted according to the principles of the Declaration of Helsinki, and the study protocol was approved by the Institutional Review Board of Kansai Medical University Hospital (Approval #2021197). All data were anonymized. The institutional review board waived the requirement for informed consent because of the retrospective study design, as medical records and archived samples were used with no risk to the participants. Moreover, the present study did not include minors. Information regarding this study, such as the inclusion criteria and the opportunity to opt out, was provided through the institutional website (<https://www.kmu.ac.jp/hirakata/hospital/2671t800001356c-att/a1642567101597.pdf>).

Histopathological analysis. Surgically resected specimens were fixed with formalin, sectioned, and stained with hematoxylin and eosin. Two researchers (TK and MI) independently

Table I. Clinicopathological features between immature and intermediate/mature desmoplastic reactions.

| Variables | Desmoplastic reaction category | | P-value |
|---------------------------|--------------------------------|--------------------------------|---------|
| | Immature, n=282 (%) | Intermediate/Mature, n=161 (%) | |
| Sex | | | 0.4902 |
| Male | 148 (52.5) | 90 (55.9) | |
| Female | 134 (47.5) | 71 (44.1) | |
| Median age, years (range) | 72.5 (21-96) | 74 (37-99) | 0.2291 |
| Location | | | 0.1845 |
| Right side | 140 (49.7) | 90 (55.9) | |
| Left side | 100 (35.5) | 56 (34.8) | |
| Rectum | 42 (14.8) | 15 (9.3) | |
| pT | | | <0.0001 |
| pT3 | 160 (56.7) | 133 (82.6) | |
| pT4a/b | 122 (43.3) | 28 (17.4) | |
| pN | | | <0.0001 |
| Negative | 108 (38.3) | 109 (67.7) | |
| Positive | 174 (61.7) | 52 (32.3) | |
| pStage ^a | | | <0.0001 |
| II | 109 (38.7) | 109 (68.6) | |
| III | 148 (52.5) | 50 (31.0) | |
| Tumor differentiation | | | 0.6115 |
| Well | 55 (19.5) | 30 (18.6) | |
| Moderate | 168 (59.6) | 104 (64.6) | |
| Poor | 35 (12.4) | 18 (11.2) | |
| Mucinous | 24 (8.5) | 9 (5.6) | |
| Lymphatic invasion | | | 0.0007 |
| Positive | 234 (83.0) | 111 (68.9) | |
| Negative | 48 (17.0) | 50 (31.1) | |
| Venous invasion | | | <0.0001 |
| Positive | 275 (97.5) | 134 (83.2) | |
| Negative | 7 (2.5) | 27 (16.8) | |
| TB | | | <0.0001 |
| TB1 | 72 (25.5) | 73 (45.3) | |
| TB2/TB3 | 210 (74.5) | 88 (54.7) | |
| Perineural invasion | | | <0.0001 |
| Positive | 222 (78.7) | 76 (47.2) | |
| Negative | 60 (21.3) | 85 (52.8) | |
| Tumor deposits | | | <0.0001 |
| Positive | 81 (28.7) | 12 (7.5) | |
| Negative | 201 (71.3) | 149 (92.5) | |

TB, tumor budding. ^a27 pStage IV patients were excluded, because metastatic lesions were not resected and histopathologically analyzed in all patients.

evaluated the histopathological features of all the tumor slides. The TNM Classification of Malignant Tumours, Eighth edition was used.

DR was classified into immature, intermediate, and mature types according to the definition by Ueno *et al* (3,7,9). Briefly, the immature type is histopathologically characterized by the presence of myxoid stroma (defined as stroma accompanied

by an amorphous mucoid material) greater than a microscopic field of x400 magnification, at the invasive front of the tumor (Fig. 1A). The intermediate type is defined by the presence of keloid-like collagen, (thick bundles of hypocellular collagen showing hyalinization) without myxoid stroma (Fig. 1B); the absence of myxoid stroma and keloid-like collagen is regarded as the mature type.

Typical histopathological features of TD are shown in Fig. 2. TB was evaluated in accordance with the 2016 International Tumor Budding Consensus Conference (16). TB was defined as a single tumor cell or a cluster of up to four tumor cells in one hotspot at the invasive front of a field measuring 0.785 mm² (16). Tumors with 0-4 buds were classified as TB1, 5-9 buds as TB2, and those with more than 10 buds as TB3 (16).

Statistical analyses. All analyses were performed using JMP, version 13.0 (SAS Institute). Correlations between the two groups were analyzed using the χ^2 test or Fisher's exact test for categorical variables. Mann-Whitney U test was used for continuous variables. Logistic regression analysis was performed to detect the odds ratios between DR type and other clinicopathological indicators. Statistical significance was set at $P < 0.05$.

Results

Patient characteristics. Table I summarizes the clinicopathological features of the present cohort. This study included 205 (46.3%) women and 238 (53.7%) men. The median age at the time of surgery was 73 years (range: 21-99 years). 293 (66.1%) patients were classified as pT3, and 150 (33.9%) patients as pT4. The tumor locations were as follows: 230 patients had tumors in the right colon (51.9%), 156 patients (35.2%) in the left colon, and 57 patients in the rectum (12.9%). Lymph node metastasis was observed in 226 patients (51.0%).

Immature, intermediate, and mature types of DR were noted in 282 patients (63.7%), 91 patients (20.5%), and 70 patients (15.8%), respectively. TD was observed in 93 (21.0%) patients. Table I summarizes the clinicopathological parameters of immature and intermediate/mature types of DR. Immature type DR was significantly correlated with a higher pT stage ($P < 0.0001$), pStage ($P < 0.0001$), presence of lymph node metastasis ($P < 0.0001$), and lymphatic ($P = 0.0007$), venous ($P < 0.0001$), and perineural invasion ($P < 0.0001$), as well as higher TB ($P < 0.0001$) compared to intermediate/mature types of DR. Moreover, immature type DR was significantly correlated with the presence of TDs ($P < 0.0001$).

Odds ratios between immature type DR and other clinicopathological indicators. Multivariate analyses were used to analyze the odds ratio (OR) between immature type DR and other clinicopathological indicators (Table II). This analysis revealed that the presence of perineural and venous invasion, a higher pT stage (pT4), and TDs were significantly correlated with immature type DR (OR, 4.905; 3.539; 3.285; 2.884, $P = 0.00001$, 0.00029, 0.00052, and 0.00131, respectively); however, histological subtypes, higher budding (TB2 and TB3), lymphatic invasion were not significantly correlated with immature type DR.

Discussion

The present study demonstrated for the first time that there is a significant correlation between TD and immature-type DR in CRC. Previous studies have shown a significant correlation between immature type DR and a higher TB and

Table II. Odds ratios between immature type desmoplastic reaction and other clinicopathological indicators.

| Variable | Odds ratio | P-value |
|----------------------------------|------------|---------|
| Perineural invasion | 4.905 | 0.00001 |
| Venous invasion | 3.539 | 0.00029 |
| pT4 | 3.285 | 0.00052 |
| Tumor deposits | 2.884 | 0.00131 |
| Tumor differentiation (Poor) | 0.863 | 0.13701 |
| Tumor differentiation (Mucinous) | 0.656 | 0.22085 |
| Tumor budding 2/3 | 0.293 | 0.50925 |
| Lymphatic invasion | 0.041 | 0.91065 |

the presence of lymphovascular invasion and lymph node metastasis (4,9,10). TD is a histopathological parameter that indicates poor prognosis in CRC (12,15). The mechanism of TD formation has been investigated, and a study revealed that more than half of the TDs have perineural and/or intravascular connections (17). Moreover, immature type DR was significantly correlated with the presence of lymphovascular and perineural invasion in the present cohort, as well as in previous reports (4,9,10). Therefore, there might be a close relationship between lymphovascular and perivascular invasion, TD, and immature type DR.

TB is also an important prognostic indicator in CRC, and the prognostic significance of TB has also been reported in other types of carcinomas, regardless of the histological type of cancer (both adenocarcinoma and squamous cell carcinoma) (18-22). For example, Noda *et al* recently analyzed the significance of DR, TB, tumor-infiltrating lymphocytes, and depth of invasion of oral squamous cell carcinoma to determine its ability to predict extranodal extension, which is an important indicator of poor prognosis for this type of carcinoma (21). They clearly demonstrated that both a higher TB and immature type DR were significantly correlated with the presence of lymphovascular invasion and lymph node metastasis. In addition, higher TB was an independent indicator for extranodal extension of oral squamous cell carcinoma using multivariate analysis, and the presence of TB and immature type DR in biopsy specimens was a useful indicator for predicting extranodal extension of oral squamous cell carcinoma (21). A significant correlation between higher TB and immature type DR was noted in the present cohort of CRC patients, which corresponded to previous reports regarding CRC (4,9,10). TB is speculated to be closely related to the epithelial-mesenchymal transition (EMT) of carcinoma cells (16). These results suggest that both higher TB and immature type DR are correlated with EMT in carcinoma cells of CRC patients (discussed below), leading to poorer prognosis in patients with CRC.

It has been speculated that the development of immature type DR is related to the tumor microenvironment, especially cancer-associated fibroblasts (CAFs) (3,10,23). CAFs are important components of the cancer stroma in various types of carcinomas, including CRC. A previous study showed that tenascin-C and fibronectin, which are involved in cancer

angiogenesis, are frequently present in immature type DR of CRC (10). Moreover, a significant correlation between high periostin expression, a protein that is related to EMT in cancer, and immature type DR in CRC tissues has been recently reported (23). Although the detailed molecular mechanism for the formation of immature type DR remains unclear, the tumor microenvironment, including CAFs, plays an important role in the development of DR. CAFs are considered to play important roles in EMT in carcinoma cells. Therefore, a close relationship between lymphovascular invasion, DR, TB, and TD may exist. Additional studies are needed to clarify the detailed molecular mechanism governing this association, leading to novel therapeutic targets for patients with CRC, especially for those with immature type DR.

Accurate risk stratification for predicting the recurrence and/or metastasis after surgical resection in patients with CRC is a very important issue for post-operative treatment strategy. The present study for the first time demonstrated the close correlation between immature-type DR and the presence of TD. This result provides information regarding one of the mechanisms between immature-type DR and poor prognosis. Additional studies are needed to clarify the molecular mechanism between immature-type DR and poor prognosis.

The present study has several limitations. First, and most importantly, this study was a single-institute retrospective analysis, which led to bias in statistical power of the study. Second, this study examined the relationship between DR and TD. The prognostic significance of DR and TD in the present cohort was not analyzed because the follow-up period was less than 5 years. Therefore, additional studies with larger numbers of CRC patients are needed to clarify the correlation between DR and TD, and their prognostic significance.

In conclusion, the present study demonstrated a significant correlation between immature type DR and the presence of TD in patients with pT3 and pT4 CRC. A close relationship between lymphovascular invasion, DR, TB, and TD is also suggested based on this study. However, additional studies are needed to analyze the detailed mechanism underlying the development of immature type DR in CRC. These studies provide important information for the risk stratification of metastasis and/or recurrence in patients with CRC and may provide needed information to novel treatment strategies.

Acknowledgements

Not applicable.

Funding

No funding was received.

Availability of data and materials

All data generated and analyzed in this study are included in this published article.

Authors' contributions

TK and MI conceived and designed the study. TK and MI performed the histopathological analysis. TK and MI confirm

the authenticity of all the raw data. TK, MI, HM, MasH, MadH, YH and MS acquired and analyzed the data. TK and MI drafted the manuscript, tables and figures. All authors have read and approved the final manuscript.

Ethics approval and consent to participate

The present study was conducted in accordance with The Declaration of Helsinki, and the study protocol was approved by the Institutional Review Board of the Kansai Medical University Hospital (protocol no. 2021197; Hirakata, Japan). All data are completely anonymized. The Institutional Review Board waived the requirement of informed consent due to the retrospective design of the study, with no risk of identity exposure for the patients. The present study did not include any minors.

Patient consent for publication

Not applicable.

Competing interests

The authors declare that they have no competing interests.

References

1. Farc O and Cristea V: An overview of the tumor microenvironment, from cells to complex networks (Review). *Exp The Med* 21: 96, 2021.
2. Li J, Chen D and Shen M: Tumor microenvironment shapes colorectal cancer progression, metastasis, and treatment responses. *Front Med (Lausanne)* 9: 869010, 2022.
3. Ueno H, Kajiwar Y, Ajioka Y, Sugai T, Sekine S, Ishiguro M, Takashima A and Kanemitsu Y: Histopathological atlas of desmoplastic reaction characterization in colorectal cancer. *Jpn J Clin Oncol* 51: 1004-1012, 2021.
4. Ueno H, Ishiguro M, Nakatani E, Ishikawa T, Uetake H, Murotani K, Matsui S, Teramukai S, Sugai T, Ajioka Y, *et al*: Prognostic value of desmoplastic reaction characterisation in stage II colon cancer: Prospective validation in a Phase 3 study (SACURA Trial). *Br J Cancer* 124: 1088-1097, 2021.
5. Ueno H, Konishi T, Ishikawa Y, Shimazaki H, Ueno M, Aosasa S, Saiura A, Shinto E, Kajiwar Y, Mochizuki S, *et al*: Primary tumor histology affects oncological outcomes independently of the anatomical extent of disease in colorectal liver metastasis. *JMA J* 3: 240-250, 2020.
6. Nearchou IP, Kajiwar Y, Mochizuki S, Harrison DJ, Caie PD and Ueno H: Novel internationally verified method reports desmoplastic reaction as the most significant prognostic feature for disease-specific survival in stage II colorectal cancer. *Am J Surg Pathol* 43: 1239-1248, 2019.
7. Ueno H, Kanemitsu Y, Sekine S, Ishiguro M, Ito E, Hashiguchi Y, Kondo F, Shimazaki H, Kajiwar Y, Okamoto K, *et al*: A multi-center study of the prognostic value of desmoplastic reaction categorization in stage II colorectal cancer. *Am J Surg Pathol* 43: 1015-1022, 2019.
8. Ueno H, Sekine S, Oshiro T, Kanemitsu Y, Hamaguchi T, Shida D, Takashima A, Ishiguro M, Ito E, Hashiguchi Y, *et al*: Disentangling the prognostic heterogeneity of stage III colorectal cancer through histologic stromal categorization. *Surgery* 163: 777-783, 2018.
9. Ueno H, Kanemitsu Y, Sekine S, Ishiguro M, Ito E, Hashiguchi Y, Kondo F, Shimazaki H, Mochizuki S, Kajiwar Y, *et al*: Desmoplastic pattern at the tumor front defines poor-prognosis subtypes of colorectal cancer. *Am J Surg Pathol* 41: 1506-1512, 2017.
10. Ueno H, Shinto E, Shimazaki H, Kajiwar Y, Sueyama T, Yamamoto J and Hase K: Histologic categorization of desmoplastic reaction: Its relevance to the colorectal cancer microenvironment and prognosis. *Ann Surg Oncol* 22: 1504-1512, 2015.

11. Studer L, Blank A, Bokhorst JM, Nagtegaal ID, Zlobec I, Lugli A, Fischer A and Dawson H: Taking tumour budding to the next frontier - a post International tumour budding consensus conference (ITBCC) 2016 review. *Histopathology* 78: 476-484, 2021.
12. Nagtegaal ID, Kniijn N, Hugen N, Marshall HC, Sugihara K, Tot T, Ueno H and Quirke P: Tumor deposits in colorectal cancer: Improving the value of modern staging-a systematic review and meta-analysis. *J Clin Oncol* 35: 1119-1127, 2017.
13. Ueno H, Jones AM, Wilkinson KH, Jass JR and Talbot IC: Histological categorisation of fibrotic cancer stroma in advanced rectal cancer. *Gut* 53: 581-586, 2004.
14. Ueno H, Jones A, Jass JR and Talbot IC: Clinicopathological significance of the 'keloid-like' collagen and myxoid stroma in advanced rectal cancer. *Histopathology* 40: 327-334, 2002.
15. Ueno H, Mochizuki H, Shirouzu K, Kusumi T, Yamada K, Ikegami M, Kawachi H, Kameoka S, Ohkura Y, Masaki T, *et al*: Multicenter study for optimal categorization of extramural tumor deposits for colorectal cancer staging. *Ann Surg* 255: 739-746, 2012.
16. Lugli A, Kirsch R, Ajioka Y, Bosman F, Cathomas G, Dawson H, El Zimaity H, Fléjou JF, Hansen TP, Hartmann A, *et al*: Recommendations for reporting tumor budding in colorectal cancer based on the International tumor budding consensus conference (ITBCC) 2016. *Mod Pathol* 30: 1299-1311, 2017.
17. Goldstein NS and Turner JR: Pericolonic tumor deposits in patients with T3N+MO colon adenocarcinomas: Markers of reduced disease free survival and intra-abdominal metastases and their implications for TNM classification. *Cancer* 88: 2228-2238, 2000.
18. Lugli A, Zlobec I, Berger MD, Kirsch R and Nagtegaal ID: Tumour budding in solid cancers. *Nat Rev Clin Oncol* 18: 101-115, 2021.
19. Li ZW, He L, Zheng Z, Zhang Q, Xu YT, Chen JY, Shi J, Huang WB and Fan XS: Combined assessment of tumour cell nest size and desmoplastic reaction as an excellent prognostic predictor in oesophageal squamous cell carcinoma. *Histopathology* 80: 1112-1120, 2022.
20. Sakaguchi T, Satoi S, Hashimoto D, Yamamoto T, Yamaki S, Hirooka S, Ishida M, Ikeura T, Inoue K, Naganuma M, *et al*: High tumor budding predicts a poor prognosis in resected duodenal adenocarcinoma. *Surg Today* 52: 931-940, 2022.
21. Noda Y, Ishida M, Ueno Y, Fujisawa T, Iwai H and Tsuta K: Novel pathological predictive factors for extranodal extension in oral squamous cell carcinoma: A retrospective cohort study based on tumor budding, desmoplastic reaction, tumor-infiltrating lymphocytes, and depth of invasion. *BMC Cancer* 22: 402, 2022.
22. Kosaka H, Ishida M, Ueno M, Komeda K, Hokutou D, Iida H, Hirokawa F, Matsui K, Sekimoto M and Kaibori M: Tumor budding may be a promising prognostic indicator in intrahepatic cholangiocarcinoma: A multicenter retrospective study. *Ann Gastroenterol Surg*, 2022 (In press).
23. Sueyama T, Kajiwaru Y, Mochizuki S, Shimazaki H, Shinto E, Hase K and Ueno H: Periostin as a key molecule defining desmoplastic environment in colorectal cancer. *Virchows Arch* 478: 865-874, 2021.



This work is licensed under a Creative Commons Attribution-NonCommercial-NoDerivatives 4.0 International (CC BY-NC-ND 4.0) License.