

Treatment of spinal rhabdomyosarcoma in adults: A case report and literature review of current evidence

SUIYONG DU^{1,2,3*}, PANPAN HU^{1,2*}, HONGQING ZHUANG⁴, SHAOMIN YANG⁵ and FENG WEI^{1,2}

¹Department of Orthopaedics; ²Beijing Key Laboratory of Spinal Disease Research, Peking University Third Hospital, Beijing 100191; ³Department of Spine Surgery, 521 Hospital of Norinco Group, Xi'an, Shanxi 710065; Departments of ⁴Radiation Oncology and ⁵Pathology, Peking University Third Hospital, Beijing 100191, P.R. China

Received October 10, 2022; Accepted January 5, 2023

DOI: 10.3892/ol.2023.13685

Abstract. Spinal rhabdomyosarcoma (RMS) is a rare yet highly malignant tumor in adults. Literature on this entity is lacking and no mature treatment guideline is currently available. The treatment arsenals include surgery, radiotherapy and chemotherapy, being used singly or jointly. However, the prognosis is dismal, with a mean overall survival period of 10 months. Thus, any case of this disease with encouraging outcomes shall be shared. A case of a middle-aged female patient with spinal RMS was presented in the current report. The patient suffered from back pain but was neurologically intact. The patient underwent a total *en-bloc* spondylectomy of the T11-L2 vertebrae and spinal reconstruction with 3D-printed prosthetic vertebrae. Afterwards, the patient received a rigid schedule of stereotactic body radiotherapy (SBRT) and chemotherapy. To date, the patient has survived for 40 months, with the preservation of neurological function and sustained mitigation of local pain after the operation. The patient suffered subcutaneous colonization of tumor cells and pulmonary metastasis 10 months postoperatively, but obtained a long locoregional control of 19 months. In conclusion, total *en-bloc* lesion resection is indicated for the treatment of isolated, primary spinal RMS in adults. Some authors reported that the usage of new surgical tools and instruments has facilitated surgery, which was previously invasive and technically challenging. Advanced radiotherapy techniques, such as SBRT, which were proven effective for local lesion control, should be implemented early after the operation. Chemotherapy remains the mainstay of treatment, but further research and evidence for the efficacy of regimens specifically for adults are required.

Introduction

Rhabdomyosarcoma (RMS) is a rare yet highly malignant cancer type in the adult population, with an estimated incidence of 0.9 per million per year (1). It may affect numerous structures and organs, including the head and neck, genitourinary tract, extremities and trunk (1,2). Adults with spinal RMS have a significantly poor prognosis. Wang *et al* (3) reported that the median overall survival (OS) period was merely 10 months, in a retrospective study of 11 cases and review of 22 cases from the previous literature. They indicated that the cases with radical resection had a longer median OS period (3). Treatment guidelines and recommendations for adult spinal RMS were established in reference to those for children and experts' experience, rather than studies of high quality (3-6).

In the present study, the case of a middle-aged female with isolated spinal RMS involving T11 to L2 vertebrae was reported. The patient was scheduled to receive a multi-modality treatment regimen of total resection with 3D-print reconstruction, early start of stereotactic body radiotherapy (SBRT) and chemotherapy. Consequently, the patient enjoyed a long survival period and the outcome was encouraging. Furthermore, the literature regarding spinal RMS was reviewed and an overview of the evidence of the efficacy of treatment modalities currently available was presented. The case described herein provides useful information that will be of value to the clinical community.

Case report

Case presentation. A 46-year-old female patient visited Peking University Third Hospital (Beijing, China) in November 2017 due to progressive back pain. However, the patient had no symptoms or signs of neurological impairment as determined by physical examination. The patient was practically afebrile and in an overall good condition. The patient had no history of malignancies, known history of tuberculosis infection or invasive interventions on the spine. The results of laboratory tests were generally normal and serological examination for tumor markers of breast, lung, gastrointestinal and liver neoplasms was negative.

Imaging work-ups. Computed tomography (CT) scans revealed large expansile, osteolytic lesions mainly dwelling in

Correspondence to: Dr Feng Wei, Department of Orthopaedics, Peking University Third Hospital, 49 North Garden Road, Haidian, Beijing 100191, P.R. China
E-mail: weifeng@bjmu.edu.cn

*Contributed equally

Key words: 3D printing, case report, rhabdomyosarcoma, spine, stereotactic body radiotherapy, total *en-bloc* spondylectomy

the right halves of the T12 and L1 vertebral bodies (Fig. 1). The lesion on magnetic resonance imaging scans revealed homogeneously T1-weighted hypointense and T2-weighted hyperintense signals. On axial images, possible involvement of the right crus of the diaphragm was noted. The images of positron emission tomography-CT revealed significantly elevated uptake of 18-fluorodeoxyglucose in the T11-L2 region.

Surgical strategies and techniques. The patient of the current study presented with an isolated spinal lesion, without any distant metastasis or visceral organs involved. Furthermore, the involvement of paraspinal tissues was relatively limited (Fig. 1G-K), which remained the possibility of total *en-bloc* resection. Thus, it was decided to surgically resect the tumor lesion.

Prior to the operation, the feeding vessels of the tumor and Adamkiewicz artery were evaluated by digital subtraction angiography. Just the feeding vessels were embolized while keeping the Adamkiewicz artery untouched. According to the extent of the tumor invading the vertebral body, anterior dissection was performed via a retroperitoneal approach with the patient in the left decubitus position (Fig. 2). The margins of the tumor were ill-defined and no intact capsule was detected. The attaching segment of iliopsoas and suspicious portion of the right diaphragm crus were cut off. The anterior exposure was practically fulfilled by blunt dissection with fingers. During the procedure, the anterior one-third of the intervertebral disc was removed.

The patient was then placed in the prone position and sufficient exposure from T8 to L5 was established. The bilateral nerves of T11, T12 and L1 were ligated and cut, while the L2 nerves were preserved. Dissection along the vertebral bodies was then performed in a forward direction to conjoin with the anterior dissection. The remaining posterior intervertebral disc was removed. The specimen was rotated out, entirely and uneventfully. The reconstruction was then made with a patient-tailored 3D-printed prosthesis and the fixation levels were at T8, T9 and T10, and L3, L4 and L5. The 3D-printed implant had two lateral holes, which were connected with the posterior rods by the screws. The implant was fabricated with titanium alloy and contained a porous microstructure mimicking cancellous bone, so no additional bone graft was required to achieve the final fusion.

The postoperative pathological examinations were conducted according to standard procedures and the results were consistent with embryonal RMS. The margin of the specimen was clear of tumor infiltration.

Rehabilitation and pain management. At one week after the operation, the patient was transferred to the rehabilitation center of Peking University Third Hospital (Beijing, China), to facilitate the recovery of the patient's physical functions. During the postoperative hospital stay, the patient reported slight to moderate pain and was prescribed oral non-steroidal anti-inflammatory drugs to control her pain.

RT and chemotherapy. The patient started SBRT 40 days after the operation. The radioactive dose was 35 Gy in five fractions. After another 40 days, the patient was administered six cycles of chemotherapy and the regimen was six cycles of ifosfamide + adriamycin (Fig. 3).

Post-treatment course and events. During the chemotherapy period, a subcutaneous nodule was detected, which was inferred to be the colonization of disseminated tumor cells in the procedure of CT-guided biopsy. The patient underwent extensive skin and subcutaneous removal to radically resect the lesion (Fig. 4). Pulmonary metastasis was detected 10 months after the operation. A video-assisted thoracoscopic surgery was arranged to resect the metastatic lesion, which was followed by three cycles of ifosfamide + etoposide + vincristine.

Local recurrence appeared 19 months after the operation in the right crus of the diaphragm (Fig. 5). At the same time, pulmonary metastasis exhibited slight progress. Therefore, SBRT was implemented at these two sites.

Latest follow-up. At the latest follow-up, which was 40 months after the index operation, it was indicated that the local recurrence was stable, but that pulmonary metastasis progressed with new nodules emerging. Therefore, the patient was prepared for another cycle of SBRT for progressing pulmonary metastasis.

Discussion

Among adults with RMS, patients with spinal involvement have a much poorer prognosis (3). The 5-year survival rate of adult RMS was reported to be 27% (7), but there were no such data for the subgroup of spinal RMS. In the series of Wang *et al* (3), the longest survival period was 18 months. By contrast, the patient of the present study has survived for >40 months since the index surgery in December 2017. Considering the patient is of moderate health and tolerant to another cycle of SBRT, she may presumably have a long life expectancy.

A multi-modalities regimen is common practice for the treatment of spinal RMS and total *en-bloc* resection remains a first choice, particularly for an isolated lesion (3-6). This malignancy is of an aggressive nature. Invasion to multiple vertebrae and juxtaposing soft tissues may have occurred by the time of diagnosis (3). The challenges of surgery include how to radically resect the tumor and reconstruct the spine at the same time. The former challenge is the surgeons' experience and surgical skills concerned; the latter has been mitigated with the application of a customized 3D-printed vertebral body (8).

The patient of the current study presented with a long-flank soft tissue mass anterior to the vertebral bodies and suspicious involvement of the right crus of the diaphragm. An anterior dissection and exposure would be indicated in this setting. The suspicious segment of the right diaphragm crus was cut off to secure a clear margin. The posterior manipulations were technically challenging. To facilitate the removal, certain nerve roots were required to be sacrificed, which, however, left no persistent sequelae. During the procedure, caution was taken to avoid tear of the dural sac and the pleura/peritoneum on the ventral side. The surgeon should be alert to the dissemination of tumor cells in the surgical bed, which should be avoided. In the present case, distilled water and cisplatin irrigation were used to avoid the colonization of tumor cells *in situ*.

Radiotherapy has demonstrated its efficacy for local control after surgery (4-6,9,10). In the previous literature, numerous advanced and effective delivery techniques, including intensity-modulated RT, brachytherapy, proton beam RT and SBRT,

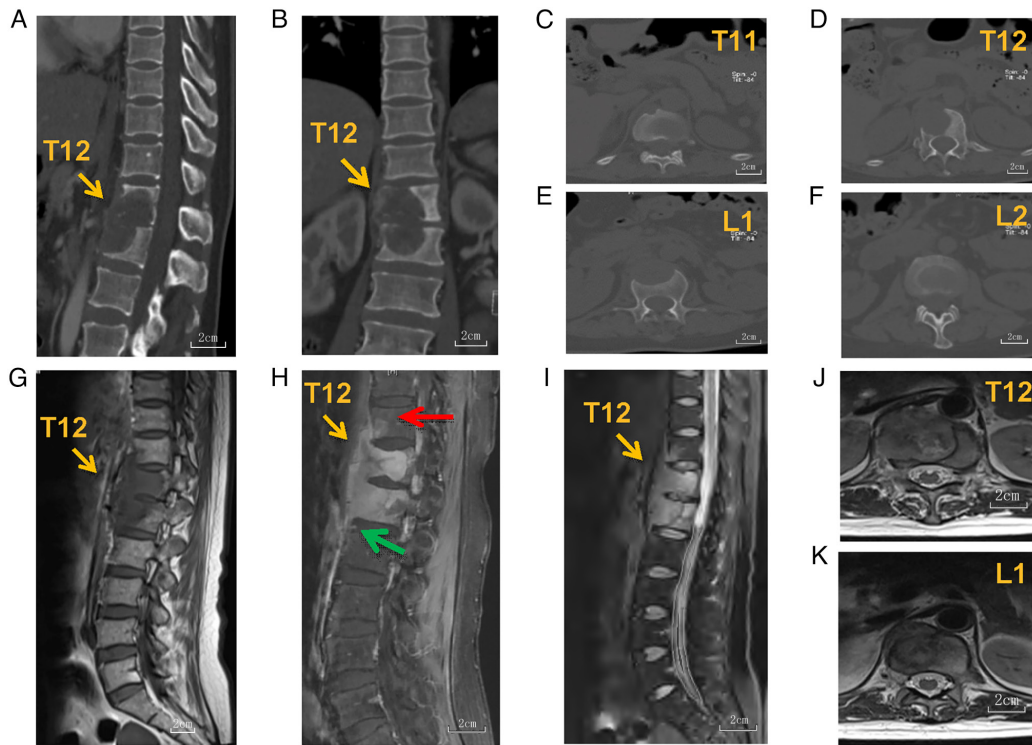


Figure 1. Presentation of the imaging prior to the operation. (A-F) Computed tomography sagittal (A) and coronal (B) reconstruction films revealed an osteolytic, expansile lesion in the spine, with (C) T11, (D) T12, (E) L1 and (F) L2 being invaded. (G-I) On magnetic resonance imaging scans, the lesion was (G) T1-weighted hypointensive and (I) T2-weighted hyperintensive, with edema signals in the normal parts of the vertebrae. (H) The lesion displayed homogeneous enhancement on T1-enhanced films. The lesion invaded the (C and H) anterior, lower corner of T11 (red arrow in H) and (F and H) anterior superior corner of L2 (green arrow in H). (H) A long-flank soft tissue mass was revealed along the anterior T11 to the superior corner of the L2 vertebra. From the images of (J) T12 and (K) L1 planes, the right crus of the diaphragm had a possible involvement with the tumor, whilst the periaortic space stayed uninvaded (scale bars, 2 cm).

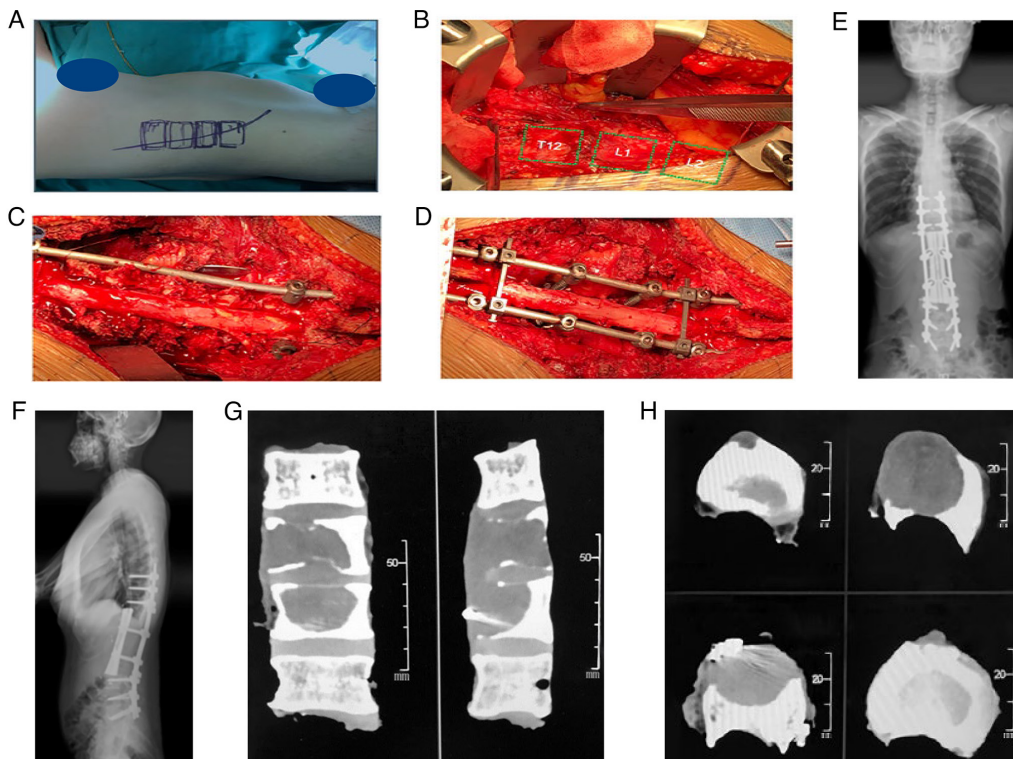


Figure 2. (A) The patient was positioned on her left side. (B) An oblique incision was made until the exposure of the T11 to L2 vertebrae. (C) After the anterior dissection, the posterior elements of the target vertebrae, including bilateral pedicles, were removed in the posterior operation. (D) A 3D-print prosthetic vertebra was implanted after the total resection of the T11 to L2 vertebrae. Postoperative (E) anteroposterior and (F) lateral X-rays were taken. Computed tomography (G) reconstruction and (H) axial images of the specimen revealed the completeness of resection. (G) Scale bar, 50 mm; (H) scale bar, 20 mm.

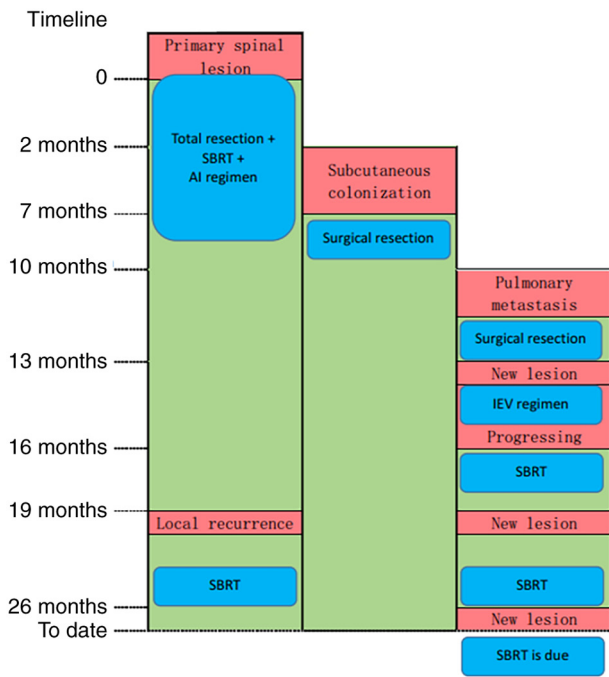


Figure 3. Timeline of the treatment and events of the patient. The time in the left column refers to the period after the index spinal surgery. Red columns represent new emerging or progressing lesions after anti-tumor therapies; green columns represent tumor-free or stable lesions after the therapies. SBRT, stereotactic body radiotherapy; AI, adriamycin and ifosfamide; IEV, ifosfamide, etoposide and vincristine; mon, months.

have been described (4,10). SBRT is an image-guided modality and may be planned well according to the postoperative and re-irradiation settings, allowing accurate delivery of the local ablative dose (9). This technique has a prominent advantage for the tumors around the cord; thus, this delivery technique was applied to the patient of the present study. Usually, RT is performed between 6 and 12 weeks after the operation, but an earlier start forebodes a better local control for parameningeal RMS (4,10). Considering the relatively quick healing of the wound and timely restoration of the patient's general condition, SBRT on the operative area, particularly the right diaphragm crus, was started 40 days after the operation, which led to local recurrence occurring later than previously reported (3). In previous studies, a wide range of RT doses, from 20 to 70 Gy, is used (3,10). The final dose administered to the patient of the present study was decided based on the studies and treatment experience of low-risk pediatric patients (4). The patient literally had a period of local control for 19 months until a relapse occurred in the right diaphragm crus. The relapse in this area was preoperatively expected, considering the existence of tumor invasion. However, it would be too invasive to remove the entire diaphragm and paraspinal muscle, as this may cause severe respiratory dysfunction and visceral complications. In the present study, SBRT was administered as 5 fractions, which was rather like intensity-modulated RT, as SBRT in single- and multi-fractions may provide satisfactory efficacy for spinal tumors (11). The combination of total *en-bloc* tumor resection and earlier start of adjuvant SBRT may provide satisfying local control for isolated spinal RMS (11).

Due to the small number of adult patients and lack of centralization of care for them, there is currently no

standardized recommended chemotherapy regimen for adults with RMS. The general practice is to refer to regimens for pediatric patients. The mainstay regimen for pediatric patients is vincristine, actinomycin D and cyclophosphamide (VAC) (2-4). The combination and dose of these agents are required to be balanced over the efficacy and cytotoxicity. Previous studies emphasized the incorporation of cyclophosphamide into the regimen (3,12-16). However, the cumulative toxicity must be heeded for pediatric patients, which usually impedes the administration of a sufficient dose. Therefore, in the adult patient of the present study, the dose of cyclophosphamide was intensified with caution (nine cycles in total). The efficacy of doxorubicin did not stand firmly in the reexamination in a multicenter, randomized controlled trial, in spite of numerous studies stating it as the standard of care (1,17). In addition, the use of other traditional agents was sporadically reported and their efficacy requires further examination (4,12,13,18). Certain on-going prospective trials continue to examine and develop new chemotherapy agents and molecular therapies (19). Furthermore, another modality is rising and has gained substantial interest. Targeted therapy was revealed to have encouraging potential in various clinical/preclinical studies and is likely to provide a big advance in the care of RMS (3,19-21).

In a national study including 449 adults with RMS, Bompas *et al* (1) reported that non-alveolar RMS, younger age (<25 years), R0 resection, RT and VAC-based chemotherapy regimens were relevant with a better OS in patients with localized RMS. In the patient of the present study, the employment of a 3D-printed vertebral body enabled an invasive yet complete resection of multiple vertebrae, yielding an R0 resection. The earlier start of SBRT after the operation further facilitated local control. These made a remarkable contribution to the long locoregional control period for the patient of the present study. The treatment schedule of this patient was individualized by our institutional multidisciplinary treatment team. Considering that the tumor mostly dwelled within the vertebral space and had limited involvement of surrounding soft tissue, the resection surgery was undertaken as the first step. Preoperative SBRT may reduce tumor load and remain an alternative option. However, it frequently causes severe adhesion of tumor capsule to the surrounding tissues. Regrettably, the patient of the present study developed colonization of tumor cells in the path of biopsy, which was an indication for extensive skin and subcutaneous removal. This event raises awareness of the necessity of a holistic and coordinated strategy when planning the path of biopsy and surgical incision. However, the outcome for the present patient was encouraging, suggesting that proactive treatment strategies and advances in surgical techniques and instruments still have an essential role in primary tumors of high malignancy.

Currently, there is no well-established treatment guideline for adult RM, and physicians used to refer to the treatment strategy for pediatric patients (3-6). Numerous lessons may be learned from the patient of the present study. As adult RMS is highly malignant, total *en-bloc* resection of the tumor is so far the best choice. Different from the condition in children, adult RMS is less sensitive to conventional RT and CT (1,4,12,13,18). Thus, adjuvant SBRT was performed

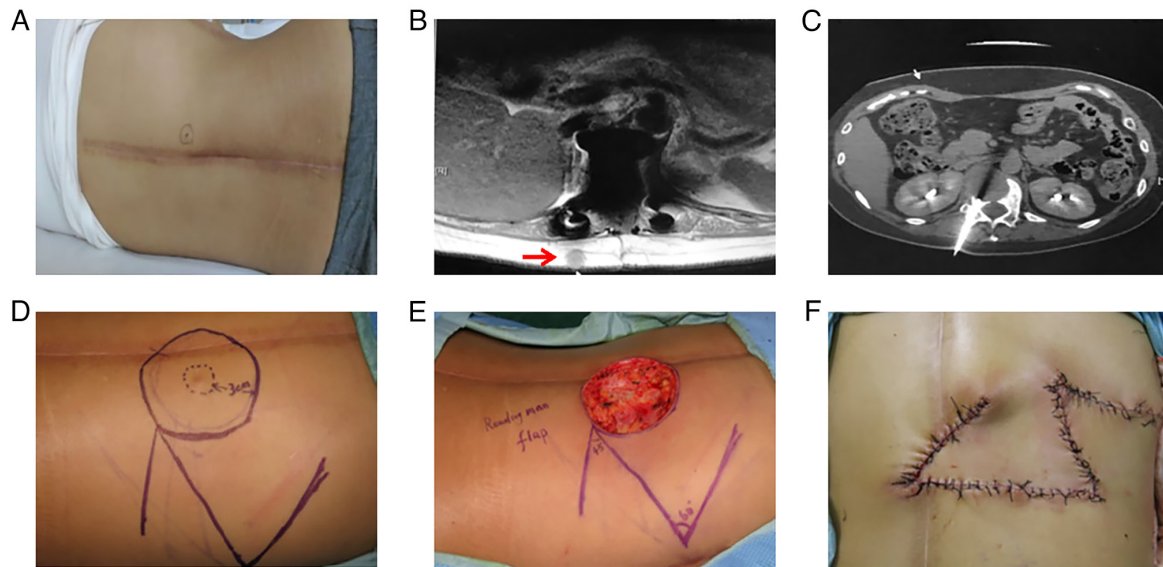


Figure 4. A subcutaneous nodule was detected 2 months after the index operation. (A) The nodule emerged near the incision. (B) Magnetic resonance imaging revealed the nodule. (C) The path of biopsy needle prior to the spinal surgery. (D) The surgery planning of radical lesion resection. (E) The nodule was radically removed. (F) A flap transposition surgery was subsequently performed.

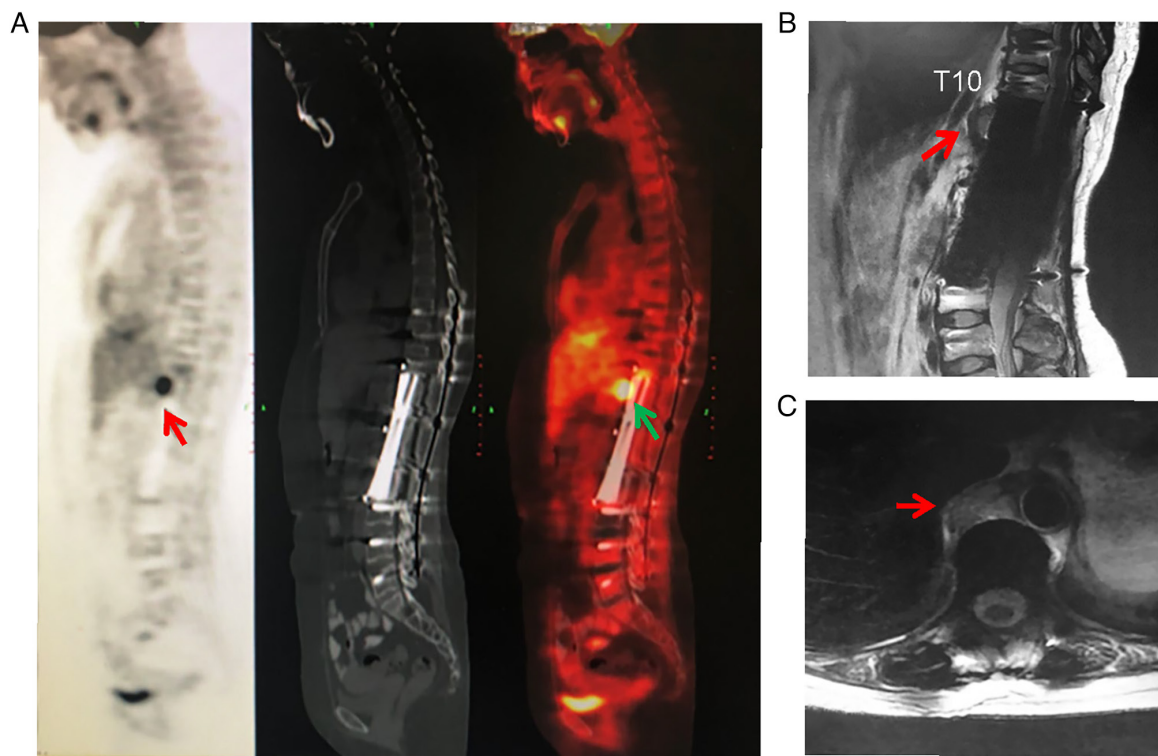


Figure 5. Local recurrence was detected in the right crus of the diaphragm 19 months after the index operation. (A) A new lesion was detected on PET-CT. In the left panel, the PET film is displayed, the CT film is provided in the middle panel and the right panel is the combined film. On magnetic resonance (B) sagittal reconstruction and (C) axial images, the lesion was also detected. PET, positron emission tomography.

after the operation. Furthermore, the puncture biopsy channels were planned to be removed together when designing the operation plan prior to surgery. If the tumor has invaded the diaphragm and paraspinal muscles, it is technically impossible to remove the entire diaphragm and iliopsoas muscle. However, it may be recommended that the invaded part of muscles shall be dissected in an extracapsular way, leaving

the tumor untouched intraoperatively, and then remove the whole specimen.

Acknowledgements

The authors would like to thank Dr Baoshan Cao and Dr Li Liang (Department of Medical Oncology and Radiation

Sickness, Peking University Third Hospital, Beijing, China) for their support in the preparation of this article.

Funding

This study was supported by the institutional research fund (Peking University Third Hospital; grant no. Y73504-03). The fund had no influence on the design of the study, the collection, analysis or interpretation of data or the preparation of the manuscript.

Availability of data and materials

The datasets used and/or analyzed during the current study are available from the corresponding author on reasonable request.

Authors' contributions

SD and PH designed the report, reviewed the patient information, collected and processed the clinical data and drafted the manuscript. SY performed the pathological diagnosis. HZ performed RT and chemotherapy. FW designed the study, selected the patient, processed the data and supervised the study. SD and PH confirm the authenticity of all the raw data. All authors read and approved the final version of the manuscript.

Ethics approval and consent to participate

The preparation of this retrospective study was approved by the Ethics Committee Board of Peking University Third Hospital (Beijing, China). Written informed consent was obtained from the patient.

Patient consent for publication

Written consent to publication of clinical data and images was obtained from the patient.

Competing interests

The authors declare that they have no competing interests.

References

1. Bompas E, Campion L, Italiano A, Le Cesne A, Chevreau C, Isambert N, Toulmonde M, Mir O, Ray-Coquard I, Piperno-Neumann S, *et al*: Outcome of 449 adult patients with rhabdomyosarcoma: An observational ambispective nationwide study. *Cancer Med* 7: 4023-4035, 2018.
2. Kaseb H, Kuhn J and Babiker HM: Rhabdomyosarcoma. In: StatPearls [Internet]. Treasure Island (FL): StatPearls Publishing, 2022.
3. Wang T, Gao X, Yang J, Guo W, Wu Z, Tang L, Cao S, Cai X, Liu T, Jia Q and Xiao J: Treatment strategies and outcomes for spinal rhabdomyosarcoma: A series of 11 cases in a single center and review of the literature. *Clin Neurol Neurosurg* 192: 105729, 2020.
4. Gurria JP and Dasgupta R: Rhabdomyosarcoma and extraosseous ewing sarcoma. *Children (Basel)* 5: 165, 2018.
5. Raney RB, Maurer HM, Anderson JR, Andrassy RJ, Donaldson SS, Qualman SJ, Wharam MD, Wiener ES and Crist WM: The intergroup rhabdomyosarcoma study group (IRSG): Major lessons from the IRS-I through IRS-IV studies as background for the current IRS-V treatment protocols. *Sarcoma* 5: 9-15, 2001.
6. Spreafico F, Ferrari A, Mascarin M, Collini P, Morosi C, Basoni D, Biassoni V, Schiavello E, Gandola L, Gattuso G, *et al*: Wilms tumor, medulloblastoma, and rhabdomyosarcoma in adult patients: lessons learned from the pediatric experience. *Cancer Metastasis Rev* 38: 683-694, 2019.

7. Sultan I, Qaddoumi I, Yaser S, Rodriguez-Galindo C and Ferrari A: Comparing adult and pediatric rhabdomyosarcoma in the surveillance, epidemiology and end results program, 1973 to 2005: An analysis of 2,600 patients. *J Clin Oncol* 27: 3391-3397, 2009.
8. Wei F, Li Z, Liu Z, Liu X, Jiang L, Yu M, Xu N, Wu F, Dang L, Zhou H, *et al*: Upper cervical spine reconstruction using customized 3D-printed vertebral body in 9 patients with primary tumors involving C2. *Ann Transl Med* 8: 332, 2020.
9. Osborn VW, Lee A and Yamada Y: Stereotactic body radiation therapy for spinal malignancies. *Technol Cancer Res Treat* 17: 1533033818802304, 2018.
10. Ladra MM, Szymonifka JD, Mahajan A, Friedmann AM, Yong Yeap B, Goebel CP, MacDonald SM, Grosshans DR, Rodriguez-Galindo C, Marcus KJ, *et al*: Preliminary results of a phase II trial of proton radiotherapy for pediatric rhabdomyosarcoma. *J Clin Oncol* 32: 3762-3770, 2014.
11. Gong Y, Xu L, Zhuang H, Jiang L, Wei F, Liu Z, Li Y, Yu M, Ni K and Liu X: Efficacy and safety of different fractions using stereotactic body radiotherapy for spinal metastases: A systematic review. *Cancer Med* 8: 6176-6184, 2019.
12. Arndt CA, Stoner JA, Hawkins DS, Rodeberg DA, Hayes-Jordan AA, Paidas CN, Parham DM, Teot LA, Wharam MD, Breneman JC, *et al*: Vincristine, actinomycin, and cyclophosphamide compared with vincristine, actinomycin, and cyclophosphamide alternating with vincristine, topotecan, and cyclophosphamide for intermediate-risk rhabdomyosarcoma: Children's oncology group study D9803. *J Clin Oncol* 27: 5182-5188, 2009.
13. Arndt CA, Hawkins DS, Meyer WH, Sencer SF, Neglia JP and Anderson JR: Comparison of results of a pilot study of alternating vincristine/doxorubicin/cyclophosphamide and etoposide/ifosfamide with IRS-IV in intermediate risk rhabdomyosarcoma: A report from the children's oncology group. *Pediatr Blood Cancer* 50: 33-36, 2008.
14. Walterhouse DO, Pappo AS, Meza JL, Breneman JC, Hayes-Jordan A, Parham DM, Cripe TP, Anderson JR, Meyer WH and Hawkins DS: Reduction of cyclophosphamide dose for patients with subset 2 low-risk rhabdomyosarcoma is associated with an increased risk of recurrence: A report from the soft tissue sarcoma committee of the children's oncology group. *Cancer* 123: 2368-2375, 2017.
15. Dumont SN, Araujo DM, Munsell MF, Salganick JA, Dumont AG, Raymond KA, Linassier C, Patel S, Benjamin RS and Trent JC: Management and outcome of 239 adolescent and adult rhabdomyosarcoma patients. *Cancer Med* 2: 553-563, 2013.
16. Gupta AA, Anderson JR, Pappo AS, Spunt SL, Dasgupta R, Indelicato DJ and Hawkins DS: Patterns of chemotherapy-induced toxicities in younger children and adolescents with rhabdomyosarcoma: A report from the children's oncology group soft tissue sarcoma committee. *Cancer* 118: 1130-1137, 2012.
17. Bisogno G, Jenney M, Bergeron C, GallegoMelcón S, Ferrari A, Oberlin O, Carli M, Stevens M, Kelsey A, De Paoli A, *et al*: Addition of dose-intensified doxorubicin to standard chemotherapy for rhabdomyosarcoma (EpSSG RMS 2005): A multicentre, open-label, randomised controlled, phase 3 trial. *Lancet Oncol* 19: 1061-1071, 2018.
18. Hawkins DS, Chi YY, Anderson JR, Tian J, Arndt CAS, Bomgaars L, Donaldson SS, Hayes-Jordan A, Mascarenhas L, McCarville MB, *et al*: Addition of vincristine and irinotecan to vincristine, dactinomycin, and cyclophosphamide does not improve outcome for intermediate-risk rhabdomyosarcoma: A report from the children's oncology group. *J Clin Oncol* 36: 2770-2777, 2018.
19. Hawkins DS, Gupta AA and Rudzinski ER: What is new in the biology and treatment of pediatric rhabdomyosarcoma? *Curr Opin Pediatr* 26: 50-56, 2014.
20. Weitao Y, Fangxing W, Qiqing C and Jiaqiang W: Efficacy and safety of apatinib in advanced sarcoma: An open-label, nonrandomized, single-center study of 45 patients. *Anticancer Drugs* 30: e0778, 2019.
21. van Erp AEM, Versleijen-Jonkers YMH, van der Graaf WTA and Fleuren EDG: Targeted therapy-based combination treatment in rhabdomyosarcoma. *Mol Cancer Ther* 17: 1365-1380, 2018.



This work is licensed under a Creative Commons Attribution-NonCommercial-NoDerivatives 4.0 International (CC BY-NC-ND 4.0) License.