

# Spontaneous rupture-induced life-threatening mediastinal mixed germ cell tumor: A case report and therapeutic considerations

XIAOSONG LI<sup>1\*</sup>, SHENGHAN XU<sup>2\*</sup>, YUNBIN LI<sup>1</sup>, YANPING TANG<sup>1</sup>,  
KAIYING WANG<sup>1</sup>, YUMENG LEI<sup>1</sup>, JIAN MA<sup>1</sup> and JIAN LI<sup>1</sup>

<sup>1</sup>Department of Thoracic Surgery, The Affiliated Hospital of Guizhou Medical University, Guiyang, Guizhou 550004;

<sup>2</sup>Department of Urology, The People's Hospital of Liupanshui, Liupanshui, Guizhou 553001, P.R. China

Received September 29, 2023; Accepted February 9, 2024

DOI: 10.3892/ol.2024.14316

**Abstract.** Spontaneous rupture and hemorrhage of mediastinal germ cell tumors is a rare occurrence. In the current report, the case of a 20-year-old male patient who was admitted with chest tightness and dyspnea is presented. An urgent chest CT scan revealed a large tumor in the right anterior mediastinum, measuring ~12 cm in diameter, with associated intratumoral hemorrhage. An emergency thoracotomy was performed to excise the lesion, which revealed that the bleeding was caused by a ruptured tumor. Postoperative pathological findings revealed a mediastinal mixed germ cell tumor consisting of four pathological types: Embryonal carcinoma, seminoma, yolk sac tumor and immature teratoma. Postoperatively, the patient showed marked improvement in the symptoms of dyspnea. However, the follow-up outcome was poor, and the patient succumbed 2 months after surgery. To the best of our knowledge, there are no reports of rupture and hemorrhage involving >4 mixed germ cell tumors. In the present report, the experience of the treatment of the patient is summarized, and literature was reviewed to improve clinicians' awareness of the disease.

## Introduction

Mixed germ cell tumors consist of  $\geq 2$  types of germ cells and usually occur in the gonads, with rare occurrences in the mediastinum (1). The most common combination observed is that of astrocytoma and yolk sac tumor derived from primordial germ cells of the embryonic gonads. To the best of our knowledge, only one case of spontaneous rupture and

bleeding in mediastinal mixed germ cell tumor has been reported. Typically, these tumors consist of a combination of two cell types (1,2), and a single case involving three cell types has been reported, including yolk sac tumor, immature teratoma and a small amount of embryonal carcinoma (3). However, there have been no reports of mixed germ cell tumor with >4 cell types. To the best of our knowledge, the present study is the first to report a mediastinal mixed germ cell tumor presenting with these four pathological types, including embryonal carcinoma, seminoma, yolk sac tumor and immature teratoma. Mixed mediastinal germ cell tumors can spontaneously rupture and bleed, leading to hemothorax (1). Emergency thoracotomy is commonly considered for treatment, but the prognosis remains poor (3). Upon reviewing the literature, only one related report where the patient had a fair prognosis following surgical treatment was identified (1). However, the patient of the present report experienced a poor prognosis post-surgery; their vital signs and laboratory tests, including hemoglobin levels, showed no marked abnormalities upon admission. Additionally, surgery might accelerate tumor progression. It was hypothesized that conservative treatment as an initial approach was a viable option under these circumstances. The current report presents the approach adopted for the treatment of a 20-year-old male patient with mixed germ cell tumor aiming to provide references for the treatment of similar diseases in the future.

## Case report

In February, 2021, a 20-year-old male patient was admitted to The Affiliated Hospital of Guizhou Medical University (Guiyang, China) with complaints of cough and expectoration for >20 days, chest tightness and shortness of breath for >1 week. The patient had started coughing and expectorating copious amounts of yellow-white purulent sputum without any apparent cause >20 days prior to admission. The patient underwent a thoracic computed tomography (CT) scan at Fuquan City People's Hospital (Fuquan, China) in January, 2021, which revealed an anterior superior mediastinal mass, suggestive of thymoma with a likelihood of malignancy, accompanied by a small amount of right-sided pleural effusion. Subsequently, the patient was transferred to The Third Affiliated Hospital of Guizhou Medical University (Guizhou, China) for further

---

*Correspondence to:* Dr Jian Li, Department of Thoracic Surgery, The Affiliated Hospital of Guizhou Medical University, 28 Guiyi Street, Guiyang, Guizhou 550004, P.R. China  
E-mail: leesward@163.com

\*Contributed equally

**Key words:** hemothorax, mixed germ cell tumor, mediastinal mixed germ cell tumor, extragonadal germ cell tumor

diagnosis and treatment in January, 2021. At that point, the patient presented with chest tightness, shortness of breath and difficulty breathing, considered to be secondary to tumor compression. A repeat of thoracic CT showed mediastinal occupation and extensive right-sided pleural effusion. These CT images were performed at Fuquan City People's Hospital and The Third Affiliated Hospital of Guizhou Medical University, therefore only the report results were provided by the patient. Thoracic cavity puncture and tube drainage were performed, resulting in the extraction of a moderate amount of bloody fluid which alleviated the symptoms of dyspnea. Due to the severity of the patient's condition, and at the request of the patient and their family, the patient was urgently transferred to The Affiliated Hospital of Guizhou Medical University with the initial diagnosis of 'mediastinal occupation'. The patient reported no family history of genetic or infectious diseases, or prior surgeries. Physical examination revealed a slight leftward deviation of the trachea, fullness in the right thorax and widened intercostal spaces. The chest wall was non-tender, the left voice tremor was diminished and there was no pleural friction. While the respiratory sound in the left lung was clear, it was absent in the right lung. No bulging in the precordial area, normal cardiac borders, strong heart sounds, a heart rate of 95 beats/min and no pathological murmurs over the valve auscultation areas were observed. After admission, laboratory test results showed that the red blood cell count was  $3.83 \times 10^{12}$  cells/l [healthy adult range,  $(3.5-5.5) \times 10^{12}$  cells/l], and the hemoglobin level was 116.00 g/l (healthy adult range, 130-175 g/l); however, the platelet count was 523.00 cells/l [healthy adult range,  $(125-300) \times 10^{12}$  cells/l], the fibrinogen level was 6.08 g/l (healthy adult range, 2-4 g/l), the D-Dimer level was 7.8  $\mu\text{g/ml}$  (healthy adult range, 0-1  $\mu\text{g/ml}$ ) and the bicarbonate radical level was 27.00 mmol/l (healthy adult range, 1.3-24.8 mmol/l). The levels of sodium, calcium, urea, creatinine, uric acid, total protein, albumin, cholinesterase, prealbumin and creatine kinase were slightly lower, but erythrocyte sedimentation rate, N-terminal pro-brain natriuretic peptide, activated partial thromboplastin time, fibrinogen, D-Dimer and fibrin (fibrinogen) degradation product were slightly higher (Table I). The red blood cell count and hemoglobin levels both decreased immediately after surgery and gradually increased from day 3 after surgery. It is noteworthy that postoperative myoglobin levels increased to 2066.00 ng/ml (healthy adult range, 28.00-72.00 ng/ml). However, D-Dimer levels decreased gradually after operation. The changes in laboratory tests and clinical parameters during the hospital stay are shown in Table II. Upon arrival at The Affiliated Hospital of Guizhou Medical University, a contrast-enhanced CT revealed compression and thinning of the right pulmonary artery, incomplete expansion of the right lung, moderate hemorrhaging in the right thorax and slight enlargement of multiple mediastinal lymph nodes (Fig. 1). Based on the assessment of the patient, it appeared that the tumor was malignant and had potentially infiltrated the pericardium, pleura or right atrium. Emergency surgery was performed to address a hemothorax caused by a ruptured tumor. Through surgery, it was observed that the tumor was located in the right anterior superior mediastinum, measuring  $\sim 17.0 \times 15.0 \times 6.0$  cm, had a brittle and inactive texture, easily bleeding upon touch, lacked an integrated envelope. In addition, the tumor extended downwards

along the mediastinum, invading the right pericardium, middle and lower lobe of the right lung, phrenic nerve and reaching the anterior border of the spine. The entire lesion and invaded tissue were removed during surgery. Tissues were stained with hematoxylin and eosin for 3 min at 65°C, and images were captured under a LEICA DM3000 LED fluorescence microscope (Leica Microsystems, Inc.). The results revealed that the lesion was a mixed germ cell tumor consisting of four cell types: embryonal carcinoma, seminoma, yolk sac tumor and immature teratoma (Fig. 2). However, the parents of the patient declined immunohistochemistry. Based on these pathological features, the pathologist diagnosed the tumor as mixed germ cell tumor, with  $\sim 85\%$  yolk sac tumor,  $\sim 10\%$  immature teratoma,  $\sim 3\%$  seminoma and  $\sim 2\%$  embryonal carcinoma. No tumor metastasis was observed in the fibrofatty tissue of the pleural wall or in the group 11 lymph nodes. However, tumor involvement was detected in the tissue of the middle and lower lung lobes of the right lung, indicating metastasis of the tumor (Fig. 2I and J). The postoperative  $\alpha$ -fetoprotein (AFP) level was 1210.00 ng/ml (normal range, 0-7 ng/ml), and the  $\beta$ -human chorionic gonadotropin level was 3.54 mIU/ml (healthy male range,  $\leq 2$  mIU/ml). Although these tests were not conducted before surgery, results are consistent with a diagnosis of a germ cell tumor. The patient's respiratory distress gradually improved after surgery, but both red blood cell count and hemoglobin level markedly dropped on day 10 postoperatively, and a repeat chest radiograph indicated a notable recovery of the chest cavity (Fig. 3). A positron emission tomography (PET)/CT scan on day 12 postoperatively revealed the presence of multiple skeletal metastases throughout the body. The affected lung tissue had already been removed during surgery, and therefore PET/CT did not reveal obvious signs of lung metastasis (Fig. 4). Despite recommendations for chemotherapy, the patient opted for discharge on day 17 after surgery. As noted during the follow-up period, the patient passed away 2 months after discharge in May 2021.

## Discussion

The patient of the current report had a tumor comprising multiple types of germ cells. Spontaneous rupture of mediastinal mixed germ cell tumors is a rare occurrence and may not be well recognized by clinicians, and it can lead to hemorrhage and potentially life-threatening complications. To the best of our knowledge, there have been no reported cases of spontaneous rupture and bleeding from a mixed germ cell tumor consisting of four cell types. In the US, the overall incidence range of extragonadal germ cell tumors between 1973 and 2007 was 1.8-3.4 cases per 1 million individuals, with a lower incidence rate reported in females (4). According to a study by the Finnish National Cancer Registry, during the period 1969-2008, the incidence rate of extragonadal mixed germ cell tumor was  $\sim 0.18$  and  $\sim 0.10$  per 1 million in men and women, respectively (5). While germ cell tumors are most commonly seen in gonads, some can occur outside those. Mixed germ cell tumors usually occur in the midline and can be found anywhere from the head to the sacrum. The most common location for mixed germ cell tumors is the anterior mediastinum (50-70% of cases) (1-4). However, due to the rarity of ruptured mixed germ cell tumors in the

Table I. Laboratory examination after admission hospital test results.

Indices	Value	Variation	Normal range
RBCs per liter	3.83	Down	(3.5-5.5)x10 <sup>12</sup>
Hemoglobin, g/l	116	Down	130-175
Platelets per liter	523	Up	(125-300)x10 <sup>12</sup>
LYM%	12.1	Down	20-50
MON%	17.1	Up	3-10
SBC, mmol/l	27	Up	21.3-24.8
ABC, mmol/l	3.8	Up	-3-3
Sodium, mmol/l	134.7	Down	137-147
Calcium, mmol/l	2.075	Down	2.11-2.52
Urea, mmol/l	2.33	Down	3.1-8.0
Creatinine, μmol/l	49.62	Down	57-97
Uric acid, μmol/l	90.5	Down	208-428
Total protein, g/l	56.45	Down	65-85
Albumin, g/l	29.1	Down	40-55
Cholinesterase, U/l	3793	Down	5,000-12,000
Prealbumin, mg/l	90	Down	200-400
CK, U/l	29.62	Down	50-310
ESR, mm/h	120	Up	0-21
NT-proBNP, pg/ml	127.9	Up	20.00-88.00
APTT, sec	49	Up	28-44
Fibrinogen, g/l	6.08	Up	2-4
D-Dimer, μg/ml	7.81	Up	0-1
FDP, μg/ml	26.55	Up	0-5

RBCs, red blood cells; LYM%, percentage of lymphocytes; MON%, percentage of monocytes; SBC, standard bicarbonate radical; ABC, actual bicarbonate radical; CK, creatine kinase; ESR, erythrocyte sedimentation rate; NT-proBNP, N-terminal pro-brain natriuretic peptide; APTT, activated partial thromboplastin time; FDP, fibrin (fibrinogen) degradation product.

mediastinum, the rate of hemorrhage associated with them remains unknown. Teratoma and pure seminoma are the most common histological subtypes of mediastinal mixed germ cell tumors (3). The exact cause of mixed germ cell tumors has not yet been confirmed. Previous studies suggested that the tumor originated from germ cell precursors that were mistakenly stagnant during midline migration in embryogenesis (3). Genetic studies have shown that aneuploidy and chromosome 12 abnormalities are the most common genetic aberrations observed in post-puberty germ cell tumors (6-8). Mediastinal mixed germ cell tumors are considered to arise from germ cells that remain in the anterior mediastinum. This category encompasses various types of mature teratomas, yolk sac tumors, immature teratomas, embryonal carcinomas, choriocarcinomas and mixed germ cell tumors (1). The exact cause of spontaneous rupture in mixed germ cell tumors is still debated, but it is hypothesized to be associated with multiple factors such as autolysis, infection, inflammation, crush necrosis and ischemia (9). Additionally, it has been suggested that the rapid development of choriocarcinoma within a mixed mediastinal germ cell tumor may be a contributing factor to tumor rupture and hemorrhage (1). Furthermore, chemotherapy might also play a role in precipitating tumor rupture (10). However, in the present case, the patient's tumor did not contain choriocarcinoma components,

and no chemotherapy was administered prior to the rupture. Although the presence of an immature teratoma in the patient of the current report does not exclude the possibility of autolysis as an explanation for the ruptured bleeding, it is noteworthy that Ruan *et al* suggested that the presence of a large choriocarcinoma component in mediastinal mixed germ cell tumors is the most likely cause of tumor rupture (1). However, the patient of the current report was not diagnosed with choriocarcinoma.

In terms of histology, mixed germ cell tumors share the same subtypes as gonadal germ cell tumors, which include seminoma and non-seminoma. Seminoma is limited to classic seminoma, while non-seminoma includes embryonic carcinoma, teratoma (mature or immature), yolk sac carcinoma, choriocarcinoma and mixed germ cell tumor (8). Among these, mature teratomas are benign tumors with a good prognosis, while the other tumors are malignant and have a poor prognosis (8). The clinical manifestations of mediastinal tumors can vary, ranging from no symptoms to severe cardiorespiratory problems. These tumors can cause symptoms by compressing the airways, causing superior vena cava syndrome, invading the mediastinum directly, obstructing pulmonary blood vessels, causing pericardial effusion, triggering paraneoplastic syndrome and compressing the recurrent laryngeal nerve (5). Bokemeyer *et al* (11) showed that the most common symptoms

Table II. Changes of clinical indices of the patient of the present case report.

Clinical index	Pre-surgery		Post-surgery					Normal range
	Admission to hospital	Day 1	Immediately after operation	Day 1	Day 3	Day 7	Day of discharge	
Daily chest drainage, ml	50	50	N/A	10	250	150	N/A	N/A
Blood pressure, mmHg	109/68	103/64	N/A	117/74	104/64	77/55	N/A	90-139/60-89
Heart rate, beats per min	95	105	N/A	103	102	78	N/A	60-100
White blood cells per liter	9.14	11.38	12.67	12.48	9.55	8.64	8.03	3.5-9.5x10 <sup>9</sup>
Red blood cells per liter	3.83	3.92	3.21	2.37	2.88	2.86	3.32	3.8-5.1x10 <sup>12</sup>
Hemoglobin, g/l	116.00	119.20	98.00	71.00	85.00	89.00	95.00	130-175
Platelets per liter	532.00	508.00	290.00	305.00	482.00	539.00	484.00	(100-300)x10 <sup>9</sup>
Calcium, mmol/l	2.075	N/A	1.885	1.985	2.13	N/A	N/A	2.11-2.52
Albumin, g/l	29.10	N/A	21.80	30.10	37.50	N/A	N/A	40-55
Myoglobin, ng/ml	21.00	N/A	2066.00	N/A	N/A	N/A	N/A	28.00-72.00
hs-CTnT, ng/ml	0.006	N/A	0.04	N/A	N/A	N/A	N/A	0.000-0.014
AFP, ng/ml	N/A	N/A	N/A	N/A	N/A	1210.00	N/A	0.00-7.00
β-hCG, mIU/ml	N/A	N/A	N/A	N/A	N/A	3.54	N/A	healthy males, ≤2
D-dimer, μg/ml	7.81	N/A	6.52	2.23	N/A	N/A	N/A	0-1

hs-CTnT, troponin; AFP, α fetal protein; β-hCG, β-human chorionic gonadotropin; N/A, not applicable.

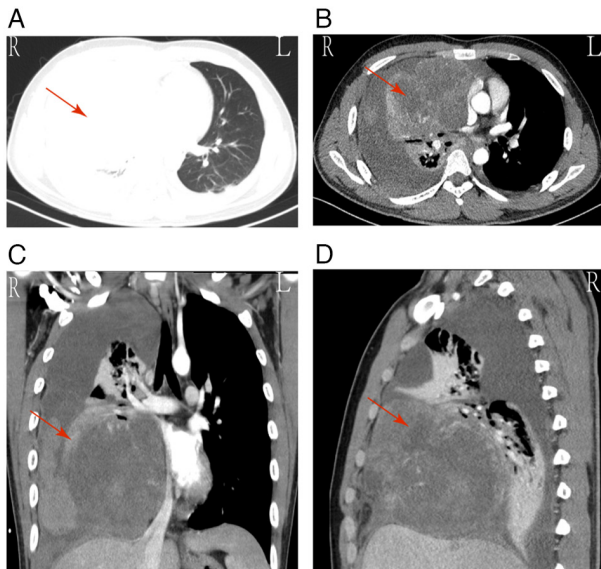


Figure 1. Results of chest CT examination. (A) Axial, (B) sagittal and (C and D) coronal scans of the CT scan of the chest. The red arrow indicates the location of the tumor. According to the results, the tumor was considered to be malignant and might have invaded the pericardium, pleura and right atrium. R, right; L, left; CT, computed tomography.

of mediastinal tumors are dyspnea (25%), chest pain (23%), cough (17%) and fever (13%).

The diagnosis of mixed germ cell tumors is often challenging and is typically diagnosed incidentally when the tumor compresses adjacent organs, leading to corresponding symptoms. It is commonly detected during routine diagnosis or treatment, typically at a late stage. However, a correct and early diagnosis can improve prognosis. Imaging plays a critical

role in the diagnosis and staging of thymoma, as well as in the follow-up monitoring of patients with this tumor. Mediastinal lesions are typically first diagnosed using chest X-ray, CT or echocardiography (12). The CT imaging of the patient presented in the current report revealed a tumor in the right mediastinum with intratumoral hemorrhage, measuring ~17.0x15.0 cm in diameter. The right pulmonary artery was compressed and attenuated, the right lung was not fully expanded, there was moderate hemorrhaging in the right thoracic cavity and multiple mediastinal lymph nodes were mildly enlarged. The actual size of the tumor post-surgery is shown in Fig. 2A. Due to the emergent nature of the intraoperative circumstances, cross-sectional images of the tumor after excision were not captured. This limitation may impede a more comprehensive understanding of the internal structure and nature of the tumor. Most mediastinal cystic tumors are initially identified in ultrasonographic examinations as either unilocular (57.7%) or multilocular (15.4%) cysts. The cystic fluid displayed mixed echogenicity (81.1%), with acoustic shadowing observed in 72.2% of cases. Vascular formation was minimal or absent on color Doppler imaging, as indicated by color scores of 52.9% and color scoring of 27.1%; additionally, these tumors may exhibit features such as ‘cotton wool tufts’, ‘mushroom cap sign’, ‘completely hyperechogenic lesion’ and ‘starry sky sign’ (13). Ultrasound examination was not performed upon admission. Magnetic resonance imaging (MRI) is considered superior for examining soft tissue as it provides a better characterization of lesions and their internal tissue features. Additionally, MRI can identify the invasion of adjacent structures, making it a useful tool for evaluating mediastinal masses. MRI can help distinguish uncertain lesions that are not clearly visible on CT and X-ray images (12-14). Thymomas typically appear as low signal intensity on T1-weighted images and high signal

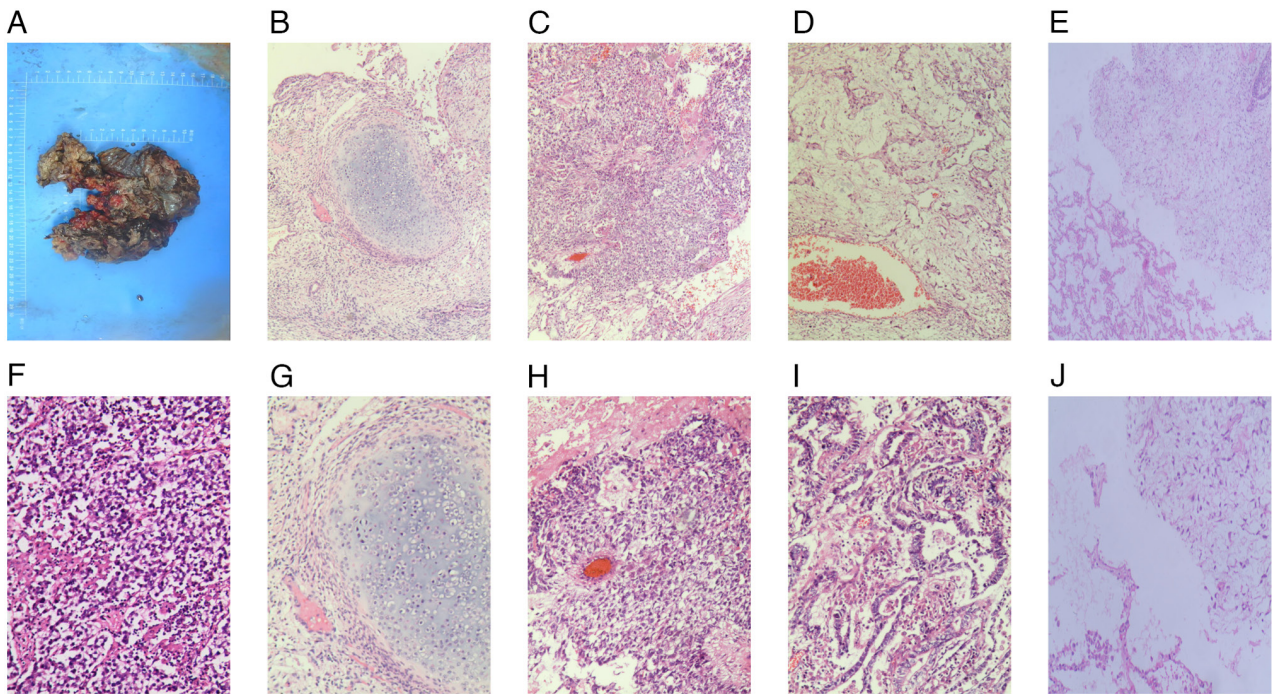


Figure 2. The results of hematoxylin and eosin staining. (A) Gross specimen of the tumor. (B-E) Pathological images of H&E staining with magnification, x40. (F-J) Pathological images of H&E staining with magnification, x100. (B and G) Immature chondrocyte component in teratoma. (C and H) Embryonal carcinomas with great heterogeneity. (D and I) Yolk sac tumor component (~85-90% of the tumor). (E and J) Involvement of lung tissue. (F) Spermatogonia in tumors.

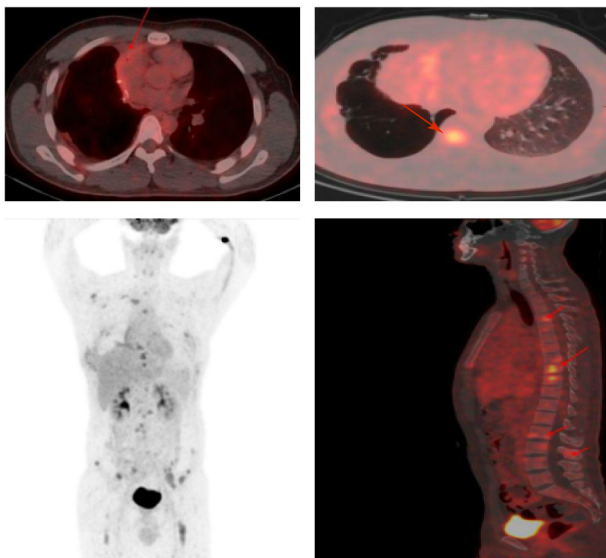


Figure 3. The PET/CT examination revealed a metabolic increase in the surgical area following mediastinal tumor surgery likely due to inflammation or tumor invasion. Red arrows indicate multiple areas of increased bone metabolism throughout the body, suggesting the possibility of distant metastasis. PET/CT, positron emission tomography/computed tomography.

intensity on T2-weighted images (14). Mediastinal tumors exhibit increased metabolic activity on PET-CT scans, which not only serve to determine the nature of the tumor (benign or malignant), but can also be used to assess the patient's response to treatment (14,15). Mixed germ cell tumors exhibit similar serological, histological and cytogenetic characteristics as gonadal germ cell tumors (14). Biochemical serum

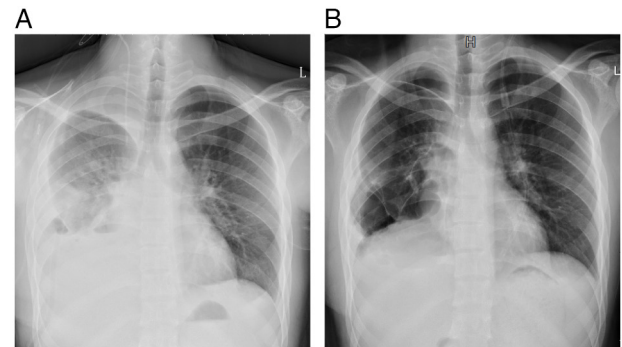


Figure 4. Results of the chest radiographs on day (A) 2 and (B) 10 after surgery showed a better recovery of the chest cavity. R, right; L, left.

tumor markers, such as AFP,  $\beta$ -human chorionic gonadotropin ( $\beta$ -hCG) and lactate dehydrogenase are often found to be elevated in mixed germ cell tumors (13). AFP levels are typically increased in non-myxomatous mixed germ cell tumors, but not in patients with pure seminoma. Conversely, serum AFP levels are raised in patients with pure yolk sac tumors or mixed germ cell tumors containing yolk sac tumors. Serum  $\beta$ -hCG levels may also be increased in advanced disease, regardless of whether it is a pure or non-serous germ cell tumor. Additionally, the presence of multinucleated trophoblast-like giant cells in seminiferous microcytomas is associated with  $\beta$ -hCG production (8). Although AFP and  $\beta$ -hCG levels were not available for the patient of the current report upon admission, postoperative examination revealed elevated levels of both markers. Zhou *et al* (16) discovered that terminal deoxynucleotidyl transferase can serve as a novel tumor marker for

diagnosing seminoma, germ cell tumor *in situ*, anaplastic cell tumor, embryonal carcinoma and mixed germ cell tumor with a markedly high positive rate. Furthermore, research has demonstrated that plasma levels of microRNA-371a-3p can be used as an indicator for prognostic assessment of germ cell tumors (17). However, the histopathological examination remains crucial for the definitive diagnosis of primary mediastinal mixed germ cell tumors. Preoperative cytology through percutaneous fine needle biopsy has emerged as a prevalent approach for diagnosing mediastinal masses. However, there are instances where the sample obtained from the core needle biopsy is insufficient for conducting immunohistochemical experiments (15). Furthermore, Sakane *et al* (18) reported a case of mediastinal mixed germ cell tumor with diffuse lung metastasis resulting from biopsy, indicating that there is a risk of tumor metastasis associated with this procedure.

In the past, the standard treatment for extragonadal germ cell tumors involved complete surgical tumor resection. However, as surgical resection alone yielded poor prognosis, chemotherapy based on cisplatin was introduced notably improving patient's overall survival rates (19,20). Nonetheless, in some patients with mixed germ cell tumor, a residual mass may still be present after cisplatin chemotherapy and conventional marginal chemotherapy (21). As a result, the current standard of care for mixed malignant germ cell tumors involves a multidimensional approach. This includes preoperative combination chemotherapy followed by aggressive surgical excision of the residual lesion (22). In patients with mediastinal mixed germ cell tumor, the potential risk of spontaneous rupture which can result in severe complications should be considered. When patients with mediastinal mixed germ cell tumor experience life-threatening bleeding, conservative therapies like blood transfusion and volume resuscitation are ineffective, and prompt surgical removal of the mass and hemostatic interventions are required (1). The prognosis of extragonadal germ cell tumors is closely related to the anatomic location and histological type of the tumor (8). In adult patients with extragonadal germ cell tumors, the primary location in the mediastinum and the histological type are additional independent prognostic factors that are associated with shorter survival (8). Mixed germ cell tumors that arise in the mediastinum often have a poor prognosis due to the tumor directly invading vital organs in that area. The tissue type is the most important prognostic factor for adult extragonadal germ cell tumors, with seminomas and non-seminomatous carcinomas having long-term survival rates of ~90 and ~45%, respectively (8). Overall, germ cell tumors occurring in the mediastinum have a poorer prognosis. Hu *et al* (3) reported an average survival time of only 3 months in 10 patients with mixed mediastinal germ cell tumors. Ruan *et al* (1) documented a case involving a patient with a mediastinal mixed germ cell tumor that spontaneously ruptured, leading to hemorrhage. This rare clinical scenario manifested as bilateral massive hemothorax and hypovolemic shock. To manage the severe bleeding, emergency surgical excision of the tumor was completed. Pathological examination revealed the tumor to be a combination of choriocarcinoma and immature teratoma, with concurrent pulmonary metastasis of choriocarcinoma cells. The patient exhibited a favorable recovery postoperatively

and received adjuvant salvage chemotherapy. After a total of 2 years following the diagnosis, the patient continued to show remission with no evidence of disease recurrence.

It is noteworthy that surgery carries certain risks and may potentially accelerate tumor metastasis. The PET/CT examination results of the patient of the present case report 10 days after surgery indicated the possibility of bone metastasis. However, it is unclear whether the metastasis occurred before the surgery. Filho *et al* (23) reported a case of a male patient with metastatic testicular cancer presenting with spontaneous retroperitoneal hemorrhage, who, after stabilization with conservative treatment, responded well to chemotherapy. Given the stable vital signs, red blood cell count and hemoglobin levels of the patient of the present case report upon admission, and considering the uncertainties in tumor staging, it was hypothesized that initial conservative treatment was more appropriate. After stabilizing hemodynamics, chemotherapy could have been administered, and the timing for surgery would be reconsidered if the tumor shrunk post-chemotherapy, potentially offering the best treatment outcome for the patient. Therefore, not all mixed germ cell tumors are suitable for emergency surgery. For patients with spontaneous rupture of mediastinal germ cell tumors, careful evaluation of the patient's vital signs and approximate tumor staging is needed before considering surgical treatment. We aim to improve the prognosis of patients with this disease by sharing the present case report.

#### Acknowledgements

Not applicable.

#### Funding

No funding was received.

#### Availability of data and materials

The data generated in the present study may be requested from the corresponding author.

#### Authors' contributions

JL and XSL guided the conception and design of the study. XSL, SHX, YPT, KYW, YML and JM collected clinical data and figures. XSL was responsible for writing the draft. XSL, JL and SHX revised the manuscript. YBL conducted the second round of image acquisition and modifications. JL, XSL, SHX, YPT, YKW, YML and JM confirm the authenticity of all the raw data. All authors have read and approved the final version of the manuscript.

#### Ethics approval and consent to participate

Not applicable.

#### Patient consent for publication

The patient's next of kin (father) provided signed informed consent for the publication of the patient's data and images after the patient succumbed to the disease.

## Competing interests

The authors declare that they have no competing interests.

## References

- Ruan Z, Wang S, Wang Z and Jing Y: A rare case of bilateral massive hemothorax from spontaneous rupture of a primary mediastinal mixed germ cell tumor. *Ann Thorac Surg* 93: 664-666, 2012.
- Shaher A, Salameh M and Raslan A: Mediastinal mixed germ cell tumor with purulent pericarditis and empyema caused by *Escherichia coli*: A rare case report. *J Cardiol Cases* 26: 239-241, 2022.
- Hu X, Li D, Xia J, Wang P and Cai J: Mediastinal mixed germ cell tumor: A case report and literature review. *Open Med (Wars)* 16: 892-898, 2021.
- Stang A, Trabert B, Wentzensen N, Cook MB, Rusner C, Oosterhuis JW and McGlynn KA: Gonadal and extragonadal germ cell tumors in the United States, 1973-2007. *Int J Androl* 35: 616-625, 2012.
- Pauniah SL, Salonen J, Helminen M, Vettenranta K, Heikinheimo M and Heikinheimo O: The incidences of malignant gonadal and extragonadal germ cell tumors in males and females: A population-based study covering over 40 years in Finland. *Cancer Causes Control* 23: 1921-1927, 2012.
- Cheng L, Zhang S, MacLennan GT, Poulos CK, Sung MT, Beck SD and Foster RS: Interphase fluorescence in situ hybridization analysis of chromosome 12p abnormalities is useful for distinguishing epidermoid cysts of the testis from pure mature teratoma. *Clin Cancer Res* 12: 5668-5672, 2006.
- Sung MT, MacLennan GT, Lopez-Beltran A, Zhang S, Montironi R and Cheng L: Primary mediastinal seminoma: A comprehensive assessment integrated with histology, immunohistochemistry, and fluorescence in situ hybridization for chromosome 12p abnormalities in 23 cases. *Am J Surg Pathol* 32: 146-155, 2008.
- Ronchi A, Cozzolino I, Montella M, Panarese I, Zito Marino F, Rossetti S, Chieffi P, Accardo M, Facchini G and Franco R: Extragonadal germ cell tumors: Not just a matter of location. A review about clinical, molecular and pathological features. *Cancer Med* 8: 6832-6840, 2019.
- Sasaka K, Kurihara Y, Nakajima Y, Seto Y, Endo I, Ishikawa T and Takagi M: Spontaneous rupture: A complication of benign mature teratomas of the mediastinum. *AJR Am J Roentgenol* 170: 323-328, 1998.
- Lemańska A, Banach P, Stanisławska K, Juskat R, Spaczyński M and Nowak-Markwitz E: Urgent embolization of hemorrhagic choriocarcinoma liver metastases-case report and review of the literature. *Ginekol Pol* 86: 957-961, 2015.
- Bokemeyer C, Nichols CR, Droz JP, Schmoll HJ, Horwich A, Gerl A, Fossa SD, Beyer J, Pont J, Kanz L, *et al*: Extragonadal germ cell tumors of the mediastinum and retroperitoneum: Results from an international analysis. *J Clin Oncol* 20: 1864-1873, 2002.
- Chaturvedi A, Gange C, Sahin H and Chaturvedi A: Incremental value of magnetic resonance imaging in further characterizing hypodense mediastinal and paracardiac lesions identified on computed tomography. *J Clin Imaging Sci* 8: 10, 2018.
- Heremans R, Valentin L, Sladkevicius P, Timmerman S, Moro F, Van Holsbeke C, Epstein E, Testa AC, Timmerman D and Froyman W: Imaging in gynecological disease (24): Clinical and ultrasound characteristics of ovarian mature cystic teratomas. *Ultrasound Obstet Gynecol* 60: 549-558, 2022.
- Park JW, Jeong WG, Lee JE, Lee HJ, Ki SY, Lee BC, Kim HO, Kim SK, Heo SH, Lim HS, *et al*: Pictorial review of mediastinal masses with an emphasis on magnetic resonance imaging. *Korean J Radiol* 22: 139-154, 2021.
- Marom EM: Advances in thymoma imaging. *J Thorac Imaging* 28: 69-80, 2013.
- Zhou J, Wang S, Zhu L, Zhou L, Zeng H, Gan Y and Wang C: Terminal deoxynucleotidyl transferase commonly expresses in germ cell tumors: Evaluation on a large series from multiple centers. *Int J Gen Med* 14: 119-129, 2021.
- Mego M, van Agthoven T, Gronosova P, Chovanec M, Miskovska V, Mardiak J and Looijenga LHJ: Clinical utility of plasma miR-371a-3p in germ cell tumors. *J Cell Mol Med* 23: 1128-1136, 2019.
- Sakane T, Okuda K, Murase T, Watanabe T, Oda R, Tatematsu T, Yokota K, Haneda H, Inagaki H and Nakanishi R: Mixed-type primary germ cell tumor of the mediastinum in a young adult male with a sudden life threatening condition: A case report. *Thorac Cancer* 11: 166-169, 2020.
- Dulmet EM, Macchiarini P, Suc B and Verley JM: Germ cell tumors of the mediastinum. A 30-year experience. *Cancer* 72: 1894-1901, 1993.
- Nichols CR: Mediastinal germ cell tumors. Clinical features and biologic correlates. *Chest* 99: 472-479, 1991.
- Reuter VE: The pre and post chemotherapy pathologic spectrum of germ cell tumors. *Chest Surg Clin N Am* 12: 673-694, 2002.
- Liu Y, Wang Z, Peng ZM and Yu Y: Management of the primary malignant mediastinal germ cell tumors: Experience with 54 patients. *Diagn Pathol* 9: 33, 2014.
- Filho LHCP, Silva TA, Beal PR, Buonfiglio VB and Sadi MV: Spontaneous rupture of a retroperitoneal lymph node metastasis causing massive hemorrhage in a patient with advanced mixed germ cell tumor. *Urol Case Rep* 45: 102180, 2022.



Copyright © 2024 Li et al. This work is licensed under a Creative Commons Attribution-NonCommercial-NoDerivatives 4.0 International (CC BY-NC-ND 4.0) License.