

Oncolytic virotherapy stimulates anti-tumor immune response and demonstrates activity in advanced sarcoma: Report of two cases

YETING QIU^{1*}, AIJUN QIN^{1*}, RONGHUA ZHAO¹⁻³, JUN DING^{1,2}, WILLIAM WEI-GUO JIA¹⁻³,
MANU SINGH², YANAL MURAD², QIAN TAN¹ and GANESSAN KICHENADASSE⁴

¹Shanghai Virogin Biotech Ltd., Shanghai 200240, P.R. China; ²Virogin Biotech Canada Ltd., Richmond, BC V6V 3A4, Canada; ³China National Biotech Group (CNBG) - Virogin Biotech (Shanghai) Co., Ltd., Shanghai 200240, P.R. China; ⁴Department of Medical Oncology, Southern Oncology Clinical Research Unit, Flinders Private Hospital, Adelaide, South Australia 5042, Australia

Received October 18, 2023; Accepted February 27, 2024

DOI: 10.3892/ol.2024.14377

Abstract. Sarcoma is derived from mesenchymal neoplasms and has numerous subtypes, accounting for 1% of all adult malignancies and 15% of childhood malignancies. The prognosis of metastatic or recurrent sarcoma remains poor. The current study presents two cases of sarcoma enrolled in a phase I dose escalation trial for solid tumor, who had previously failed all standard therapies. These patients were treated with VG161, an immune-stimulating herpes simplex virus type 1 oncolytic virus with payloads of IL-12, IL-15 and IL-15 receptor α unit, and a programmed cell death 1 (PD-1)/PD-1 ligand 1 blocking peptide. Both cases demonstrated stable disease as the best response, accompanied by a noteworthy prolongation of progression-free survival (11.8 months for chondrosarcoma and 11.9 months for soft tissue sarcoma, respectively) at a dose of 2.5×10^8 PFU/cycle. In addition, the treatment led to the activation of anti-cancer immunity, as evident from cytokine, lymphocyte subset and related pathway analyses of peripheral blood and/or tumor biopsy samples. These promising results suggest that VG161 monotherapy holds promise as an effective treatment for sarcoma and warrants further investigation through clinical trials. The two reported patients were part of a phase I clinical trial conducted and registered on the Australian New Zealand Clinical Trials

Registry in Australia (registration no. ACTRN12620000244909; registration date, 26 February, 2020).

Introduction

Sarcomas are rare malignancies of mesenchymal cell origin that display a heterogenous mix of clinical and pathologic characteristics (1). They can be classified into two main types: Soft tissue sarcoma (STS) and bone sarcoma. Primary bone tumors and STS account for ~1% of adult malignant tumors (1), and the most common primary malignant bone tumors are osteosarcoma, chondrosarcoma and Ewing sarcoma, while STS have complex pathological types, the most common being leiomyosarcoma and liposarcoma. Surgery with or without neoadjuvant chemoradiation is recommended for patients with resectable lesions. However, ~50% of patients with sarcoma develop metastases after surgery and the post-operative recurrence rate is reported to be 10-20% (2). For these metastatic or recurrent patients, anthracycline-based regimens are first-line therapies, such as doxorubicin and epirubicin, which have limited efficacy (1). While patients with NTRK gene fusion-positive status can be treated with larotrectinib and entrectinib (1), these cases constitute <5% of patients with non-gastrointestinal stromal tumor soft-tissue sarcoma (3). As of now, there are no approved immune therapies for treating most subtypes of sarcoma except for alveolar soft part sarcoma, due to the severe immune suppressive tumor microenvironment (4).

Oncolytic virus is either wild-type or genetically modified virus selectively replicating in tumor cells and thereby lysing the cells and leading to tumor antigen release (5,6). In addition, they can stimulate anti-cancer immunity by infecting tumor cells and expressing exogenous immune-stimulating factors carried by the virus (5,6). Therefore, oncolytic virotherapy can be considered for anti-cancer immune therapy. VG161 is a genetically modified herpes simplex virus type 1 (HSV-1) oncolytic virus. The neurovirulence of wild-type HSV-1 is removed by deletion of ICP34.5 (two copies) in the wild-type backbone. It carries IL-12, IL-15/IL-15 with its receptor α unit (IL-15RA) and programmed cell death 1 ligand 1 (PD-L1) blocking peptide, which synergistically stimulate innate

Correspondence to: Dr Qian Tan, Shanghai Virogin Biotech Ltd., Room 4608, Block A, Zhongyi Building, 580 Nanjing West Road, Jing'an, Shanghai 200240, P.R. China
E-mail: susie.tan@virogin.com

Dr Ganessan Kichenadasse, Department of Medical Oncology, Southern Oncology Clinical Research Unit, Flinders Private Hospital, Unit, Level 3, Mark Oliphant Building, 5 Laffer Drive, Adelaide, South Australia 5042, Australia
E-mail: ganessan.kichenadasse@flinders.edu.au

*Contributed equally

Key words: sarcoma, oncolytic virus, herpes simplex virus, intratumoral injection, anti-tumor immune responses

and adaptive anti-tumor immunity (7,8). In tumor-bearing immune-competent mice, VG161 has demonstrated systemic anti-cancer activity and shown to induce anti-cancer immune memory in a rechallenge mouse model (7,8). VG161 has now entered the stage of clinical development; current data indicate its safety and potential clinical efficacy in certain cancers. In the present study, two cases of sarcoma are reported who were enrolled in a phase I dose escalation trial for patients with solid tumor who had failed to respond to all standard therapies and treated with VG161 monotherapy.

Materials and methods

Virus DNA detection and quantification. VG161 virus DNA was quantified as described previously (7). In brief, DNA was isolated using the DNeasy Blood and Tissue Kit (Qiagen Sciences, Inc.) and VG161 virus copies were measured by quantitative PCR using primers and a probe specific to the codon optimized IL-15RA1 payload of VG161. The primers used were as follows: Forward, 5'-CTCTCCAAGCTCCAA CAATACA-3' and reverse, 5'-GAGGACTCGTGGCTAGAG AT-3'; and probe, 5'-CAGCAACCACAGCAGCAATCGTG-3' (Integrated DNA Technologies).

Cytokine level detection. Cytokine levels were measured using the Meso Scale Discovery (MSD) platform [V-PLEX Plus Proinflammatory Panel 1 Human Kit (MSD) and the V-PLEX Plus Human IL-15 Kit (MSD)] based on the manufacturers' instructions. In brief, plates precoated with capture antibodies on predefined spots were incubated with serum samples prediluted two-fold in assay diluent for 2 h. Detection antibodies conjugated with electro-chemiluminescent labels (MSD GOLD™ SULPHO TAG) were applied to the analytes to complete the sandwich immunoassay. An MSD electrochemiluminescence detection instrument was used for reading the V-Plex plate and V-PLEX (Multiplex) data acquisition and analysis were performed using MSD Discovery Workbench® 4.0 software (MSD).

Flow cytometric detection. A flow cytometry assay was performed on peripheral blood mononuclear cells (PBMCs) (9) isolated from patients by Ficoll Paque (Milipore-Sigma) using an Attune NxT Flow Cytometer (Thermo Fisher Scientific, Inc). Anti-CD3 FITC (cat. no. 11-0038-41), CD56 PE (cat. no. 12-0567-41; Invitrogen; Thermo Fisher Scientific, Inc.) and anti-CD8 BV605 (cat. no. 564115; BD Biosciences) antibodies were used to quantify natural killer (NK) cells (CD3⁺CD56⁺) and CD8⁺ cells (CD3⁺CD8⁺) in peripheral blood. All antibodies were diluted 1:40 before use.

RNA-sequencing (seq) detection and analysis. Total RNA from the biopsy samples was isolated using the RNeasy Plus Isolation Kit (Qiagen Sciences, Inc.), and was used to generate PCR-free cDNA Nanopore sequencing libraries (cat. no. SQK-DCS109; Oxford Nanopore) following the manufacturer's protocol and sequenced in PromethION R9 flow cells (Oxford Nanopore). Data were analyzed using in-house bash scripts, including automated bash scripts running Guppy basecaller v5 (<https://genomebiology.biomedcentral.com/articles/10.1186/s13059-019-1727-y>), FastQC v0.11.9 ([https://www.bioinformatics.babraham.](https://www.bioinformatics.babraham.ac.uk/projects/fastqc/)

[ac.uk/projects/fastqc/](https://www.bioinformatics.babraham.ac.uk/projects/fastqc/), minimapper2 (<https://academic.oup.com/bioinformatics/article/34/18/3094/4994778>, Samtools v1.13 (<https://academic.oup.com/gigascience/article/10/2/giab008/6137722?login=false>) and featureCounts v2.0.3 (<https://academic.oup.com/bioinformatics/article/30/7/923/232889>, and packages in R v4.3.2 (DESeq2, ComplexHeatmap, Tidyverse, ggplot2, ggpubr and clusterProfiler). RNA-seq analysis was used to calculate the immune-cell composition using single-cell reference profiles. The calculated immune cell values were relative to all the immune cells identified in a particular sample, such that the sum of the total value is equal to 1.

Results

Trial information. The two reported patients were part of a phase I clinical trial conducted and registered in Australia (ACTRN12620000244909). It was a first-in-human, open label, dose escalation study to evaluate the safety, tolerability, pharmacokinetics (PK) and biologic effect of VG161 in subjects with advanced malignant solid tumors who are refractory to conventional therapies, which was composed of two parts (Part A: Single dose with three different dose levels of 5.0x10⁷, 1.0x10⁸ and 2.0x10⁸ PFU/dose; Part B: Multiple doses with three different dose levels of 5.0x10⁷, 1.0x10⁸ and 2.0x10⁸ PFU/dose). In Part B, VG161 (Virogin) was administered as intratumoral injections by five daily injections on Days one through eight of each cycle with 28 days per cycle until intolerability or tumor progression. Eligible patients were aged ≥18 years with advanced malignant solid tumor refractory/relapsed after and/or intolerant to standard therapies or for which no standard therapy exists or is available. Patients had at least one injectable cutaneous or subcutaneous or hepatic lesions. Safety was assessed according to the Common Terminology Criteria for Adverse Events version 5.0 (10). Antitumor activity was assessed using the Response Evaluation Criteria in Solid Tumours (RECIST) version 1.1 (11) and the modified RECIST version 1.1 for immune-based therapeutics (termed iRECIST) criteria (12). For PK and viral shedding analysis, viral DNA was measured in needle biopsy samples of injected tumor, blood, urine, and swab of oral mucosa and the injection site. Changes in cytokines and lymphocyte subsets in the blood were also observed as pharmacodynamic parameters. Anti-drug antibody was tested using HSV-1 IgG ELISA commercial kits (cat. no. H1029G; Calbiotech). Biological activity was tested by RNA sequencing on needle biopsy samples collected pre- and post-injection.

Case report. The two patients reported in the present study received intratumoral injection of VG161 at 5.0x10⁷ PFU/dose by five daily injections on Days one through eight per cycle. The first case was a 68-year-old white male diagnosed with right scapular conventional chondrosarcoma with lung metastasis at an external hospital in November 2019, and received partial scapulectomy for symptom control in November 2019. Post-operative anti-cancer therapies included doxorubicin and local radiation, and the patient progressed after completing doxorubicin treatment and radiation. The patient had shoulder pain, which may have been related to the tumor and was treated with paracetamol, ibuprofen and Targin (naloxone hydrochloride; oxycodone hydrochloride). The concomitant diseases included neuropathy, gastroesophageal reflux, hypertension and Meniere's disease, which were treated with esomeprazole, pregabalin and amlodipine.

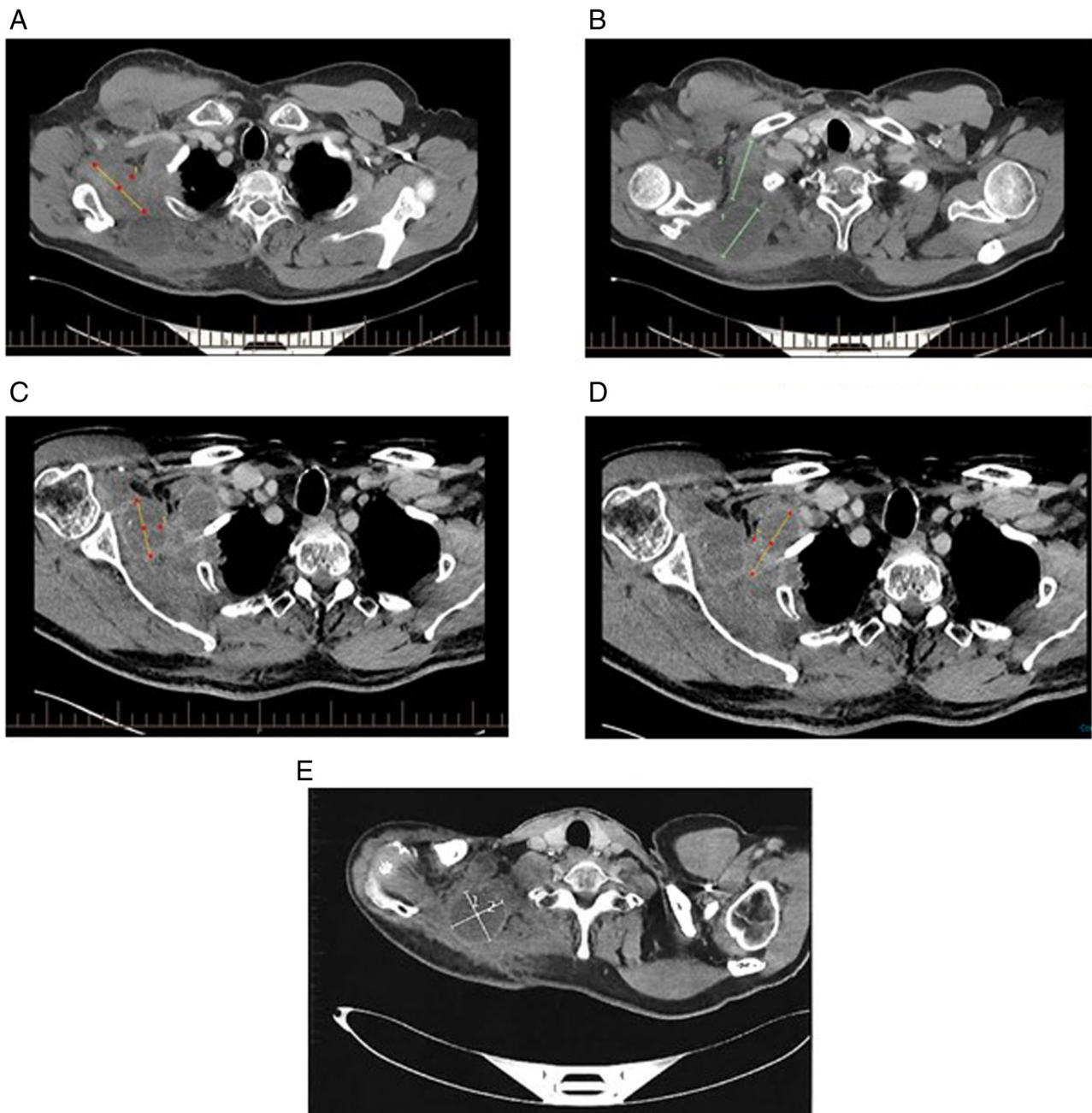


Figure 1. CT imaging of target lesions of Case 1 at baseline and after VG161 treatment. (A) CT scan of 1st target lesion at baseline. (B) CT scan of 2nd and 3rd target lesions at baseline. (C) CT scans of 1st target lesion on C5D28. (D) CT scans of 2nd target lesion on C5D28. (E) CT scans of 3rd target lesion on C5D28. CT, computed tomography.

Since October 2021, the subject (diagnosed as TxNOM1 Stage IV based on imaging examinations at screening) (13) had received intratumoral injection of VG161 for a total of 13 cycles in the Southern Oncology Clinical Research Unit (Adelaide, Australia) and the treatment was discontinued due to disease progression in October 2022. The maximum changes of the sum of the longest diameters of the target lesions were -17.96% (evaluated at Cycle 5, Day 28) from baseline and the best response was stable disease (SD). The CT scans are presented in Fig. 1. The progression-free survival (PFS) was 11.8 months and overall survival (OS) was not defined, as the patient was still alive at the data cut-off date in late June 2023 (follow-up for >20.5 months). The data are shown in Fig. 2.

For Case 1, treatment-related adverse events (TRAEs) included pyrexia (grade 2, occurred during Cycle 4, resolved after hospitalization), fatigue (grade 1, occurred during Cycle 4, resolved after ibuprofen treatment), nausea (grade 1, occurred during Cycle 2, resolved after ondansetron treatment), neck and face pain (grade 2, occurred during Cycle 2, resolved after amitriptyline treatment), injection site reaction (injection site pain, discharge and swelling, grade 1, occurred after Cycle 1, resolved after oxycodone treatment), pruritus (grade 1, occurred during Cycle 9, resolved spontaneously) and lymphocyte count decreased (grade 3, occurred during Cycle 4, resolved spontaneously). One severe adverse event (SAE), pyrexia (grade 2, occurred during Cycle 4, resolved

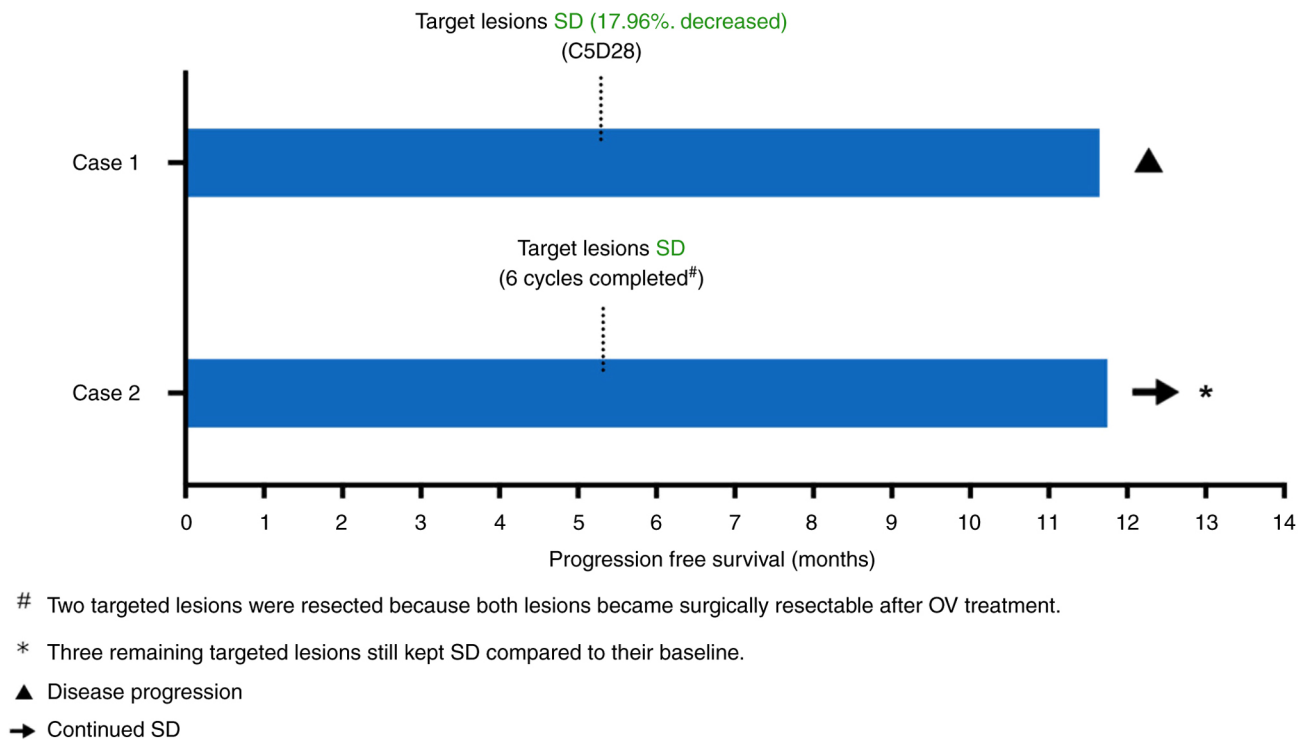


Figure 2. Swimmer plot of progression-free survival for Case 1 and 2. SD, stable disease; OV, oncolytic virus.

after hospitalization), was reported, possibly related to treatment. All of the above AEs had resolved. No TRAEs led to death or dose reduction or treatment discontinuation.

The second case was a 52-year-old white female diagnosed with STS, hemangiopericytoma, at an external hospital in August 2011 and received radical popliteal resection. Post multiple sequential anti-cancer therapies included radiotherapy, KN046 (a recombinant antibody targeting PD-L1 and cytotoxic T-lymphocyte antigen 4, doxorubicin and T3011 (HSV-1 oncolytic virus) and the disease was progressive after these treatments. The patient had pain in the thigh, cervical spine, shoulder and lower back (intermittent pain), which may have been related to the tumor. The concomitant diseases included neuropathy, hypothyroidism and trochanteric bursitis, and the patient was treated with thyroxine for hypothyroidism.

At screening, there were five target lesions observed in this subject. The five target lesions were located at the right axilla, right supraclavicular, right posterior thigh, right diaphragm and anterior mediastinal node, respectively. Since August 2022, the subject (diagnosed as TxN0M1 Stage IV based on imaging examinations at screening) (13) had received intratumoral injection of VG161 for a total of six cycles at the Southern Oncology Clinical Research Unit (Adelaide, Australia) and maintained SD until treatment discontinuation followed by surgical resection of the two injected targeted lesions located respectively at the right axilla and right supraclavicular lesions in January 2023. The above two targeted lesions were resected because both lesions became surgically resectable after oncolytic virus treatment. During the follow-up visit after surgery, except for the two resected targeted lesions, the three remaining targeted lesions still maintained SD compared to their baseline. Therefore, the best overall response of this subject was SD and the PFS was >11.9 months and OS was not defined (>11.9 months), as the

patient still kept SD at the data cut-off date in late July 2023 (11.9 months from first dosing). The data are shown in Fig. 2.

For Case 2, no TRAEs and SAEs were reported. The treatment-emergent AEs (TEAEs) included cough, nausea, headache and vomiting. These TEAEs were all grade 1 or 2 and had resolved. None of the TRAEs led to death or dose reduction or treatment discontinuation.

PK and viral shedding. Viral DNA was tested in injected lesion biopsy samples after VG161 treatment, which demonstrated VG161 entered and replicated in the injected tumor lesion. No viral DNA was detected in the serum and urine samples, and swab of oral mucosa. While viral DNA was detected at the injection site swab after injection for case 1, it turned to be negative 24 h after the last dose. No viral DNA was found in any of the injection site swabs from case 2. The above results showed that multiple intratumoral injections of VG161 have a low risk of viral spreading or shedding.

Translational findings. Levels of cytokines, including IL-12, IL-15, IL-6, IFN- γ and TNF- α were tested in the blood before and after VG161 treatment. The results showed increases in these cytokines, particularly INF- γ , after VG161 treatment, indicating activation of immune function. The data are presented in Table I. Changes in peripheral CD8⁺ and NK cells were determined by flow cytometry of PBMC samples of Case 2, and no significant changes were observed between the time-points Screening and End of treatment in Fig. 3. The data are shown in Figs. 3 and S1. The NK cells decreased slightly after the first dose of VG161 (Day 1) compared to the baseline (Screening), which may prompt the transfer of peripheral NK cells into the injected lesions. For RNA-seq analysis, bulk RNA was extracted from the biopsy samples obtained from one injected lesion at the right

Table I. Changes of cytokines (pg/ml) in peripheral blood in cycle 1 after VG161 treatment.

Cytokines	Baseline	Day 3	Day 8	Day 15	Day 28	Max fold change
	Case 1/Case 2	Case 1/Case 2	Case 1/Case 2	Case 1/Case 2	Case 1/Case 2	
IL-15	3.30/5.20	4.13/4.93	2.80/3.78	2.56/6.62	4.48/4.17	1.36/1.27
IL-6	2.89/1.13	3.46/1.56	2.22/7.91	1.78/1.39	2.51/1.00	1.20/7.00
INF- γ	9.68/8.03	46.24/15.66	9.70/6.80	4.61/167.71	9.53/4.96	4.78/20.89
TNF- α	0.84/0.54	0.89/0.71	0.89/0.63	0.92/1.13	0.86/0.57	1.10/2.09

The cytokine IL-12 was below the lower limit of quantification at all time-points, as the lower limit of the test method was higher than the IL-12 level. NA, not available.

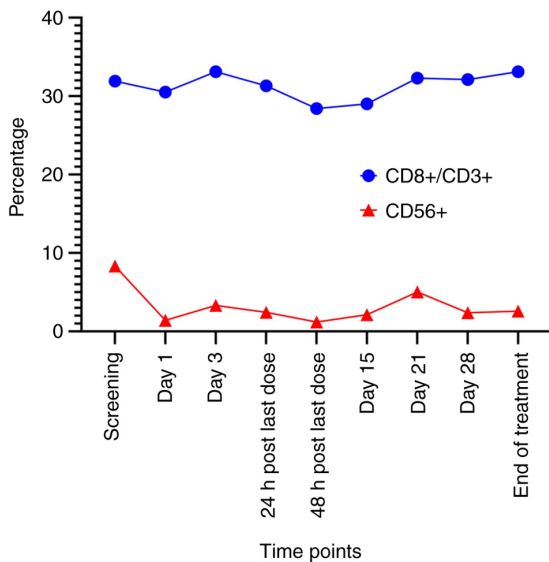


Figure 3. Changes of peripheral lymphocytes examined by flow cytometry of peripheral blood mononuclear cell samples from Case 2.

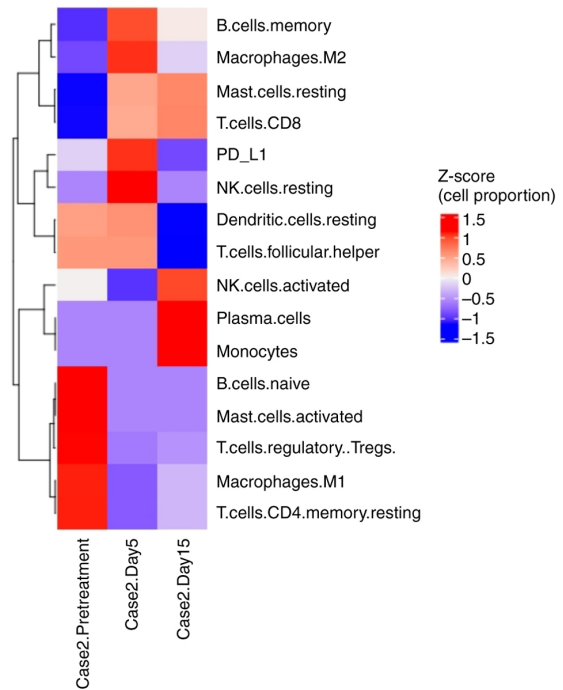


Figure 4. RNA-sequencing analysis results from biopsy sample of Case 2.

supraclavicular lesion of Case 2 pre- and post-VG161 treatment. The heatmap constructed was using the Z-score, which represents the deviation of individual sample values from the row mean for a given cell type. Changes in the tumor microenvironment before and after the VG161 treatment are displayed in Fig. 4. Although the levels of CD8⁺ cells and NK cells in PBMCs only changed marginally over the treatment course (Figs. 3 and S1), the tumor samples showed more significant changes in CD8⁺ and NK cells, and T-regulatory cells were decreased after VG161 treatment (Fig. 4). Due to a low quantity and quality of sample for Case 1, there were insufficient data to analyze, and it was not possible to present the lymphocyte cell and RNA-seq results for Case 1. Furthermore, through the RNA-seq analysis, the presence of a fusion gene ('RP11-680G10.1:GSE1' on chromosome 16 '+' strand) was found in Case 2, which has been previously reported to be associated with sarcomas (14). Due to low RNA quantity and quality, there were insufficient sequencing data from Case 1, and it was not possible to detect any gene fusion in Case 1.

Discussion

Sarcomas can be classified into two main types: STS and bone sarcoma. The systemic treatment of unresectable sarcoma

remains a clinical challenge, as the efficacy of approved standard therapies is limited. Chondrosarcoma, one subtype of sarcoma, accounts for 9.2% of all primary malignant bone tumors with an incidence of ~1/200,000. Conventional chondrosarcoma accounts for ~85% of all chondrosarcoma, including primary and secondary chondrosarcoma. Chemotherapy is commonly ineffective in chondrosarcoma, particularly for conventional chondrosarcoma, and there is currently no standard systemic treatment for conventional chondrosarcoma (15). In recent clinical trials, patients with inoperable advanced chondrosarcoma who received apatinib treatment achieved a median PFS of 4.7 months (16). In the current study, a patient with chondrosarcoma in whom chemotherapy failed but who achieved a prolonged PFS of 11.8 months was presented. Similarly, STS also poses challenges with standard therapy, as there is limited efficacy with an objective response rate (ORR) of 49%, a median PFS of 4.2 months and a median OS of 16.8 months (1). A phase II study recently reported a PFS of 4.1 months among unresectable and/or metastatic soft tissue sarcoma (17). By contrast, the

present study demonstrated that VG161 monotherapy achieved a prolonged PFS (>11.9 months) of a case of STS that previously progressed after chemotherapy. Although the OS is undefined so far, improved OS data are expected as the follow-up time for one of these two patients exceeds 14.3 months, which is the median OS reported in the literature (17). With this encouraging result, a clinical trial of VG161 monotherapy focusing on sarcoma is being planned to be launched.

So far, only limited subtypes of sarcoma have demonstrated a response to immune therapies. Atezolizumab, as the first systemic therapy, was approved for alveolar soft part sarcoma, which reported an overall response rate of 24% and a durable response rate at 6 and 12 months of 67 and 42%, respectively (18). The clinical trial has reported that responses to immune therapies occurred in numerous subtypes of sarcoma (19). Among the 38 patients that received nivolumab monotherapy, the confirmed ORR was 5% [92% CI (1-15%)]. Responses occurred in undifferentiated pleomorphic sarcoma (UPS) and sarcoma not otherwise specified (NOS). For the 38 patients that received nivolumab in combination with ipilimumab therapy, the confirmed ORR was 16%, [92% CI (7-29%)]. Responses occurred in UPS, leiomyosarcoma, myxofibrosarcoma and angiosarcoma. Nivolumab alone demonstrated limited efficacy in an unselected sarcoma population; however, nivolumab combined with ipilimumab demonstrated preliminary efficacy in certain sarcoma subtypes. To date, no immune therapy has been approved for the two subtypes of sarcoma reported in the current study.

Unlike conventional chemotherapy, the ORR usually does not represent the prolonged PFS and OS with anti-cancer immune therapy. The ORR of ipilimumab in combination with nivolumab for patients with metastatic sarcoma was reported to be only 16%, but significantly prolonged PFS and OS were achieved, which appears to be more important for efficacy assessment (19). Instead of directly killing cancer cells, immune therapy can cause tumor dormancy through activation of anti-cancer immunity, resulting in prolonged PFS and OS. None of the two cases reported in the present study achieved partial response, but the best overall response was SD. Together with the prolonged PFS and OS, it reflected the activation of anti-cancer immunity by VG161 treatment, which was also demonstrated by the laboratory findings, as discussed in the following section.

Certain progress has been made in therapies of oncolytic viruses in sarcoma. A phase II trial of Talimogene laherparepvec plus pembrolizumab in patients with locally advanced or metastatic sarcoma who had failed at least one standard systemic therapy reported the efficacy data. The primary endpoint was the ORR at 24 weeks, which was 35% (20). A phase II clinical trial is investigating the combination of JX-594, a thymidine kinase gene-inactivated oncolytic virus expressing the granulocyte-macrophage colony-stimulating factor, combined with metronomic cyclophosphamide (arm 1) compared with metronomic cyclophosphamide (arm 2) in patients with advanced STS. None of the patients in arm 1 were progression-free at six months, while one out of four was progression-free at six months in arm 2 (21). Of note, the present study found a clinical meaningful PFS benefit of the treatment with immune-stimulating HSV-1 oncolytic virus VG161 in patients with sarcoma, with high tolerance and a good safety profile.

The clinical benefit observed in the two patients of the present study may be explained by the upregulation of IFN- γ induced by VG161. The IFN pathway has an important role in the human immune response. Following the virus entering the human body, the innate and adaptive immune responses are being triggered to defend against the virus. One of the critical pathways against the viral invasion is the IFN pathway (22); however, it also stimulates anti-tumor activity. Therefore, IFNs are used in the treatment of numerous types of cancer (23). In the present trial, the level of IFN- γ was apparently increased after VG161 treatment in both cases where prolonged PFS/OS was observed.

Along with IFN- γ , and when biopsy samples from Case 2 were examined, an increase in the number of immune cells, including activated and resting NK cells, CD8⁺ cells and memory B cells were also detected post-treatment. On the other hand, the numbers of T-regulatory cells were decreased in the post-treatment samples. Although systemic changes in CD8⁺ and NK cells were not significant, it may be an important indication for the safety of VG161 treatment. Furthermore, these results, along with the tumor biopsy immune cell composition, may indicate local changes in the tumor microenvironment, as well as infiltration of immune cells, which may be more significant than systemic changes in the peripheral immune cell composition.

Taken together, the current findings point out an increased activation of the immune system, locally and systemically. Another interesting finding was the upregulation of PD-L1 in post-treatment biopsy samples. This finding strongly suggests that combination therapy of VG161 with checkpoint inhibitors (CPI) may be warranted in these patients. Furthermore, clinical trials of combination therapy of VG161 with CPI are ongoing in China and the US (NCT05162118, NCT05223816, NCT06008925 and NCT06124001).

Finally, another incidental finding through the RNA-seq analysis was the presence of a fusion gene in Case 2 ('RP11-680G10.1:GSE1' on the chromosome 16 '+' strand) that has been previously reported to be associated with sarcomas (14), while the association between the reported anti-tumor activity and the gene fusion remains to be elucidated.

In conclusion, patients with advanced chondrosarcoma and STS treated with VG161 intratumoral injection had a prolonged PFS and potentially OS benefit compared to previously reported data in the literature (1,16,17). This promising outcome may be attributed to the ability of VG161 to activate anti-cancer immunity and transform an immune-suppressive tumor microenvironment into an immune-active one. The encouraging results observed in these two patients provide strong support for conducting further investigations into the efficacy of VG161 in sarcoma through well-designed clinical trials in the future.

The potential of VG161 to induce a durable response and activate the immune system against sarcomas may open up new avenues for effective treatment options, offering hope for improved outcomes for patients facing this challenging disease. Further research through clinical trials will be essential to validate and fully understand the benefits and mechanisms of VG161 therapy in treating sarcomas.

Acknowledgements

Not applicable.

Funding

Virogin provided funding for this research.

Availability of data and materials

The data generated in the present study may be found in the National Center for Biotechnology Information (NCBI) Sequence Read Archive under BioProject no. PRJNA1066249 or the following URL: <https://www.ncbi.nlm.nih.gov/bioproject/PRJNA1066249>.

Authors' contributions

Conceptualization: YQ, AQ, RZ, WJ, QT and GK. Methodology: YQ, AQ, QT and GK. Writing-original draft preparation: YQ and AQ. Writing-review and editing: YQ, AQ, JD, WJ and YM. Translational findings-analysis: JD, WJ, MS and YM. All authors have read and agreed to the published version of the manuscript. YQ and AQ confirm the authenticity of the raw clinical data. JD and YM confirm the authenticity of the raw non-clinical data.

Ethics approval and consent to participate

The protocol was approved by the Institutional Review Board/Independent Ethics Committee of the Southern Oncology Clinical Research Unit, St Vincent's Public Hospital and Royal Brisbane and Women's Hospital (ethical approval nos. 2019-11-950-AA-A-1, 2019-11-950-A-9 and HREC/2021/QRBW/78009, respectively). The above three hospitals have participated in this Phase I study. Informed consent was obtained from all subjects participated in the study, including the statement of participation in an experimental study/receiving experimental treatment.

Patient consent for publication

Written informed consent was obtained from the patients to publish their data and images presented in this paper.

Competing interests

YQ, AQ, RZ, JD, WWGJ, MS, YM and QT are either current or former employees of Virogin Biotech, a company focusing on developing oncolytic virotherapy. This company funded this study and provided the oncolytic virus VG161 used in the study.

References

- NCCN: NCCN Clinical Practice Guidelines in Oncology (NCCN Guidelines®) Soft Tissue Sarcoma version 2.2023. <https://www.nccn.org/guidelines/guidelines-detail?category=1&id=1464>. Accessed August 3, 2023.
- Damerell V, Pepper MS and Prince S: Molecular mechanisms underpinning sarcomas and implications for current and future therapy. *Signal Transduct Target Ther* 6: 246, 2021.
- Cocco E, Scaltriti M and Drilon A: NTRK fusion-positive cancers and TRK inhibitor therapy. *Nat Rev Clin Oncol* 15: 731-747, 2018.
- Albarrán V, Villamayor ML, Pozas J, Chamorro J, Rosero DI, San Román M, Guerrero P, Pérez de Aguado P, Calvo JC, García de Quevedo C, *et al*: Current landscape of immunotherapy for advanced sarcoma. *Cancers* 15: 2287, 2023.
- Macedo N, Miller DM, Haq R and Kaufman HL: Clinical landscape of oncolytic virus research in 2020. *J Immunother Cancer* 8: e001486, 2020.
- Su Y, Su C and Qin L: Current landscape and perspective of oncolytic viruses and their combination therapies. *Transl Oncol* 25: 101530, 2022.
- Chouljenko DV, Ding J, Lee IF, Murad YM, Bu X, Liu G, Delwar Z, Sun Y, Yu S, Samudio I, *et al*: Induction of durable antitumor response by a novel oncolytic herpesvirus expressing multiple immunomodulatory transgenes. *Biomedicines* 8: 484, 2020.
- Ding J, Murad YM, Sun Y, Lee IF, Samudio I, Liu X, Jia WW and Zhao R: Pre-existing HSV-1 immunity enhances anticancer efficacy of a novel immune-stimulating oncolytic virus. *Viruses* 14: 2327, 2022.
- Hokland P and Heron I: Analysis of the lymphocyte distribution during Isopaque-Ficoll isolation of mononuclear cells from human peripheral blood. *J Immunol Methods* 32: 31-39, 1980.
- National Institutes of Health National Cancer Institute: Common Terminology Criteria for Adverse Events (CTCAE). Version 5.0. https://ctep.cancer.gov/protocoldevelopment/electronic_applications/docs/CTCAE_v5_Quick_Reference_8.5x11.pdf. Accessed November 27, 2017.
- Eisenhauer EA, Therasse P, Bogaerts J, Schwartz LH, Sargent D, Ford R, Dancy J, Arbuck S, Gwyther S, Mooney M, *et al*: New response evaluation criteria in solid tumours: Revised RECIST guideline (version 1.1). *Eur J Cancer* 45: 228-247, 2009.
- Seymour L, Bogaerts J, Perrone A, Ford R, Schwartz LH, Mandrekar S, Lin NU, Litière S, Dancy J, Chen A, *et al*: iRECIST: Guidelines for response criteria for use in trials testing immunotherapeutics. *Lancet Oncol* 18: e143-e152, 2017.
- Amin MB, Greene FL, Edge SB, Compton CC, Gershenwald JE, Brookland RK, Meyer L, Gress DM, Byrd DR and Winchester DP: The eighth edition AJCC cancer staging manual: continuing to build a bridge from a population-based to a more 'personalized' approach to cancer staging. *CA Cancer J Clin* 67: 93-99, 2017.
- Yao T, Liu JJ, Zhao LJ, Zhou JY, Wang JQ, Wang Y, Wang ZQ, Wei LH, Wang JL and Li XP: Identification of new fusion genes and their clinical significance in endometrial cancer. *Chin Med J (Engl)* 132: 1314-1321, 2019.
- Monga V, Mani H, Hirbe A and Milhem M: Non-conventional treatments for conventional chondrosarcoma. *Cancers* 12: 1-12, 2020.
- Xie L, Xu J, Sun X, Liu K, Li X, He F, Liu X, Gu J, Lv Z, Yang R, *et al*: Apatinib for treatment of inoperable metastatic or locally advanced chondrosarcoma: What we can learn about the biological behavior of chondrosarcoma from a two-center study. *Cancer Manag Res* 12: 3513-3525, 2020.
- Ayodele O and Abdul Razak AR: Immunotherapy in soft-tissue sarcoma. *Curr Oncol* 27 (Suppl 1): S17-S23, 2020.
- Bergsma EJ, Elgawly M, Mancuso D, Orr R, Vuskovich T and Seligson ND: Atezolizumab as the first systemic therapy approved for alveolar soft part sarcoma. *Ann Pharmacother* 19: 10600280231187421, 2023.
- D'Angelo SP, Mahoney MR, Van Tine BA, Atkins J, Milhem MM, Jahagirdar BN, Antonescu CR, Horvath E, Tap WD, Schwartz GK and Streicher H: Nivolumab with or without ipilimumab treatment for metastatic sarcoma (Alliance A091401): Two open-label, non-comparative, randomised, phase 2 trials. *Lancet Oncol* 19: 416-426, 2018.
- Kelly CM, Antonescu CR, Bowler T, Munhoz R, Chi P, Dickson MA, Gounder MM, Keohan ML, Movva S, Dholakia R, *et al*: Objective response rate among patients with locally advanced or metastatic sarcoma treated with talimogene laherparepvec in combination with pembrolizumab: A phase 2 clinical trial. *JAMA Oncol* 6: 402-408, 2020.
- Toulmonde M, Cousin S, Kind M, Guegan JP, Bessede A, Le Loarer F, Perret R, Cantarel C, Bellera C and Italiano A: Randomized phase 2 trial of intravenous oncolytic virus JX-594 combined with low-dose cyclophosphamide in patients with advanced soft-tissue sarcoma. *J Hematol Oncol J Hematol Oncol* 15: 149, 2022.
- Barber GN: Host defense, viruses and apoptosis. *Cell Death Differ* 8: 113-126, 2001.
- Goldstein D and Laszlo J: The role of interferon in cancer therapy: A current perspective. *CA Cancer J Clin* 38: 258-277, 1988.

