

Predictive value of Smac, VEGF and Ki-67 in rectal cancer treated with neoadjuvant therapy

HONGJIANG YAN¹, RENBEN WANG¹, JINMING YU¹, SHUMEI JIANG¹,
KUNLI ZHU¹, DIANBIN MU² and ZHONGFA XU³

Departments of ¹Radiation Oncology, ²Pathology, and ³General Surgery, Shandong Tumor Hospital, Jinan 250117, P.R. China

Received March 24, 2010; Accepted May 27, 2010

DOI: 10.3892/ol.00000113

Abstract. The present study aimed to identify whether second mitochondria-derived activator of caspase (Smac), vascular endothelial growth factor (VEGF) and proliferating cell nuclear antigen (Ki-67) expression in pre-treatment tumor biopsies are useful predictive markers of tumor response in patients with rectal cancer undergoing pre-operative chemoradiotherapy (CRT). Paraffin-embedded tissues obtained before and after therapy were evaluated by immunohistochemical staining for Smac, VEGF and Ki-67. The study evaluated the correlation of Smac, VEGF and Ki-67 immunoreactivity in tumor biopsies before treatment of tumor response to pre-operative CRT. Regarding Smac, patients with a favorable response to neoadjuvant CRT had higher pre-therapy levels ($p=0.011$). The level of Smac expression decreased after neoadjuvant therapy ($p=0.044$). However, VEGF expression was found to be negatively and significantly correlated with a favorable tumor response to neoadjuvant CRT ($p=0.010$). A transient increase in VEGF expression was detected in the resected specimens following neoadjuvant therapy ($p=0.030$). In addition, tumors with a low Ki-67 labeling index (Ki-67-LI) expression were found to be more sensitive to neoadjuvant therapy than those with a high expression of Ki-67-LI ($p=0.034$). In contrast to VEGF, the Ki-67 expression level decreased after neoadjuvant therapy. Smac, VEGF and Ki-67 expression levels, assessed immunohistochemically from pre-treatment tumor biopsies, may be useful predictive markers of rectal tumor response to pre-operative CRT.

Introduction

Pre-operative chemoradiotherapy (CRT) is the current standard treatment for locally advanced rectal cancer (1-5). Pre-operative

CRT for locally advanced rectal cancer has several potential advantages, including a decrease in tumor volumes, introduction of downstaging, an increase in the possibility of R0 resection, a reduction in radiation-induced toxicity, enhanced probability of anal sphincter preservation by shrinking large distal tumors, a reduction in local recurrence and improvement in survival (6-10). However, the response of individual tumors to adjuvant therapies is not uniform. The majority of patients benefit from pre-operative CRT while a small percentage of the patient population is less likely to respond to this treatment. In order to offer patients individualized therapy, the identification of predictive markers of cancer response to pre-operative CRT are necessary.

The present study investigated three proteins that are known to play a significant role in the growth and development of numerous tumors.

Second mitochondria-derived activator of caspase (Smac) is a novel pro-apoptotic protein first reported by Du *et al* in 2000 (11). Under the induction of apoptotic stimuli, such as an anti-cancer drug, DNA damage, exposure to ultraviolet radiation or chemical signals, the pro-Smac proteins, composed of 293 amino acids, can be cut off from their signal peptides to become active Smac proteins that are then released from mitochondria into the cytosol along with cytochrome c to promote apoptosis. Through the interaction with inhibitors of apoptosis proteins (IAPs), Smac hydrolyzes caspase-3 protein and enhances the catalytic activity of mature caspase-3, thereby promoting apoptosis (11).

Various studies have demonstrated that vascular endothelial growth factor (VEGF) is absent in normal colorectal mucosa, but present in carcinomas (12,13). VEGF is associated with mediation to tumor angiogenesis. VEGF is activated in tumor cells by several factors, including tumor suppressor genes, hypoxia and oncogenes (14). The activation of VEGF results in the formation of new vasculature and endothelial cell migration which supports the growth of the tumor and its nutrient requirements (15). *In situ* hybridization trials showed that the transcription of VEGF mRNA in rectal tumors is up-regulated during the progression from adenoma to carcinoma (16,17). New blood vessels are characterized by increased permeability, causing less efficient delivery of chemotherapeutic agents and a decreased response to radiotherapy (18,19). Anti-VEGF therapy, in combination with chemotherapy and/or radiotherapy for rectal cancer, is a promising approach (18,20).

Correspondence to: Dr Renben Wang, Department of Radiation Oncology, Shandong Tumor Hospital, Jinan 250117, P.R. China
E-mail: wangrenben@tom.com

Key words: rectal cancer, second mitochondria-derived activator of caspase, vascular endothelial growth factor, Ki-67, pre-operative chemoradiotherapy

Table I. Change in Smac, VEGF and Ki-67 expression before and after neoadjuvant therapy.

	Smac		VEGF		Ki-67	
	Low	High	Negative	Positive	Low	High
Pre-treatment	16	24	17	23	20	20
Post-treatment	25	15	8	32	23	17
P-value	0.044		0.030		0.501	

Ki-67 is associated with regulation of the cell cycle. It is a nuclear protein that is present in the later G1, S, G2 and M phases of the cell cycle, and is thus a good marker of proliferation (21). The Ki-67 labeling index (Ki-67-LI) is likely to be associated with the downstaging of highly proliferative tumors.

By investigating the change in expression of these proteins, it may be possible to predict which patients respond favorably to pre-operative CRT.

Materials and methods

Patients. A total of 40 patients with rectal adenocarcinoma were enrolled in the present study. Informed written consent was obtained from each patient. The study was approved by the Ethisc Committee of Shandong Tumor Hospital. The patients underwent flexible endoscopy with rectal biopsy, a complete blood count, a biochemical profile and serum CEA level tests. Chest X-ray, abdominal and pelvic computed tomography (CT), magnetic resonance imaging, PET-CT and/or endoscopic ultrasonography were performed to exclude tumor, node and metastasis (TNM) stage I and IV tumors. Patients with abdominal nodal disease or metastases were excluded from the study. The complete blood count, urinalysis, liver-function tests and chest X-ray were all normal in all 40 patients.

Treatment. The patients underwent CT simulation for three-dimensional conformal radiotherapy planning and the three-field technique (one posterior field and two lateral fields). The clinical target volume of the pre-operative radiotherapy consisted of the primary tumor, the mesentery including vascular supply and the perirectal, presacral and internal iliac nodes (up to the S1/S2 junction). The planned target area was formed by enlarging the area by 10-15 mm on the basis of the clinical target volume. Pre-operative radiotherapy was delivered in fractions of 2 Gy to reach a dose of 40 Gy at 5 fractions per week. All 40 patients received concurrent chemotherapy (300 mg/m² 5-FU, 200 mg/m² oxaliplatin and 100 mg/m² leucovorin) during the first 5 and last 5 days of radiotherapy. The patients received a total mesorectal excision procedure after a lengthy interval of up to 4-6 weeks. Tumor response was classified as complete response (CR, no residual tumor), partial response (PR, tumor volume diminished >50% and/or downstaging) and no response (NR) after post-operative pathological analysis of the tumor specimens.

Immunohistochemical assay of Smac, VEGF and Ki-67. Paraffin-embedded tumors from both the biopsy before treatment (n=40) and the tumor tissue from the resection specimen

(n=40) were used to make donor blocks. Sections (4 μ m) were pre-treated with fresh xylene for 10 min and rehydrated using gradient alcohol. The sections were microwaved at high power for 25 min in citrate buffer, pH 6.0, allowed to cool and then washed in phosphate-buffered saline. The slides were examined independently by two of the authors, without any information pertaining to the patients or the results of the routine histological examination. The Ki-67-LI, Smac and VEGF expression in 40 pre-treatment rectal tumor biopsies and operative specimens was analyzed by immunohistochemistry using specific antibodies. The PV-9000 polymer detection system for immunohistological staining was purchased from Beijing Zhongshan Golden Bridge Biotechnology Company (China). The test was performed when necessary. The slides were evaluated for this study by an expert pathologist.

Methods of analysis. Sections were analyzed at a total magnification of x400. Each core was assigned a continuous score of percentage positivity, representative of the approximate area of immunostaining. For Smac, positive staining was defined as plasma which stained light yellow or pale brown in the section. According to the percentage of positive cells, samples with <5% positive cells were defined as negative, samples with 10-30% positive cells were weakly positive and samples with >30% positive cells were characterized as strongly positive. For VEGF, the percentage of cells with positivity in the cytoplasm was determined, and the scoring system was: 0, negative for VEGF; 1+, <20% positive cells; 2+, 20-50% positive staining and 3+, >50% staining. For Ki-67, all stained nuclei were scored. Tumor reactivity was expressed as the Ki-67 index (i.e., the number of stained tumor cells per 1,000 cells in each section). The percentage of cells showing distinct nuclear staining was determined.

Statistical analysis. Statistica 13.0 was used for the statistical analysis. Smac, VEGF and Ki-67 expression was evaluated using the Chi-square or Fisher's exact tests. P=0.05 was set as the threshold for statistical significance.

Results

Expression of Smac, VEGF and Ki-67 in pre-treatment biopsies and post-operative specimens (Fig. 1 and Table I). Tumors were classified into two groups according to the percentage of Smac staining, i.e., high or low expression. Of the 40 pre-treatment biopsies, Smac was highly expressed in 24 (60%) specimens. Of the 32 post-operative specimens, Smac was highly expressed in 15 (46.9%) cases. Smac expression was

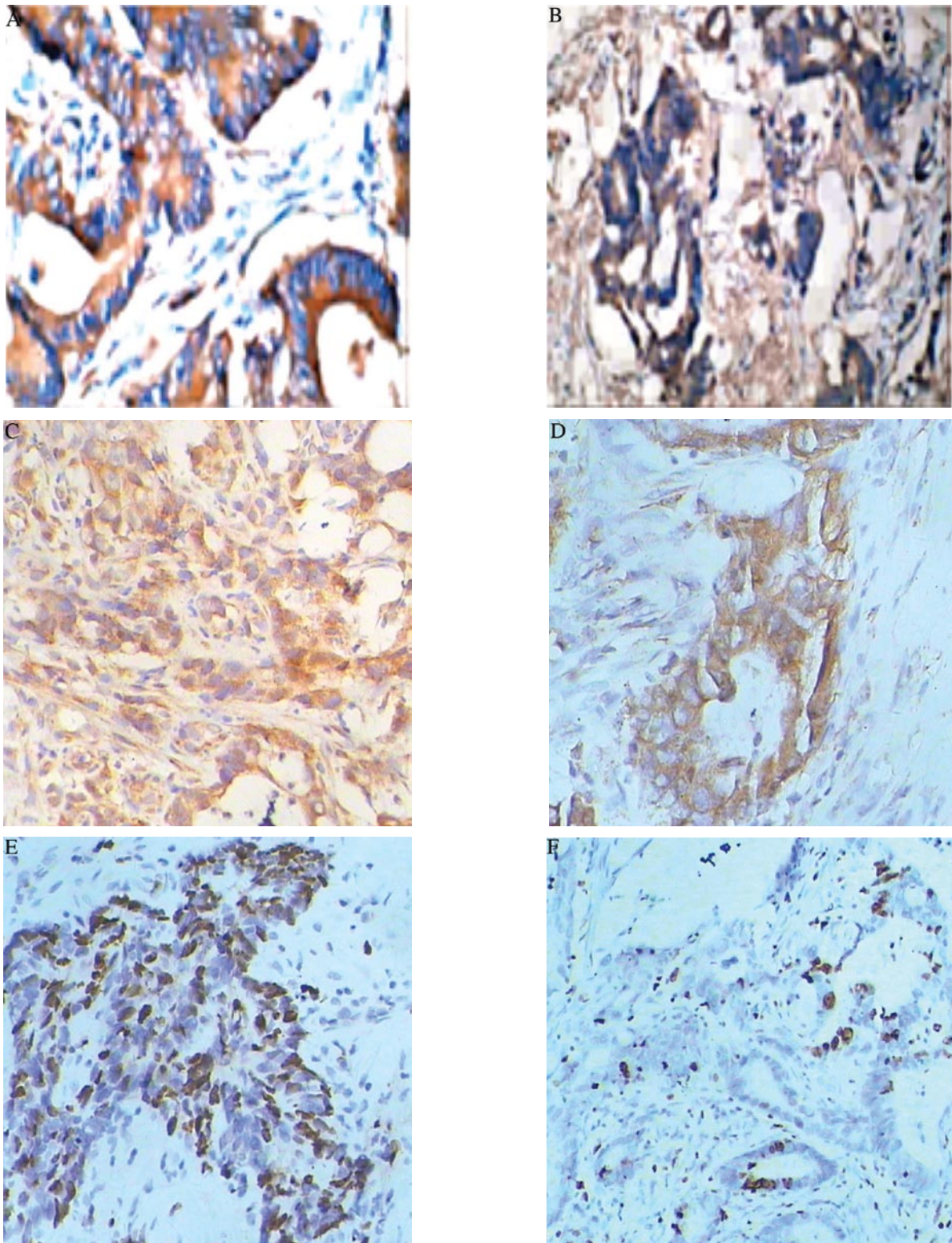


Figure 1. Smac, VEGF and Ki-67 expression. (A) Smac expression in a pre-treatment biopsy, 80%; (B) Smac expression in a surgical specimen, 15%; (C) VEGF expression in a pre-treatment biopsy, +; (D) VEGF expression in a surgical specimen, +++; (E) Ki-67 expression in a pre-treatment biopsy, 75%; (F) Ki-67 expression in a surgical specimen, 5%.

slightly lower after neoadjuvant therapy ($p=0.044$). The VEGF-stained signal was located in the cytoplasm and was present as a bulky yellow grain. Of the pre-treatment biopsies and post-operative specimens, 23 (57.5%) and 32 (80%), respectively, were positive. This difference was statistically significant ($p=0.030$). Tumors were classified into two groups according

to the percentage of Ki-67 staining and were characterized as exhibiting high or low proliferation. Tumors were determined to be highly proliferative when $>25\%$ of cells were Ki-67-positive. Of the 40 pre-treatment biopsies and post-operative specimens, Ki-67 was highly expressed in 20 (50%) and 17 (42.5%) cases, respectively. Ki-67 expression was slightly

Table II. Correlations between Smac, VEGF and Ki-67 expression and clinicopathological characteristics.

Clinicopathological characteristics	No. of cases	Smac			VEGF			Ki-67		
		Low	High	P-value	Negative	Positive	P-value	Low ($\leq 10\%$)	High ($> 10\%$)	P-value
Age (years)										
<50	16	5	11	0.356	7	9	0.896	7	9	0.519
≥ 50	24	11	13		10	14		13	11	
Gender										
Male	28	10	18	0.490	12	16	0.944	13	15	0.490
Female	12	6	6		5	7		7	5	
Tumor size (cm)										
≤ 5	30	11	19	0.482	13	17	1.000	17	13	0.144
> 5	10	5	5		4	6		3	7	
Adenocarcinoma										
Well- and moderately differentiated	28	11	17	1.000	13	15	0.443	16	12	0.168
Poorly differentiated	12	5	7		4	8		4	8	
Lymph nodal status										
Present	16	10	6	0.018	3	13	0.013	4	12	0.010
Absent	24	6	18		14	10		16	8	
Infiltration depth										
T2	13	3	10	0.130	9	4	0.018	8	5	0.311
T3	27	13	14		8	19		12	15	
TNM stage										
II	23	6	17	0.037	13	10	0.037	13	10	0.337
III	17	10	7		4	13		7	10	

lower after neoadjuvant therapy, but no statistical significance was found. No considerable differences in immunoreactivity were noted between the core and invasive edge of the tumors.

Correlations between Smac, VEGF and Ki-67 expression of the pre-treatment biopsies and patient clinicopathological characteristics (Table II). The level of Smac expression was significantly correlated with lymph node metastasis ($p=0.018$) and TNM stage ($p=0.037$), but not with histological type, depth of tumor invasion, tumor size, age and gender of the patients ($p>0.05$). VEGF expression exhibited no statistical significance among the different histological types of rectal cancer ($p=0.443$). A significant relationship was noted between patients with and without lymph nodal metastasis ($p=0.013$). It was significantly correlated with the depth of tumor invasion ($p=0.018$) and TNM stage ($p=0.037$). No significant correlation was noted between VEGF expression and gender, age and tumor size ($p>0.05$). Ki-67 expression was statistically significant between patients with and without lymph nodal metastasis ($p=0.010$). The remaining variables that were evaluated (age, gender, TNM stage, tumor size, histological type and depth of tumor invasion) were not significantly associated with Ki-67 expression ($p>0.05$).

Correlations between predictive markers and tumor response (Table III). Smac, VEGF and Ki-67 expression was signifi-

cantly correlated with tumor response to neoadjuvant therapy ($p=0.011$, $=0.010$ and $=0.034$, respectively). Tumors with a high expression of Smac and a low expression of Ki-67 or VEGF were more sensitive to neoadjuvant therapy.

Correlations between Smac and VEGF and Ki-67 expression (Table IV). A significant correlation was noted between Smac and Ki-67 expression ($p=0.010$). However, no correlation was found between VEGF and Ki-67 expression ($p>0.05$).

Discussion

Although beneficial results are obtained with the current multimodal treatment of rectal cancer, 'patient-tailored' treatments are expected to provide greater benefit. This study analyzed the potential value of Smac, VEGF and Ki-67 proteins in predicting the response of tumors to pre-operative chemoradiation.

Second mitochondria-derived activator of caspase/direct inhibitor of apoptosis-binding protein with a low pI (Smac/DIABLO) is a recently identified pro-apoptotic protein that interacts with and inhibits numerous IAPs, including survivin (11,22). Smac binds to the domain of X-linked inhibitor of apoptosis (XIAP) which is responsible for binding to processed caspase-9, thus, antagonizing the anti-apoptotic function of XIAP. Evidence suggests that the pro-apoptotic function of Smac/DIABLO is linked to an additional mechanism that is

Table III. Correlations between predictive markers and tumor response.

Predictive markers	No. of cases	Tumor response			χ^2 -value	P-value
		CR	PR	NR		
Smac					8.985	0.011
Low	16	2	4	10		
High	24	5	15	4		
VEGF					9.241	0.010
Negative	17	7	9	1		
Positive	23	3	9	11		
Ki-67-LI					6.781	0.034
Low	20	7	11	2		
High	20	6	5	9		

CR, complete response; PR, partial response; NR, no response; Ki-67-LI, Ki-67 labeling index.

Table IV. Correlations between Smac and VEGF and Ki-67 expression.

	Smac				VEGF			
	Low	High	χ^2 -value	P-value	Negative	Positive	χ^2 -value	P-value
Ki-67			6.667	0.010			0.921	0.337
Low	4	16			10	10		
High	12	8			7	13		
Smac							0.614	0.443
Low					8	8		
High					9	15		

different from IAP binding (23). The role of this protein during carcinogenesis has yet to be investigated. However, Smac/DIABLO mRNA levels have been found to be significantly lower in lung cancers when compared to normal tissues. It was shown that patients with low Smac/DIABLO mRNA levels had worse prognosis. The presence of mature Smac was not sufficient to trigger the apoptosis of healthy cells. However, cells with excess Smac protein were greatly sensitized to apoptotic triggers, such as etoposide exposure (24).

We initially reported the correlation between Smac expression and tumor response to pre-operative chemoradiation. In the present study, the level of Smac expression was significantly correlated with lymph node metastasis and TNM stage ($p < 0.05$). It was noted that tumors with a high Smac expression were more sensitive to neoadjuvant therapy. Zheng *et al* found that the stable transfer of the extrinsic Smac gene and its overexpression in cervical cancer cell lines significantly enhanced the expression and activities of cellular caspase-3 and ameliorated the apoptosis-inducing effects of irradiation on cancer cells, a novel strategy in the improvement of radiotherapeutic effects on cervical cancer (25). Jia *et al* demonstrated that mature Smac enhanced the susceptibility of K562 and CEM cells to TRAIL-induced apoptosis (26). Overexpression of the mature Smac protein also inhibited proliferation, as detected by the reduced colony formation and Ki-67 expression in

leukaemic cells. Cell cycle analysis showed that Smac transfectants displayed significant G0/G1 arrest and reduction in 5-bromo-20-deoxyuridine incorporation. In addition, Smac was found to sensitize human acute myeloid leukaemia blasts to the cytochrome c-induced activation of caspase-3. Thus, it was shown that Smac/DIABLO exhibits a potential role in increasing apoptosis and suppressing proliferation in human leukaemic cells (26). Additionally, a significant negative correlation between Smac and Ki-67 expression ($p < 0.05$) was found.

We investigated the level of VEGF expression in 40 pre-treatment biopsies and post-operative specimens of rectal cancer patients. The patient group with lymph nodal metastasis exhibited a higher expression compared to the group without metastasis. VEGF expression was also elevated with increasing depth of invasion. VEGF expression was temporarily overexpressed following neoadjuvant therapy. Zlobec *et al* investigated the relationship of VEGF expression of rectal cancer patients and neoadjuvant therapy. Low or absent VEGF in pre-irradiation rectal tumor biopsies was strongly associated with complete tumor response. By contrast, non-response tumors were more highly immunoreactive and had a higher VEGF expression than completely responsive tumors (27). Giralt *et al* studied 81 patients with locally advanced rectal cancer treated with pre-operative radiotherapy and found that the VEGF expression was associated with a

less favorable disease-free survival. This difference was significantly related to the development of metastatic disease. A high expression of VEGF was associated with poor prognosis (28). VEGF, assessed immunohistochemically from pre-treatment tumor biopsies, may be a useful marker in the prediction of tumor response to pre-operative CRT (29). Few reports exist, however, involving VEGF expression in rectal cancer patients both prior to treatment and post-treatment. In the present study, the VEGF expression increased significantly following neoadjuvant therapy at 4-6 weeks. In a previous study, Inoue *et al* investigated the interactions between CRT and the expression of VEGF *in vivo* and *in vitro*. The study showed that there was a significant increase in local VEGF levels, *in vivo* and *in vitro*, after CRT, particularly in viable cancer cells, possibly due to a reduction in tumor volume induced by the CRT (30).

We aimed to correlate the expression of Ki-67 with response in a patient population with locally advanced rectal tumors. Ki-67 expression was clearly diminished following pre-operative CRT. Findings by Rau *et al* found the down-regulation of Ki-67 after neoadjuvant treatment, indicating that highly proliferative tumor cells are the most sensitive to neoadjuvant treatment (31). However, our results showed that patients with a favorable response during pre-operative CRT exhibited a low expression of Ki-67 in the resection specimens, suggesting that the effect of the treatment on proliferation was crucial for a beneficial response. Kim *et al* observed a significantly positive correlation between the cellular proliferative index and tumor response in rectal cancer after pre-operative concurrent chemoradiotherapy (CCRT), indicating that Ki-67 labeling may be a useful parameter for radiosensitive tumors selected for CCRT (32). Scholzen *et al* investigated a large number of cancer samples and reported that the value of Ki-67 as a prognostic marker for survival and tumor recurrence was repeatedly confirmed in uni- and multivariate analyses (33). There are a number of indications that Ki-67 protein expression is a requirement for progression through cell division. Ki-67 expression is highly associated with cell proliferation. Adell *et al* studied 152 rectal cancers and found that Ki-67 expression of pre-operative biopsies correlated with radiotherapy sensitivity (34). The interaction between Ki-67 status and the benefit of radiotherapy was significant for a reduced recurrence rate. Many Ki-67-stained tumor cells in the pre-operative biopsy predicted an increased treatment failure rate after radiotherapy of rectal cancer. Debucquoy *et al* found that Ki-67 was present in all biopsies and resection specimens and was down-regulated after therapy in 83% of the patients (35). In this study, the expression decreased significantly with a median value of 90% in the biopsies compared to 45% in the resection specimens. A lower pre-therapy concentration of Ki-67 was associated with CR. Furthermore, no significant correlation was found between Ki-67 expression and patient gender, age and tumor size, while Ki-67 was significantly correlated with lymph node metastasis, pathological stage and prognosis. On the other hand, a statistically significant difference ($p < 0.05$) in the Ki-67 expression between patients with and without lymph nodal metastasis was noted in our study. Patients with a high expression of Ki-67 presented with lymph nodal metastasis and exhibited a poor prognosis. These results indicated that Ki-67 expression correlated with tumor

progression. No statistical significance was found between Ki-67 expression and age, gender, histological type, tumor size and the depth of tumor invasion. Ki-67 expression was higher in the patient group with lymph nodal metastasis and tumor-eroded chorion group than the negative group. The Ki-67 expression decreased after the patients received CRT, indicating that Ki-67 expression was closely related to a deteriorating degree of tumor and biology behavior. No statistical significance between Ki-67 expression and tumor differentiation was noted in our study, which may have been due to the small sample size. In addition, tumor cell proliferation may be influenced by various factors. The degree of malignancy of tumors is related to the invasive ability of tumor cells. On the other hand, different methods and diverse samples result in varied conclusions. To ensure the significance of Ki-67 expression in rectal cancer, studies with a large population of samples are required. As concurrent radiotherapy and chemotherapy enhance the efficacy of therapy, we suggest that this type of treatment is applied to patients with rectal cancer, even in those with a high expression of Ki-67.

The limitations of our study included: i) The investigation comprised a small patient population; ii) the classification of clinical stages using magnetic resonance imaging for rectal cancer is not exact; and iii) the protein expression in biopsies may not be representative of the entire tumor.

In conclusion, the results of this study indicate that Smac, VEGF and Ki-67, assessed immunohistochemically from pre-treatment tumor biopsies, may be useful markers in the prediction of tumor response to pre-operative CRT. Through the assessment of Smac, VEGF and Ki-67 expression, we can also estimate the degree of malignancy and prognosis of rectal cancer patients.

Acknowledgements

This study was supported by Shandong Tumor Hospital, China.

References

1. Sauer R, Becker H, Hohenberger W, *et al*: Preoperative versus postoperative chemoradiotherapy for rectal cancer. *N Engl J Med* 351: 1731-1740, 2004.
2. Bosset JF, Calais G, Mineur L, *et al*: Enhanced tumoricidal effect of chemotherapy with preoperative radiotherapy for rectal cancer: preliminary results-EORTC 22921. *J Clin Oncol* 23: 5620-5627, 2005.
3. Bosset JF, Collette L, Calais G, *et al*: Chemotherapy with preoperative radiotherapy in rectal cancer. *N Engl J Med* 355: 1114-1123, 2006.
4. Gerard J, Romestaing P, Bonnetain F, *et al*: Preoperative chemoradiotherapy (CT-RT) improves local control in T3-4 rectal cancers: results of the FFCD 9203 randomised trial. *Int J Radiat Oncol Biol Phys* 63: 2-3, 2005.
5. Das P and Crane CH: Preoperative and adjuvant treatment of localized rectal cancer. *Curr Oncol Rep* 8: 167-173, 2006.
6. McLean CM and Duncan W: Rectal cancer: a review of randomized trials of adjuvant radiotherapy. *Clin Oncol* 7: 349-358, 1995.
7. Friedmann P, Garb JL, Park WC, *et al*: Pace OT survival following moderate-dose preoperative radiation therapy for carcinoma of the rectum. *Cancer* 55: 967-973, 1985.
8. Kerman HD, Roberson SH, Bloom TS, *et al*: Rectal carcinoma. Long-term experience with moderately high-dose preoperative radiation and low anterior resection. *Cancer* 69: 2813-2819, 1992.

9. Kim DW, Lim SB, Kim DY, *et al*: Pre-operative chemo-radiotherapy improves the sphincter preservation rate in patients with rectal cancer located within 3 cm of the anal verge. *Eur J Surg Oncol* 32: 162-167, 2006.
10. Minsky BD: Oxaliplatin-based combined-modality therapy for rectal cancer. *Semin Oncol* 30: 26-33, 2003.
11. Du C, Fang M, Li Y, Li L and Wang X: Smac, a mitochondrial protein that promotes cytochrome c dependent caspase activation by elimination IAP inhibition. *Cell* 102: 33-42, 2000.
12. Kang S-M, Maeda K, Onoda N, *et al*: Combined analysis of p53 and vascular endothelial growth factor in CRC for determination of tumor vascularity and liver metastasis. *Int J Cancer* 74: 502-507, 1997.
13. Wong MP, Cheung N, Yuen ST, Leung SY and Chung LP: Vascular endothelial GF is up-regulated in the early pre-malignant stage of colorectal tumor progression. *Int J Cancer* 81: 845-850, 1999.
14. Tonini T, Rossi F and Claudio PP: Molecular basis of angiogenesis and cancer. *Oncogene* 22: 6549-6556, 2003.
15. Lutsenko SV, Kiselev SM and Severin SE: Molecular mechanisms of tumor angiogenesis. *Biochem* 68: 286-300, 2003.
16. Ferrara N, Gerber H-P and LeCouter J: The biology of VEGF and its receptors. *Nat Med* 9: 669-676, 2003.
17. Falm E: Angiogenesis inhibitors in clinical development; where are we now and where are we going? *Br J Cancer* 90: 1-7, 2004.
18. Ferrara N: Vascular endothelial growth factor: basic science and clinical progress. *Endocr Rev* 25: 581-611, 2004.
19. Harmey JH and Bouchier-Hayes D: Vascular endothelial growth factor (VEGF), a survival factor for tumour cells: implications for anti-angiogenic therapy. *Bioessays* 24: 280-283, 2002.
20. Willett C, Boucher Y, di Tomaso E, *et al*: Direct evidence that the VEGF-specific antibody bevacizumab has anti-vascular effects in human rectal cancer. *Nat Med* 10: 145-147, 2004.
21. Gerdes J, Lemke H, Baisch H, Wacker HH, Schwab U and Stein H: Cell cycle analysis of a cell proliferation-associated human nuclear antigen defined by the monoclonal antibody Ki-67. *J Immunol* 133: 1710-1715, 1984.
22. Song Z, Yao X and Wu M: Direct interaction between survivin and Smac/DIABLO is essential for the anti-apoptotic activity of survivin during taxol-induced apoptosis. *J Biol Chem* 278: 23130-23140, 2003.
23. Roberts DL, Merrison W, MacFarlane M and Cohen GM: The inhibitor of apoptosis protein-binding domain of Smac is not essential for its proapoptotic activity. *J Cell Biol* 153: 221-228, 2001.
24. Sekimura A, Konishi A, Mizuno K, *et al*: Expression of Smac/DIABLO is a novel prognostic marker in lung cancer. *Oncol Rep* 11: 797-802, 2004.
25. Zheng LD, Xiong ZF, Zhu JW and Wang ZH: Effects of Smac gene over-expression on the radiotherapeutic sensitivities of cervical cancer cell line HeLa [J]. *Chin Med J* 118: 226-230, 2005.
26. Jia L, Patwari Y, Kelsey SM, *et al*: Role of Smac in human leukaemic cell apoptosis and proliferation. *Oncogene* 22: 1589-1589, 2003.
27. Zlobec I, Steele R and Compton CC: VEGF as a predictive marker of rectal tumor response to preoperative radiotherapy. *Cancer* 104: 2517-2521, 2005.
28. Giralt J, Navalpotro B, Hermsilla E, *et al*: Prognostic significance of vascular endothelial growth factor and cyclooxygenase-2 in patients with rectal cancer treated with preoperative radiotherapy. *Oncology* 71: 312-319, 2006.
29. Kakeji Y, Koga T, Sumiyoshi Y, *et al*: Clinical significance of vascular endothelial growth factor expression in gastric cancer. *J Exp Clin Cancer Res* 21: 125-129, 2002.
30. Inoue Y, Ojima E, Watanabe H, *et al*: Does preoperative chemo-radiotherapy enhance the expression of vascular endothelial growth factor in patients with rectal cancer? *Oncol Rep* 18: 369-375, 2007.
31. Rau B, Sturm I, Lage H, *et al*: Dynamic expression profile of p21WAF1/CIP1 and Ki-67 predicts survival in rectal carcinoma treated with preoperative radiochemotherapy. *J Clin Oncol* 21: 3391-3401, 2003.
32. Kim NK, Park JK, Lee KY, *et al*: p53, BCL-2 and Ki-67 expression according to tumor response after concurrent chemo-radiotherapy for advanced rectal cancer. *Ann Surg Oncol* 8: 418-424, 2001.
33. Scholzen T and Gerdes J: The Ki-67 protein: from the known and the unknown. *J Cell Physiol* 182: 311-322, 2000.
34. Adell G, Zhang H, Jansson A, Sun XF, Stål O and Nordenskjöld B: Decreased tumor cell proliferation as an indicator of the effect of preoperative radiotherapy of rectal cancer *Int J Radiat Oncol Biol Phys* 50: 659-663, 2001.
35. Debucquoy A, Goethals L, Geboes K, Roels S, Mc Bride WH and Hausermans K: Molecular responses of rectal cancer to preoperative chemoradiation. *Radiother Oncol* 80: 172-177, 2006.