

Combination celecoxib and temozolomide in C6 rat glioma orthotopic model

SEOK-GU KANG^{1*}, JONG SOO KIM^{1*}, KWAN PARK¹,
JONG SUNG KIM², MORRIS D. GROVES³ and DO-HYUN NAM¹

¹Department of Neurosurgery, Samsung Medical Center, ²Laboratory Animal Research Center, Samsung Biomedical Research Institute, Sungkyunkwan University School of Medicine, Seoul, Korea; ³Department of Neuro-Oncology, University of Texas MD Anderson Cancer Center, Houston, TX, USA

Received July 26, 2005; Accepted August 17, 2005

Abstract. The purpose of this study was to determine whether a combination treatment of temozolomide with celecoxib is effective in the rat orthotopic glioma model. After stereotactic injection of C6/LacZ rat glioma cells into the Sprague Dawley rat brain, the rats were randomly assigned to four treatment groups [group 1, control treatment; group 2, celecoxib (25 mg/kg p.o. everyday) alone; group 3, temozolomide (7.5 mg/kg i.p. for 5 days at 2nd week) alone; group 4, a combination of celecoxib and temozolomide]. Rats were sacrificed 18 days after treatment, and the body weight, tumor volume, tumor cell proliferation, microvessel densities, and apoptosis were evaluated. There was a significant reduction of tumor volume in combination group compared to control or single-agent therapy. The median tumor volume was estimated to be 111.5 mm³ (control), 65.0 mm³ (celecoxib), 71.8 mm³ (temozolomide) and 18.7 mm³ (combination). In the combination group, there was increased tumor cell apoptosis as well as decreased microvessel density and tumor cell proliferation relative to the control and single-agent therapy (P<0.05). Collectively, the data suggest that the combination celecoxib and temozolomide may provide a novel and effective approach to the treatment of glioblastoma.

Introduction

Multimodality treatment involving surgery, radiation therapy, and chemotherapy is an accepted therapeutic strategy for glioblastoma. It is generally accepted that more extensive

resection is a good prognostic factor (1-3). Compared with the significant effect of radiation therapy on glioblastoma, chemotherapy has a limited effect on these lesions (4). However, certain patients achieve marked and prolonged responses to chemotherapy, and molecular markers are beginning to be found that may predict which patients fall into this group (5-7).

Temozolomide is a methylating agent used in the therapy of malignant glioma. It is a lipophilic analog to the triazene dacarbazine and dissolves in watery solutions spontaneously to the active metabolite 5-(3methyltriazin-1-yl)imidazole-4-carboxamide (8). Due to its lipophilic properties, it is orally available and is able readily to cross the blood-brain barrier. Apart from its methylating properties, inhibition of protein kinase C has been implicated as a possible mechanism of action (9).

Cyclooxygenase-2 (COX-2) enzyme expression may be important in maintaining a favorable milieu for tumor survival in several mechanisms such as promoting angiogenesis or inhibition of apoptosis through prostaglandin synthesis (10). Also, COX-2 inhibitors have advantages that make their use potentially beneficial for treating malignant glioma (10). Additionally, COX-2 inhibitors have impaired human glioma-derived cell line growth *in vitro* (11) and have shown intracranial inhibition in the rat glioma model (12).

In general, chemotherapeutic agents can be divided as cytotoxic or cytostatic. Cytotoxic agents result in tumor cell death using these mechanisms including DNA alkylation, DNA cross-linkage, DNA strand breaks, and mitotic spindle disruption (13). Cytostatic agents alter tumor biology by inhibiting tumor growth, tumor spread, or both, but they do not kill tumor cells directly (13). As might be expected, these cytostatic agents (*cis*-retinoic acid, thalidomide, tamoxifen, celecoxib) do not usually result in marked tumor shrinkage. However, partial responses and prolonged disease stability have occurred with several agents. They are often combined with cytotoxic agents for the treatment of glioblastoma (14-17).

To evaluate the potential of celecoxib and temozolomide as novel therapeutic agents against glioblastoma, we evaluated the effect of the combination treatment with celecoxib and temozolomide on glioblastoma cells in an orthotopic rat model, which is relatively resistant to temozolomide. In order to investigate the mechanism of growth inhibition, we evaluated

Correspondence to: Dr Do-Hyun Nam, Department of Neurosurgery, Samsung Medical Center, Sungkyunkwan University School of Medicine, 50 Irwon-dong, Gangnam-gu, Seoul 135-710, Korea
E-mail: nsnam@smc.samsung.co.kr

*Contributed equally

Key words: celecoxib, cyclooxygenase-2 inhibitor, glioblastoma, temozolomide

Table I. Therapy for C6/LacZ rat gliomas implanted orthotopically into the brains of rats.

Parameters	Treatment group			
	Control (n=10)	Celecoxib (n=10)	Temozolomide (n=10)	Celecoxib plus Temozolomide (n=10)
Median body weight (range: g)	349.3 (292.5-416)	355.3 (285.5-396)	340.5 (313.5-439)	330.0 (297-360.5)
Mean body weight \pm SD (g)	358.7 \pm 44.5	348.3 \pm 32.7	362.4 \pm 46.7	326 \pm 25.9
Median tumor volume (range: mm ³)	111.5 (63.4-137.7)	65.0 (31.5-204.0)	71.8 (35.7-153.8)	18.7 (2.3-74.1)
Mean tumor volume \pm SD (mm ³) ^a	109.8 \pm 29.9	81.1 \pm 54.3	80.3 \pm 43.1	25.8 \pm 26.2

^aA significant difference between groups is observed (Kruskal-Wallis, P<0.001).

the expression level of proliferation-related protein, endothelial cell-related protein and apoptosis-related protein, after treatment with celecoxib alone, temozolomide alone and the combination of celecoxib and temozolomide.

Materials and methods

Glioma cell lines and culture condition. The rat glioblastoma cell line C6/LacZ was obtained from the American Type Culture Collection (Manassas, VA) and maintained in DMEM supplemented with 10% fetal bovine serum, penicillin (100 units/ml), and streptomycin (100 μ g/ml) and passaged \leq 10 times. Cells were grown as monolayers in a humidified atmosphere of 5% CO₂, 37°C.

Reagents. Primary antibodies were purchased as listed: mouse anti-rat CD31 (BD Pharmigen, San Diego, CA); mouse anti-proliferating cell nuclear antigen (PCNA) clone PC 10 (Dako A/S, Copenhagen, Denmark). The following secondary antibodies were used for colorimetric immunohistochemistry (IHC) analysis: peroxidase-conjugated goat anti-rabbit IgG (Vector Laboratories, Inc., Burlingame, CA); biotinylated goat anti-rabbit IgG (Zymed Laboratories, Inc., San Francisco, CA); biotinylated anti-mouse IgG (Vector Laboratories); HRP goat anti-mouse IgG (Zymed Laboratories). Terminal deoxynucleotidyl transferase-mediated nick end-labeling (TUNEL) staining was performed using a commercial apoptosis detection kit (Chemicon International, Inc., Temecula, CA). Other reagents included stable 3,3'-diaminobenzidine (Research genetics, Huntsville, AL), ABC kit (Vector Laboratories), Gill's hematoxylin (Sigma Chemical Co., St. Louis, MO). Temozolomide (Temodal, Schering-Plough, Bruxelles, Belgium), for IP, temozolomide was dissolved in 10% DMSO at 7.5 mg/kg and prepared daily. Celecoxib [Celebrex (SC-58635), Pfizer, New York, NY] was dissolved in ethanol and prepared just before use.

Animals. The orthotopic rat glioma model was made by the implantable guide-screw system (Plastics One, Roanoke, VA)

which was composed of a guide screw, stylet, and a modified Hamilton syringe (18). All procedures were performed in accordance with the regulations of the Animal Care and Use Committee of Samsung Medical Center. The rats were housed in groups of five in cages within a standardized barrier facility and maintained on a 12-h day/night cycle at 23°C. Animals were given free access to laboratory chow and water.

Orthotopic implantation of tumor cells and necropsy procedure. Before all surgical procedures, male (200-250 g) Sprague Dawley rats were anesthetized with an intraperitoneal injection of a stock solution of ketamine hydrochloride (50 mg/ml) and xylazine (23.32 mg/ml). The heads of the anesthetized rats were shaved and disinfected with a solution of 70% ethyl alcohol and povidone iodine, after which they were secured in a rodent stereotactic frame just for head fixation. A midline incision was made on the dorsal aspect of the head with the pericranium moved laterally to expose the bregma. The guide-screw entry site was marked at a point 3.0 mm left lateral and 1 mm anterior to the bregma. This point was chosen because it is located directly above the caudate nucleus, which has been shown to be a highly reliable intracranial site for tumor engraftment (18,19). Using a small hand-controlled, 1 mm in diameter, twist drill (Plastics One), a drill hole was made in the animal's skull at the entry point. The drill bit penetrates the dura and thereby opens it. The sterilized guide screw was rotated into the hole until it was flush with the skull. The screw was threaded into the hole and secured with several firm twists. The top of the screw was approximately 1 mm above the skull surface and its shaft protruded through the dura and into the brain surface. The central hole of the guide screw was closed by placing a cross-shaped stylet inside it. The wound was closed with No. 4-0 vicryl sutures. The animals were kept warm until they recovered from anesthesia. Animals were allowed to move freely until the time of cell implantation. Seven days later, animals with the guide screw in place were reanesthetized as described earlier. The guide screw was cleaned with povidone

Parameters	Treatment group			
	Control (n=10)	Celecoxib (n=10)	Temozolomide (n=10)	Celecoxib plus Temozolomide (n=10)
PCNA ^{a,b}	141.6±54.0	69.9±15.1	71.8±16.9	39.4±10.8
CD31 (MVD) ^{a,c}	19±9.8	17±5.9	12.7±6.2	7.7±4.5
TUNEL ^{a,d}	1.2 ± 1.3	4.4 ± 1.4	6.9 ± 3.9	14.6 ± 4.0

^aA significant difference between groups is observed (Kruskal-Wallis, $P < 0.001$). ^bMean \pm SD positive cells/field determined from quantitation in 20 random fields at x400 magnification. ^cMean \pm SD positive cells/field determined from quantitation in 20 random fields at x200 magnification. ^dMean \pm SD positive cells/field determined from quantitation in 20 random fields at x400 magnification. PCNA, proliferating cell nuclear antigen; MVD, microvessel density; TUNEL, terminal deoxynucleotidyl transferase-mediated nick end-labeling.

iodine, the animal's head is held in a rodent Stereotactic frame, and the stylet was removed using fine forceps. Cells were injected into the white matter at a depth of 5 mm through a 10 μ l Hamilton syringe connected to the manipulating arm of the Stereotactic device. For this intracranial tumor model, 1×10^5 C6/LacZ glioma cells (in Hank's balanced salt solution) were implanted. All injections consisted of a total volume of 10 μ l delivered over 12.5 min by a microinfusion pump. Based on the entry point of the guide screw and the depth of needle penetration, it is certain that the cells were injected into the caudate nucleus (19). The 26-gauge needle was retracted over a period of 10-15 min. The stylet was repositioned in the screw hole by using fine forceps to close the system. The animals were kept warm until they recovered from anesthesia and were allowed to move around freely until the time of sacrifice. Rats were sacrificed 18 days after treatment and weighed. For immunohistochemistry (IHC) and H&E staining procedures, tumors were fixed in formalin and embedded in paraffin. For IHC requiring frozen tissues, tumors were embedded in OCT compound (Miles, Inc., Elkart, IN), frozen rapidly in liquid nitrogen, and stored at -80°C .

Therapy for established C6 rat glioma growing in the brain of rats. All animals underwent implantation of guide screws and after 1 week they were divided into four groups (Table I). For all animals (40 rats), 1×10^5 C6/LacZ glioma cells were injected and the animals were sacrificed 18 days later following specific treatment. Animals in group 1 (10 rats) were treated by saline (23 ml/kg/day) p.o. daily and saline (7.5 ml/kg) i.p. from 8th to 12th day. Animals in group 2 (10 rats) were treated daily by celecoxib, which was administered in the diet at a dose of 160 ppm (equivalent to 25 mg/kg/day) (12). Animals in group 3 (n=10) were treated by temozolomide, which was administered i.p. at a dose of 7.5 mg/kg from the 8th to 12th day. Animals in group 4 (n=10) were treated by the combination of celecoxib and temozolomide, in the previously described manner.

Tumor volume measurement. The fixed brains in 10% buffered formalin were cut axially every 2 mm and embedded in

paraffin. Tumor volume was calculated (12) by measuring the section with the largest tumor portion and applying the formula: length x width² x 0.5 (12).

Immunohistochemical (IHC) analysis of tissue. Paraffin-embedded tissues were used to assay the expressions of PCNA (parameter for cell proliferation) and TUNEL (parameter for apoptosis). Tissue sections (4-6 μ m thick) were mounted on silanized glass slides and dried overnight. The sections were deparaffinized in xylene, followed by treatment with a graded series of alcohol [100, 95, and 80% ethanol/ddH₂O (vol/vol)] and rehydrated in PBS (pH 7.5). For PCNA, sections were microwaved 5 min in water. Endogenous peroxidase was blocked by a 5-min treatment in 3% H₂O₂ in methanol for PCNA. For the staining of mouse anti-PCNA clone PC-10 (1:300; Dako Corporation, Carpinteria, CA), slides were treated with primary antibodies in 5% normal horse serum and 1% normal goat serum phosphate buffer solution, then they were incubated at 4°C overnight. Peroxidase-conjugated secondary antibodies were used and visualized by incubating the slides with stable 3,3'-diaminobenzidine (DAB) for 10-20 min. The sections were rinsed with distilled water, counterstained with Gill's hematoxylin for 1 min, and mounted with Universal Mount (Research Genetics, Huntsville, AL). Control samples exposed to secondary antibody alone showed no specific staining. To minimize bias and subjectivity, the data for this assay were recorded by two separate individuals who were both blinded to the identity of the slides. Areas representing true positive staining were then selected. Ten different sections of each slide were scored using 10 different areas in one field. Apoptotic cells were visualized using a commercially available TUNEL kit (Intergen Company, Purchase, NY). Expression of CD31 (parameter for microvessel density) was determined on fresh frozen tissues that were cut into 4 μ m thick sections and mounted on positively charged slides. The slides were stored at -80°C ; sections were fixed in cold acetone for 10 min and then washed twice with PBS for 3 min each time. Detection of PCNA, CD31 and TUNNEL was carried out as described previously (20).

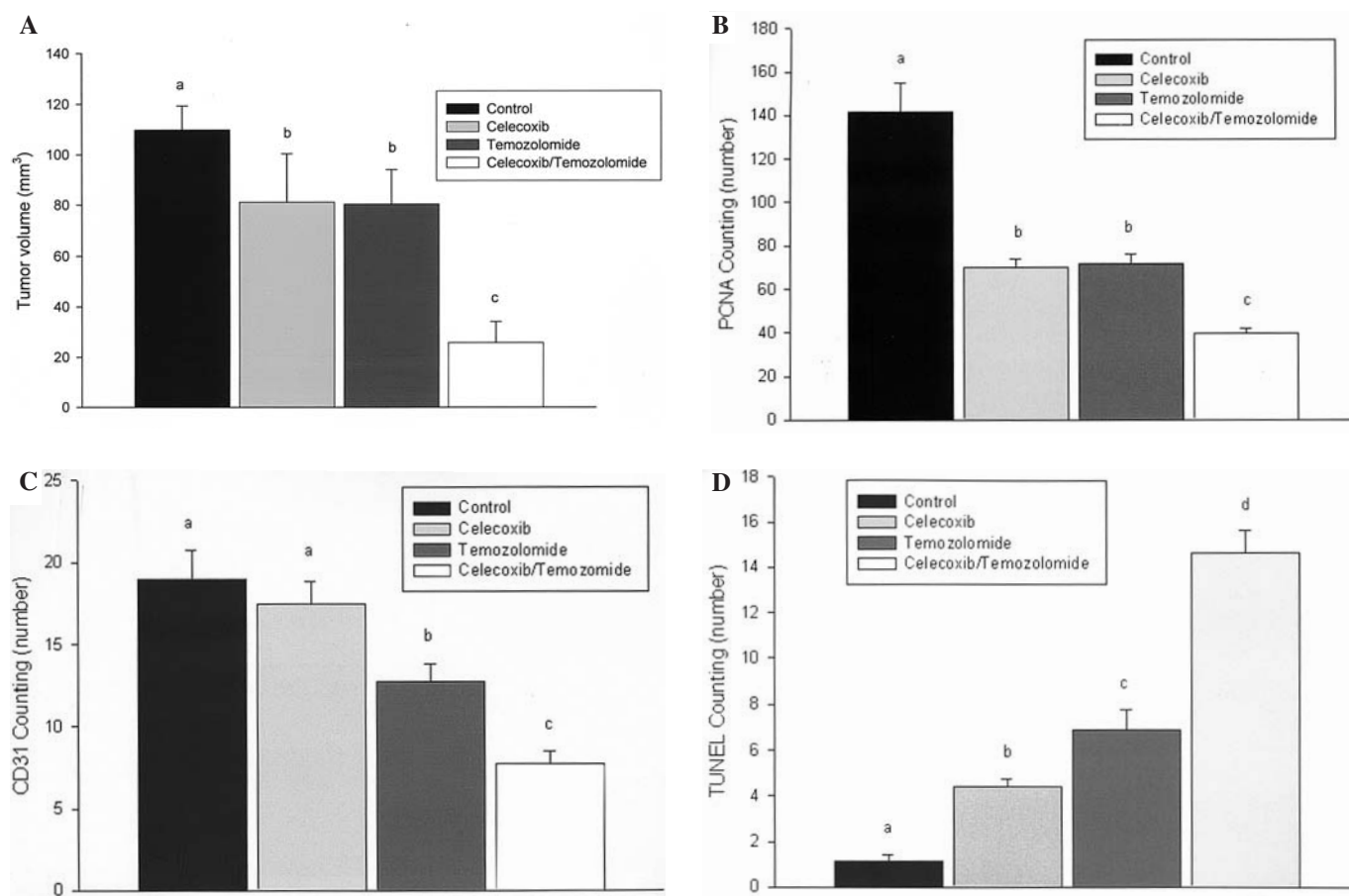


Figure 1. Statistical significance was analyzed by Kruskal-Wallis test among the four-treatment groups (control, celecoxib, temozolomide, and celecoxib/temozolomide combination) and $P < 0.001$. Tumor volume (A) and the number of PCNA (B) and the MVD (C) as well as TUNEL positive cells (D) were compared between the two different treatment groups by the LSD test using ranks for multiple comparisons. The same letters indicate non-significant difference between groups based on the LSD multiple comparison test ($P < 0.05$). PCNA, proliferating cell nuclear antigen; MVD, microvessel density; TUNEL, terminal deoxynucleotidyl transferase-mediated nick end-labeling; LSD, the least significant difference.

Quantification of PCNA, microvessel density (MVD) and TUNEL. PCNA is one of proliferation-related proteins. For the quantification of PCNA expression, the number of positive cells (PCNA⁺) was quantified in 20 random fields at x400 magnification. CD31 is known to be an endothelial cell-related protein. To quantify MVD, 20 random fields at x200 magnification were examined for each tumor, and the microvessels within those fields counted. A single microvessel was defined as a discrete cluster or single cell stained positive CD31 (CD31⁺), and the presence of a lumen was not required for scoring as a microvessel. For the quantification of TUNEL (apoptosis-related protein) expression, the number of positive cells (TUNEL⁺) was quantified in 20 random fields at x400 magnification. For the exact quantification, two individual specialists were involved in counting PCNA⁺ cells, CD31⁺ cells, and TUNEL⁺ cells.

Statistical analysis. Statistical analysis was completed using commercially available software (SPSS version 10.0.7; SPSS Institute, Chicago, IL). Statistical significance was accepted when $P < 0.05$. All measurements are reported as the mean \pm standard deviation (SD). Comparisons of tumor volume, body weight, and PCNA count, TUNEL⁺ cells and MVD among the different treatment groups, were analyzed by Kruskal-Wallis test. Tumor volume and the number of PCNA and TUNEL

positive cells as well the MVD between the two groups were compared by the least significant difference (LSD) test using ranks for multiple comparisons. The synergistic effects of celecoxib and temozolomide were compared by ANOVA test by using contrast.

Results

Inhibition of glioblastoma cell growth in the brain of rats. The C6/LacZ glioma cells were implanted into the caudate nucleus of S-D rats. The rats were randomized into four treatment groups of 10 rats each. The first group received daily saline p.o. and saline i.p. from the 8th to 12th day. The second group received daily p.o. celecoxib (25 mg/kg). The third group received an i.p. injection of temozolomide (7.5 mg/kg) for 5 days after 1 week. The fourth group received daily p.o. celecoxib (25 mg/kg) and i.p. temozolomide (7.5 mg/kg) for 5 days after 1 week. All rats in the control and treatment groups were sacrificed on day 18 because the control rats started to become sick. The data from two independent experiments were very similar and were therefore combined. The data for the effect of these therapies on C6/LacZ glioma cells are summarized in Table I and Fig. 1A.

Celecoxib therapy alone and temozolomide therapy alone was effective in reducing tumor volume. They were statistically

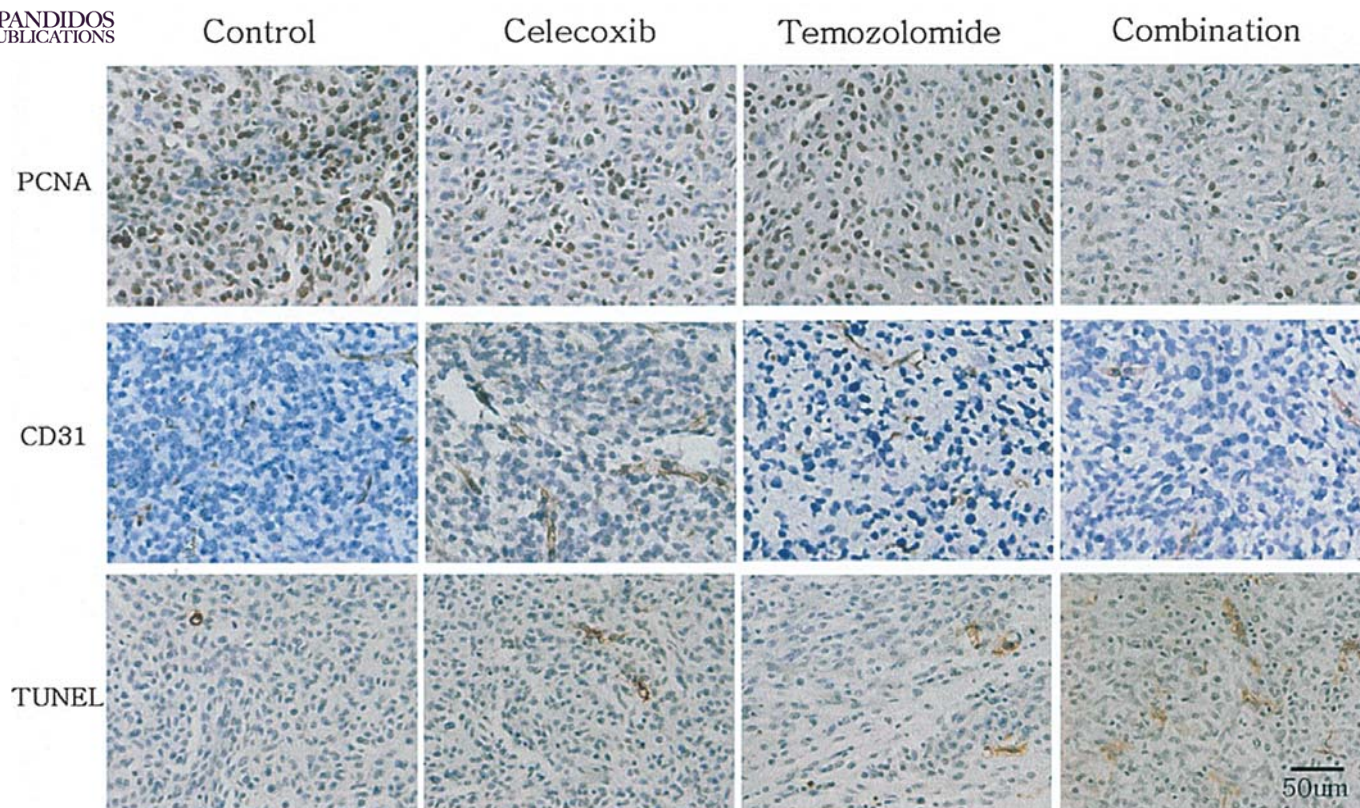


Figure 2. Immunohistochemistry (IHC) of tumors derived from C6/LacZ glioma cell line growing in the brains of rats. Groups of rats were treated with saline, celecoxib, temozolomide, or celecoxib plus temozolomide. Tumors were harvested on day 18 and processed IHC. The first, second, and third rows show representative results of colorimetric IHC analysis for proliferating cell nuclear antigen (PCNA; shown in brown), CD31 (shown in brown), and terminal deoxynucleotidyl transferase-mediated nick end-labeling (TUNEL; shown in brown) for each treatment group in C6/LacZ gliomas. Note the reduction in PCNA⁺ cells and microvessel density as well as increased TUNEL⁺ cells caused by the celecoxib-temozolomide combination treatment.

significant compared with the control therapy ($P<0.05$). Among the celecoxib alone group and temozolomide alone group, there were no significant differences in the tumor volume ($P=0.445$). The combination of celecoxib and temozolomide further reduced tumor volume. This reduction in tumor volume was statistically significant compared with all other therapy ($P<0.01$) although there was no statistically significant synergistic effect of the combination ($P=0.509$). Body weight was maintained in all groups of rats.

IHC analysis. In the next step of experiments, we determined the mechanism responsible for the therapeutic effects of celecoxib plus temozolomide. The immunohistochemical data demonstrate that the inhibition in tumor growth observed in tumors of rats treated with celecoxib alone, temozolomide alone and in combination was accompanied by a reduction in tumor cell proliferation (PCNA count) and induction of apoptosis (TUNEL count) (Table II, Fig. 2). Celecoxib alone (69.9 ± 15.1), temozolomide alone (78.1 ± 16.9), and the combination therapy (39.4 ± 10.8) decreased the number of PCNA⁺ cells in tumors compared with the control (141.6 ± 54.0) ($p<0.001$) (Fig. 1B). There were no significant difference in the number of PCNA⁺ cells between celecoxib and temozolomide alone group ($P=0.888$). PCNA was most significantly reduced from the tumors of control rats receiving both celecoxib and temozolomide ($P<0.001$ versus all other groups) although there was no statistically significant synergistic

effect of the combination ($P=0.807$). MVD (CD31 count) was reduced from the control level (19 ± 9.8) in tumors treated with temozolomide alone (12.7 ± 6.2) ($P<0.01$), but not in celecoxib alone (17 ± 5.9) ($P=0.938$). The most significant reduction was in the combination therapy group, where MVD decreased to 7.7 ± 4.5 ($P<0.001$ versus all groups) (Fig. 1C) and furthermore there was statistically significant synergistic effect of the combination ($P=0.012$). The number of TUNEL⁺ cells increased significantly from 1.2 ± 1.3 in the control group to 4.4 ± 1.4 (celecoxib), 6.9 ± 3.9 (temozolomide), and 14.6 ± 4.0 (combination) ($P<0.001$). There were more TUNEL⁺ cells in the temozolomide group than the celecoxib group ($P<0.05$). Combination therapy significantly increased the number of TUNEL⁺ cells compared with other all groups ($P<0.001$) (Fig. 1D) although there was no statistically significant synergistic effect of the combination ($P=0.955$).

Discussion

Despite aggressive treatments, there has only been slight improvement in the prognosis of glioblastoma using current standard therapeutic approach including operation, radiation therapy, chemotherapy and immunotherapy (21-23).

For glioblastoma, COX-2 overexpression is found in tumors with more malignant histology, and its level of expression correlates with prognosis (11,24,25). The effect of COX-2 inhibitors in preventing malignant progression or delay of

recurrence of malignant glial tumors has not yet been determined. It was reported that high-grade glioma tissues expressed elevated levels of COX-2, when compared with low-grade glioma specimens (11). In a number of cell and animal models, induction of COX-2 has been shown to promote cell growth, inhibit apoptosis, and enhance cell motility and adhesion; however, the mechanisms of these activities are largely unknown (26). Celecoxib is a selective COX-2 inhibitor that has been used extensively in osteoarthritis treatment because of its anti-inflammatory properties. COX-2 is overexpressed in most malignant gliomas, and COX-2 inhibitors have impaired malignant glioma-derived cell line growth *in vitro* and *in vivo* (12,27). Celecoxib has excellent oral bioavailability. Though little toxicity data are available for glioma patients, patients receiving celecoxib as an anti-inflammatory agent have been prone to gastritis and platelet function inhibition. Compared with other anticancer agents, COX-2 inhibitors are relatively safe. Although COX-2 inhibitors are not cytotoxic agents, their known anti-proliferative, proapoptotic, anti-vascular, and anti-invasive effects support their use in the prevention of glioma progression and as a combination treatment with chemotherapy or radiation therapy. Our prior study showed that tumors that highly express COX-2 as well as epidermal growth factor receptor (EGFR) or Akt might respond well to the COX-2 inhibitor celecoxib and treatment of rat gliosarcoma in rat brain with COX-2 inhibitor celecoxib significantly decreased cell growth and increased apoptosis (12). Combination treatment of temozolomide and celecoxib significantly inhibited the tumor volume of C6/LacZ rat glioma cells implanted in the brains of rats and tumor progression more than the single agent (celecoxib or temozolomide) therapy. This result showed that the combination treatment influenced tumor cell biology including proliferation, angiogenesis and apoptosis, which correspond with our earlier study that celecoxib inhibits glioma cell growth which came from the inhibition of cell proliferation and induction of apoptosis. Although there was a reduction of MVD in the celecoxib alone group compared with the control group, it was not a significant difference. However, we found that combination treatment showed a synergistic effect on the reduction of MVD in the C6/LacZ rat orthotopic glioma model. These findings suggested that the celecoxib has anti-angiogenic effect as reported before (28,29).

Temozolomide is an imidazotetrazine derivative that has become one of the most commonly used chemotherapy agents for glioblastoma. Moreover, its antiglioma activity has been demonstrated in several phase II trials (30,31). This study demonstrates that temozolomide inhibited the growth of tumors and was accompanied by a reduction in tumor cell proliferation and induction of apoptosis. Additionally, MVD was decreased compared to the control group indicating antivascular effect in the temozolomide treatment group. This result is similar to the reports by other authors that temozolomide inhibits angiogenesis (32-34).

C6 glioma cell line has been stated originating from brain tumors formed in random bred Wistar-Furth rats (35). Although the origin of the C6 glioma cell line is unclear, this cell line is considered to be a useful experimental model system for the study of glioblastoma growth and the screening for future drug targets and for the development of novel therapies (36).

C6 rat glioma is not a sensitive tumor for the treatment of temozolomide. Even though there was a significant reduction of the tumor, the extent of tumor reduction was <30%. This model is good to evaluate the combination effect of celecoxib and temozolomide because of the tumor's relative chemoresistance to temozolomide. In our study with temozolomide, C6 rat glioma became more sensitive with combination of celecoxib.

In our study, celecoxib and temozolomide had more effect on the tumor volume, cell proliferation, and apoptosis; although there was no synergism. The combination has synergistic effect on the MVD. The synergistic effect of combination treatment on the MVD indicates that the glioblastomas, which have the most prominent endothelial cell proliferation as well as Cox-2 expression, may be effective to the combination treatment. Early results from a small phase I trial that combined celecoxib and temozolomide for the treatment of malignant gliomas has been published (Pannullo S, *et al*, Proc Am Soc Clin Oncol 22: abs. 114, 2003) and recently, phase II trials have been initiated in some centers, including our own.

According to our data, when Cox-2 inhibitors are used in glioblastoma patients, MVD and expression of Cox-2 can be a good parameter of combination treatment. A metronomic antiangiogenic chemotherapeutic protocol might be a good strategy with which to combine the Cox-2 inhibitors. However, more research remains to be done on the exact antiglioma mechanism of this combination and further detailed studies should be made in a large number of patients.

Acknowledgements

The present study was supported by the Samsung grant, #SBRI (CA42081) and the Sungkyunkwan University School of Medicine and In-Sung Foundation for Medical Research (C-A4-826-1). We thank Sun Woo Kim, for her expert advice in the statistical work of this study and we thank Mi-Hyun Kim, Mi Ryung Song and Jin Hyun Prak for their animal care and immunostaining work, and also thank Meen Jong Lee, Hyun Jeong Lim and Hee Jin Bae for editing the report.

References

1. Sawaya R, Hammoud M, Schoppa D, Hess KR, Wu SZ, Shi WM and Wildrick DM: Neurosurgical outcomes in a modern series of 400 craniotomies for treatment of parenchymal tumors. *Neurosurgery* 42: 1044-1055, 1998.
2. Lacroix M, Abi-Said D, Fourney DR, Gokaslan ZL, Shi W, DeMonte F, Lang FF, McCutcheon IE, Hassenbusch SJ, Holland E, Hess K, Michael C, Miller D and Sawaya R: A multivariate analysis of 416 patients with glioblastoma multiforme: prognosis, extent of resection, and survival. *J Neurosurg* 95: 190-198, 2001.
3. Jeremic B, Milicic B, Grujicic D, Dagovic A, Aleksandrovic J and Nikolic N: Clinical prognostic factors in patients with malignant glioma treated with combined modality approach. *Am J Clin Oncol* 27: 195-204, 2004.
4. Laperriere N, Zuraw L and Cairncross G: Radiotherapy for newly diagnosed malignant glioma in adults: a systematic review. *Radiother Oncol* 64: 259-273, 2002.
5. Fine HA, Dear KB, Loeffler JS, Black PM and Canellos GP: Meta-analysis of radiation therapy with and without adjuvant chemotherapy for malignant gliomas in adults. *Cancer* 71: 2585-2597, 1993.
6. Stewart LA: Chemotherapy in adult high-grade glioma: a systematic review and meta-analysis of individual patient data from 12 randomised trials. *Lancet* 359: 1011-1018, 2002.



ROSS JG, Ueki K, Zlatescu MC, Lisle DK, Finkelstein DM, and RR, Silver JS, Stark PC, Macdonald DR, Ino Y,

8. Newlands ES, Stevens MF, Wedge SR, Wheelhouse RT and Brock C: Temozolomide: a review of its discovery, chemical properties, pre-clinical development and clinical trials. *Cancer Treat Rev* 23: 35-61, 1997.
9. Tentori L, Leonetti C and Aquino A: Temozolomide reduces the metastatic potential of Lewis lung carcinoma (3LL) in mice: role of alpha-6 integrin phosphorylation. *Eur J Cancer* 31A: 746-754, 1995.
10. Giglio P and Levin V: Cyclooxygenase-2 inhibitors in glioma therapy. *Am J Ther* 11: 141-143, 2004.
11. Joki T, Heese O, Nikas DC, Bello L, Zhang J, Kraeft SK, Seyfried NT, Abe T, Chen LB, Carroll RS and Black PM: Expression of cyclooxygenase 2 (COX-2) in human glioma and *in vitro* inhibition by a specific COX-2 inhibitor, NS-398. *Cancer Res* 60: 4926-4931, 2000.
12. Nam DH, Park K, Park C, Im YH, Kim MH, Lee S, Hong SC, Shin HJ, Kim JH, Eoh W and McDonnell TJ: Intracranial inhibition of glioma cell growth by cyclooxygenase-2 inhibitor celecoxib. *Oncol Rep* 11: 263-268, 2004.
13. Parney IF and Chang SM: Current chemotherapy for glioblastoma. *Cancer J* 9: 149-156, 2003.
14. Dillman RO, Shea WM, Tai DF, Mahdavi K, Barth NM, Kharkar BR, Poor MM, Church CK and DePriest C: Interferon-alpha2a and 13-cis-retinoic acid with radiation treatment for high-grade glioma. *Neurooncology* 3: 35-41, 2001.
15. Brandes AA, Ermani M, Turazzi S, Scelzi E, Berti F, Amista P, Rotilio A, Licata C and Fiorentino MV: Procarbazine and high-dose tamoxifen as a second-line regimen in recurrent high-grade gliomas: a phase II study. *J Clin Oncol* 17: 645-650, 1999.
16. Napolitano M, Keime-Guibert F, Monjour A, Lafitte C, Ameri A, Cornu P, Broet P and Delattre JY: Treatment of supratentorial glioblastoma multiforme with radiotherapy and a combination of BCNU and tamoxifen: a phase II study. *J Neurooncol* 45: 229-235, 1999.
17. Cha S, Knopp EA, Johnson G, Litt A, Glass J, Gruber ML, Lu S and Zagzag D: Dynamic contrast-enhanced T2-weighted MR imaging of recurrent malignant gliomas treated with thalidomide and carboplatin. *Am J Neuroradiol* 21: 881-890, 2000.
18. Lal S, Lacroix M, Tofilon P, Fuller GN, Sawaya R and Lang FF: An implantable guide-screw system for brain tumor studies in small animals. *J Neurosurg* 92: 326-333, 2000.
19. Kobayashi N, Allen N, Clendenon NR and Ko LW: An improved rat brain-tumor model. *J Neurosurg* 53: 808-815, 1980.
20. Kim SJ, Uehara H, Karashima T, Shepherd DL, Killion JJ and Fidler IJ: Blockade of epidermal growth factor receptor signaling in tumor cells and tumor-associated endothelial cells for therapy of androgen-independent human prostate cancer growing in the bone of nude mice. *Clin Cancer Res* 9: 1200-1210, 2003.
21. Hayes RL, Arbit E, Odaimi M, Pannullo S, Scheff R, Kravchinskiy D and Zaroulis C: Adoptive cellular immunotherapy for the treatment of malignant gliomas. *Crit Rev Oncol Hematol* 39: 31-42, 2001.
22. Huang Y, Hayes RL, Wertheim S, Arbit E and Scheff R: Treatment of refractory recurrent malignant glioma with adoptive cellular immunotherapy: a case report. *Crit Rev Oncol Hematol* 39: 17-23, 2001.
23. Kang SG, Ryu CH, Jeun SS, Park CK, Shin HJ, Kim JH, Kim MC and Kang JK: Lymphokine activated killer cells from umbilical cord blood show higher antitumor effect against anaplastic astrocytoma cell line (U87) and medulloblastoma cell line (TE671) than lymphokine activated killer cells from peripheral blood. *Child Nerv Syst* 20: 154-162, 2004.
24. Shono T, Tofilon PJ, Bruner JM, Owolabi O and Lang FF: Cyclooxygenase-2 expression in human gliomas: prognostic significance and molecular correlations. *Cancer Res* 61: 4375-4381, 2001.
25. Prayson RA, Castilla EA, Vogelbaum MA and Barnett GH: Cyclooxygenase-2 (COX-2) expression by immunohistochemistry in glioblastoma multiforme. *Ann Diagn Pathol* 6: 148-153, 2002.
26. Cao Y and Prescott SM: Many actions of cyclooxygenase-2 in cellular dynamics and in cancer. *J Cell Physiol* 190: 279-286, 2002.
27. Kardosh A, Blumenthal M, Wang WJ, Schonthal AH and Chen TC: Differential effects of selective COX-2 inhibitors on cell cycle regulation and proliferation of glioblastoma cell lines. *Cancer Biol Ther* 3: 55-62, 2004.
28. Gately S and Kerbel R: Therapeutic potential of selective cyclooxygenase-2 inhibitors in the management of tumor angiogenesis. *Prog Exp Tumor Res* 37: 179-192, 2003.
29. Ruegg C, Dormond O and Mariotti A: Endothelial cell integrins and COX-2: mediators and therapeutic targets of tumor angiogenesis. *Biochim Biophys Acta* 1654: 51-67, 2004.
30. Yung WK: Temozolomide in malignant gliomas. *Semin Oncol* 27: 27-34, 2000.
31. Yung WK, Albright RE, Olson J, Fredericks R, Fink K, Prados MD, Brada M, Spence A, Hohl RJ, Shapiro W, Glantz M, Greenberg H, Selker RG, Vick NA, Rampling R, Friedman H, Phillips P, Bruner J, Yue N, Osoba D, Zaknoen S and Levin VA: A phase II study of temozolomide vs. procarbazine in patients with glioblastoma multiforme at first relapse. *Br J Cancer* 83: 588-593, 2000.
32. Kurzen H, Schmitt S, Naher H and Mohler T: Inhibition of angiogenesis by non-toxic doses of temozolomide. *Anticancer Drugs* 14: 515-522, 2003.
33. Tang S, Gao Y and Ware JA: Enhancement of endothelial cell migration and *in vitro* tube formation by TAP20, a novel beta 5 integrin-modulating, PKC theta-dependent protein. *J Cell Biol* 147: 1073-1084, 1999.
34. Glikli G, Abu-Ghazaleh R, Jezequel S, Wheeler-Jones C and Zachary I: Vascular endothelial growth factor-induced prostacyclin production is mediated by a protein kinase C (PKC)-dependent activation of extracellular signal-regulated protein kinases 1 and 2 involving PKC-delta and by mobilization of intracellular Ca²⁺. *Biochem J* 353: 503-512, 2001.
35. Beutler AS, Banck MS, Wedekind D and Hedrich HJ: Tumor gene therapy made easy: allogeneic major histocompatibility complex in the C6 rat glioma model. *Hum Gene Ther* 10: 95-101, 1999.
36. Grobbs B, De Deyn PP and Slegers H: Rat C6 glioma as experimental model system for the study of glioblastoma growth and invasion. *Cell Tissue Res* 310: 257-270, 2002.