



## Chinese medicine *Angelica Sinensis* suppresses radiation-induced expression of TNF- $\alpha$ and TGF- $\beta$ 1 in mice

CONG-HUA XIE\*, MING-SHENG ZHANG\*, YUN-FENG ZHOU\*\*, GUANG HAN, ZHEN CAO, FU-XIANG ZHOU, GONG ZHANG, ZHI-GUO LUO, JIAN-PING WU, HUI LIU, JI CHEN and WEN JIE ZHANG\*\*

Department of Cancer Radio-Chemotherapy, Wuhan University Zhongnan Hospital and Cancer Research Center, Wuhan, Hubei 430071, P.R. China

Received December 1, 2005; Accepted January 19, 2006

**Abstract.** Radiotherapy of thoracic cancer often causes pulmonary inflammation leading to pneumonitis and fibrosis. We favor the hypothesis that cytokine-mediated multicellular interactions may result in the overexpression of proinflammatory cytokines such as TNF- $\alpha$  and TGF- $\beta$ 1, which promotes progressive radiation-induced lung injury. The root of *Angelica Sinensis*, known as 'Danggui' in Chinese medicine, is widely used to treat radiation-induced pneumonitis in humans and shows clinical efficacy and low/no toxicity with an unclear mechanism. Using quantitative RT-PCR and immunohistochemistry (IHC) methods, we investigated radiation-induced lung injury in a mouse model. C57BL/6 mice were assigned to 4 groups: no treatment (NT), *Angelica Sinensis* treatment only (AS), X-ray irradiation only (XRT, single fraction of 12 Gy irradiation to the thoraces) and AS treatment plus XRT (AS/XRT). Mice in NT and AS groups exhibited low TNF- $\alpha$  and TGF- $\beta$ 1 mRNA levels and few positive cell counts for TNF- $\alpha$  (8-17 cells per field,  $\times$ 400 magnification) and TGF- $\beta$ 1 (9-31 cells per field), respectively. In XRT mice, there were increased inflammatory cells positive for TNF- $\alpha$  and TGF- $\beta$ 1 in lung tissue compared with NT mice ( $P < 0.01$ ). However, when XRT mice received AS treatment (AS/XRT), the number of inflammatory cells in lung tissue positive for both TNF- $\alpha$  and TGF- $\beta$ 1 was decreased compared with XRT-only mice ( $P < 0.01$ ) accompanied by moderately decreased mRNA levels of TNF- $\alpha$  and TGF- $\beta$ 1. We conclude that radiation induces expression of TNF- $\alpha$  and TGF- $\beta$ 1 in the inflammatory cells of irradiated lung tissue during the pneumonic phase. The predominant localization of TNF- $\alpha$  and TGF- $\beta$ 1 in inflam-

matory cell infiltrates suggests these cytokines' involvement in the process of radiation-induced pneumonitis. Moreover, effective down-regulation of TNF- $\alpha$  and TGF- $\beta$ 1 in irradiated lung tissue by *Angelica Sinensis* is, at least in part, indicative of its clinical efficacy in treating radiation-induced pneumonitis.

### Introduction

The lung is a major organ targeted by radiation in cancer radiotherapy of the thoracic region and often suffers from radiation-induced injury such as pneumonitis and excessive fibrosis. Radiation-induced lung injury progresses in three phases with distinct histological changes (1). Radiation-induced initial injury or early phase occurs over the first month causing damage to pneumocytes and endothelial cells, which release surfactant and exudate into the alveoli resulting in interstitial edema. Second phase may last from one to several months, termed as acute pneumonitis phase, which is characterized by a sustained inflammatory response with accumulated leukocytes, plasma cells, macrophages, fibroblasts and collagen fibers causing capillary obstruction. Third phase or fibrotic phase usually starts from 6 months after radiation when fibrosis develops together with loss of capillaries, thickened alveolar septa and obliteration of the alveolar space. It is generally accepted that lung fibrosis is a result of the repair process following the acute alveolitis response known as classic radiation pneumonitis.

Although there have been ample published studies attempting to elucidate the mechanisms leading to pneumonitis and pulmonary fibrosis, the pathogenesis of radiation-induced lung injury at cellular and molecular levels is not totally understood. New evidence suggests that tissue repair and fibrosis are largely due to the release of biological mediators which can activate many signal transduction pathways (2). These can happen within hours or days after radiation, initiating and sustaining the fibrogenic process (2-7), and continue for weeks or months.

TNF- $\alpha$  is regarded as a key cytokine involved in the pathogenesis of radiation pneumonitis. TNF- $\alpha$  induces the expression of adhesion molecules which subsequently recruit leukocytes into the sites of inflammation, primes leukocytes to produce oxidants, and promotes the production of prostaglandins and other inflammatory mediators (8). In addition, TNF- $\alpha$  exerts fibrogenic effects by stimulating the growth of fibroblasts and increasing the collagen deposition (9). Previous studies have

---

*Correspondence to:* Dr Yun-Feng Zhou, Department of Radio-chemotherapy, Zhongnan Hospital, Wuhan University, 169 Dong Hu Road, Wuhan, Hubei 430071, P.R. China  
E-mail: chxie\_65@hotmail.com

\*Contributed equally

\*\*Shared senior authorship

*Key words:* *Angelica Sinensis*, pneumonitis, radiation, TNF- $\alpha$ , TGF- $\beta$ 1

indicated an involvement of TNF- $\alpha$  in the pathogenesis of radiation-induced pneumonitis (10,11).

TGF- $\beta$ 1 has been found to be a major mediator responsible for tissue damage under a variety of conditions, including chemotherapy and radiotherapy, in which excessive fibrosis occurs (12-14). TGF- $\beta$ 1 is autoinductive and chemotactic to monocytes, macrophages and fibroblasts and capable of causing them to migrate to sites of tissue damage (15). TGF- $\beta$ 1 may also promote fibroblasts to proliferate (15-19) and stimulate cellular production of collagen and fibronectin (17,19,20). Furthermore, TGF- $\beta$ 1 stimulates the production of connective tissue and simultaneously limits its breakdown, leading connective tissue to maturation (21). Recent investigations have suggested that TGF- $\beta$ 1 may be involved in the pathogenesis of radiation-induced pneumonitis (10,11).

Because of the pathological significance of TNF- $\alpha$  and TGF- $\beta$ 1 in radiation-induced lung injury, any pharmacological intervention that may down-regulate or inhibit the expression of these proinflammatory cytokines should explore the mechanism(s) as well as define an effective treatment for radiation-induced pneumonitis.

The root of *Angelica Sinensis* (AS), known as 'Danggui' in Chinese, is a traditional Chinese medicine that has been widely used in China for gynecological diseases with a long history (22). Chemical and pharmacological studies of extracts or compounds purified from AS root have found them to increase myocardial blood flow and reduce radiation-induced damage in humans (23-25). In recent years, AS has been used in treating cancer patients with radiation-induced pneumonitis as an empirical practice based on the theory of Chinese medicine, and has shown clinical efficacy with low/no toxicity (26). However, the underlying mechanism(s) are not known as to why AS is effective in treating radiation-induced pneumonitis.

In this study, we have investigated radiation-induced pneumonitis in a mouse model and show that *Angelica Sinensis* is able to down-regulate the levels of both proinflammatory cytokines, TNF- $\alpha$  and TGF- $\beta$ 1, with attenuated histopathology in otherwise severe radiation-induced pneumonitis.

## Materials and methods

**Mice.** C57BL/6 mice were purchased from Sino-British Sippr/BK Laboratory Animals Ltd. (Shanghai, P.R. China). Eight-week old female mice (approximately 20 g each) were divided into 4 study groups: i) no treatment (NT, 9 mice); ii) *Angelica Sinensis* treatment (AS, 9 mice); iii) radiation group (XRT, 27 mice); and iv) *Angelica Sinensis* treatment plus radiation (AS/XRT, 27 mice). *Angelica Sinensis* extract (25%, pharmaceutical reagent for human use provided by Zhongnan Hospital, Wuhan University College of Medicine, Wuhan, P.R. China) was administered intraperitoneally (i.p., 0.2 ml/10 g/day) in a single injection. In AS and AS/XRT group, *Angelica Sinensis* injection was initiated one week before thoracic irradiation and continued up to two weeks after irradiation. As a control, mice in other groups received the same volume of 0.9% sodium chloride using the same method.

**Radiation schedule.** Mice in XRT and AS/XRT groups underwent  $\gamma$ -irradiation while mice in other groups (NT and AS groups) did not. A dose of 12 Gy to the midplane of the lungs

was given in a single fraction via a posterior field using a linear accelerator (Simens, Primus-Hi, Germany). A plastic jig was used to restrain the mice without anesthesia and lead blocks were placed to shield the head and abdomen. The irradiation specifics were: beam energy, 6 MV-photons; dose-rate, 2.0 Gy/min; source surface distance (SSD), 1 m; size of radiation field, 10x10 cm. A source film was taken to ensure full exposure of the lung. Film dosimetry was used to deduce relative dose distribution. Following irradiation, mice in all 4 groups were maintained in specific pathogen-free (SPF) environment and supplied with standard diet and water.

**Tissue isolation.** Mice were sacrificed by cervical dislocation at time-points corresponding to latency period (1, 24, 72 h and 1 week post-irradiation), pneumonic phase (2, 4, 8 and 16 weeks post-irradiation), and the beginning of fibrotic phase (24 weeks post-irradiation), respectively. Lungs were immediately removed after death without perfusion. Left lobes were fixed in 10% neutral buffered formalin for histological and histochemical analyses. Right lobes were quickly frozen in liquid nitrogen until RNA isolation.

**Histology.** Paraffin-embedded tissue was sectioned at an average thickness of 5  $\mu$ m, stained using haematoxylin and eosin as well as Masson stain for collagen.

**Immunohistochemistry (IHC).** Streptavidin-peroxidase methodology was used for quantifying TNF- $\alpha$  and TGF- $\beta$ 1 protein expression. Tissue dewaxing in xylene and rehydration in graded alcohol were performed according to the manufacturer's protocol. Anti-mouse TNF- $\alpha$  and TGF- $\beta$ 1 antibodies were purchased from Santa Cruz Biotechnology (CA, USA) and goat anti-rabbit secondary antibody was from Maixin biotechnology (Fuzhou, P.R. China). A standardized scoring procedure was established and IHC slides were subjected to blinded evaluation by two investigators. After examining the whole lung section and estimating the extent of altered lung parenchyma, 10 representative fields (x400 magnification), non-contiguous and non-overlapping fields were selected and analyzed. After initial qualitative assessment of morphologic changes, types of cells positive for TNF- $\alpha$  and TGF- $\beta$ 1 antibody staining were recorded. Positive cells from 10 non-contiguous and non-overlapping fields (x400 magnification) were used to calculate arithmetic means and expressed as an average number of cells per field.

**RNA extraction.** Total RNA preparations were performed using TRIzol reagent (Invitrogen, Carlsbad, CA, USA). Briefly, lung tissue (equivalent to 100 mg) was homogenized in 1.2 ml TRIzol reagent and tissue lysates were kept at -80°C prior to processing or used immediately after following procedures indicated in the manufacturer's protocol. RNA concentrations were determined by spectrophotometry. RNA integrity was assessed using denaturing agarose gel electrophoresis.

**cDNA synthesis.** First-strand cDNA was synthesized using SuperScript™ First-Strand Synthesis System for RT-PCR (Invitrogen) according to the manufacturer's protocol. Oligo(dT) 12-18 primers were used for generating first-strand cDNA in a final reaction mix of 20  $\mu$ l.



SPANDIDOS primer and probe sequences for murine TNF- $\alpha$ , TGF- $\beta$ 1 and GAPDH.

Name		Sequence (5'→3')	Amplicon length (bp)
TNF- $\alpha$	FW	CATCTTCTCAA AATTTCGAGTGACAA	
TNF- $\alpha$	RV	TGGGAGTAGACAAGGTACAACCC	175
TNF- $\alpha$	FP	CACGTCGTAGCAAACCACCAAGTGGA	
TGF- $\beta$ 1	FW	TGACGTC ACTGGAGTTGTACGG	
TGF- $\beta$ 1	RV	GGTTCATGTCATGGATGGTGC	170
TGF- $\beta$ 1	FP	TTCAGCGCTCACTGCTCTTGTGACAG	
GAPDH	FW	TCACCACCATGGAGAAGGC	
GAPDH	RV	GCTAAGCAGTTGGTGGTGCA	168
GAPDH	FP	ATGCCCCCATGTTTGTGATGGGTGT	

Forward (FW) and reverse (RV) primers were always located in different exons. Fluorogenic probes (FP) are FAM-labelled at the 5'-end and TAMRA-labelled at the 3'-end.

**Real-time quantitative reverse transcriptase PCR (RT-PCR).** Real-time quantitative RT-PCR was performed based on previous reports (27,28) with modifications. PCR primers and probes for murine TNF- $\alpha$ , TGF- $\beta$ 1 and housekeeping gene GAPDH were designed by CASarray Co., Ltd. (Shanghai, P.R. China) based on cDNA sequences obtained from GenBank database (Table I). RT-PCR amplifications were performed using LightCycle-FastStart DNA Master Hybridization Probes kit (Roche, Basel, Switzerland) on the Rotor-Gene sequence detector (Corbett Research, Sydney, Australia) in a total volume of 50  $\mu$ l containing 2  $\mu$ l cDNA, 1.25 units TaqDNA Polymerase, 2.5 mM MgCl<sub>2</sub>, 200  $\mu$ M of dNTPs, 300 nM of primers and 200 nM of relevant detection probes. After initial denaturing at 95°C for 2 min, 40 PCR cycles were performed at 95°C for 20 sec, 55°C for 40 sec and 65°C for 40 sec. For reproducibility within and between PCR amplifications, we established standard normal cDNA as a base expression, which was placed in each PCR amplification. Relative mRNA expression of test cDNA samples was referenced to the standard cDNA and expressed as fold change of test mRNA over base mRNA. For example, relevant mRNA expression (E)=[mRNA<sub>test</sub>/GAPDH<sub>test</sub>]/[mRNA<sub>base</sub>/GAPDH<sub>base</sub>].

**Statistical analyses.** Statistical analyses were performed using the Mann-Whitney U test contained in the SPSS software package (version 11.0) for Windows 98 and difference was regarded significant if P<0.05.

## Results

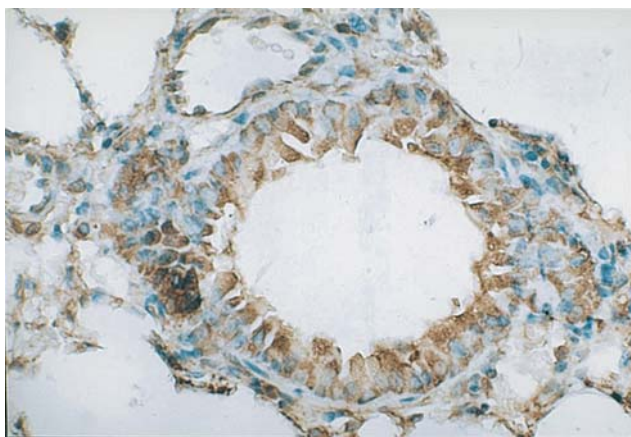
**Histology.** Histopathological alterations of radiation-induced lung injury in our experimental mice included macrophage infiltration in air spaces; edema in the alveolar wall and/or air spaces; desquamation of epithelial cells from the alveolar walls; thickening of the alveoli septa by infiltration of inflammatory cells; collagen deposition, progressive fibrosis of alveolar septa; and obliteration of the alveoli, in keeping with previous reports. In this strain of mice, protein-rich edema and hyalin membranes were typical features of radiation-induced injury. In addition, focal fibrosis developed within

inflammatory fields, between 16 and 24 weeks post-irradiation. In contrast, non-irradiated murine lungs obtained from the same period of time showed no evidence of pulmonary inflammation or other significant histopathological changes.

**Immunohistochemistry.** Staining patterns of TNF- $\alpha$  in lung tissue. At 1 h after thoracic irradiation, the bronchiolar epithelium in the lung tissue of irradiated mice revealed an intense and homogenous staining for TNF- $\alpha$ , and 80-90% epithelial cells were intensely stained (Fig. 1). In contrast, the bronchiolar epithelium revealed a variable staining intensity for TNF- $\alpha$  at later time-points. No clear time-dependent alterations were observed in terms of the number of stained epithelial cells (between 10 and 80%). In the first hours after thoracic irradiation (24 h post-irradiation), TNF- $\alpha$  antibody stained the endothelial cells whereas, in early pneumonic phase (2 and 4 weeks post-irradiation), only weak staining of the vascular endothelium was observed. During later time-points of the pneumonic phase (8, 16 and 24 weeks post-irradiation), the endothelium did not react with TNF- $\alpha$  antibody. At 72 h post-irradiation, the medial smooth muscle cells were positive for TNF- $\alpha$  and remained positive (with variable staining intensity) until 24 weeks post-irradiation. During the stage of interstitial pneumonitis, microscopic examination of lung tissue revealed inflammation with accumulation of positive inflammatory cells, particularly in perivascular and peribronchial areas, as well as in the subpleural region. The lung parenchyma revealed a pronounced increase of positive alveolar macrophages. Other cell types of the lung parenchyma, such as type I and II pneumocytes or fibroblasts, did not stain for TNF- $\alpha$ . Increased cytokine expression was detected predominantly in regions of histopathological radiation injury; inflammatory lesions, in particular, showed detectable levels of TNF- $\alpha$ . In contrast, no significant immunoreactivity was observed in areas of normal lung tissue.

**Staining patterns of TGF- $\beta$ 1 in lung tissue.** In the initial hours after thoracic irradiation, the lung parenchyma had already revealed a pronounced increase of TGF- $\beta$ 1-positive alveolar macrophages. In addition, single positive cells in the septal

## XRT



## NT

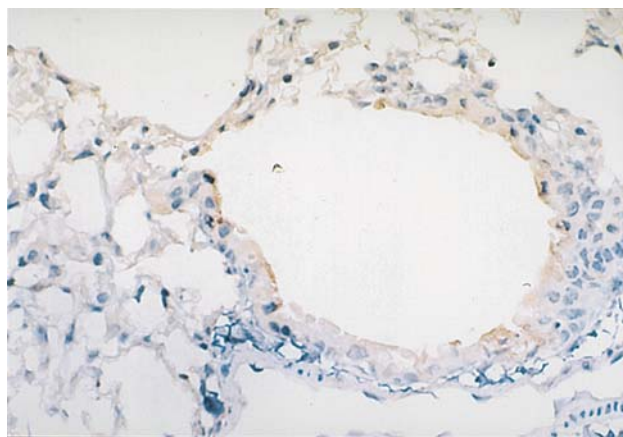


Figure 1. One hour after thoracic irradiation, the bronchiolar epithelium in irradiated lung tissue was significantly different between the XRT group and the NT group. In the XRT group, mice revealed intense and homogenous staining for TNF- $\alpha$ , (x400 magnification). However, the bronchiolar epithelium in the lung tissue of NT mice revealed weak staining for TNF- $\alpha$ , (x400 magnification).

walls could be identified as type II pneumocytes. Thus, staining related to alveolar macrophages was the most characteristic finding in specimens obtained in the first period after radiation exposure. The most striking increase in TGF- $\beta$ 1 immunoreactivity was seen at the beginning of the pneumonic phase (2 and 4 weeks post-irradiation). Microscopic examination of the lungs revealed tissue inflammation with accumulation of inflammatory cells in the alveolar spaces and interstitium, particularly in perivascular and peribronchial areas, but extending widely throughout the parenchyma until the pleural surface. The alveolar septa were expanded by infiltrated inflammatory cells but the general tissue architecture was maintained. Increased cytokine expression was detected prominently in regions of histopathological radiation injury. During later time-points (8, 16 and 24 weeks post-irradiation), type II pneumocytes and fibroblasts served as important sources of TGF- $\beta$ 1 expression. By week 24, there was evidence of interstitial fibrosis with accumulation of fibroblasts, deposition of collagen and, consequently, destruction of normal tissue architecture. Deposition of disorganized collagen and elastic fibers was evident on Masson stain. The bronchiolar epithelium revealed variable staining intensity for TGF- $\beta$ 1. Between 30 and 90% of epithelial cells were brightly stained with TGF- $\beta$ 1 antibody. No clear time-dependent alteration in the number of stained epithelial cells was observed. The endothelial lining of blood vessels displayed TGF- $\beta$ 1 immunoreactivity as a function of time after radiation exposure. TGF- $\beta$ 1 antibody intensely stained the endothelial cells for hours to days after irradiation (from 24 h to 1 week) whereas, during the intermediate phase (2, 4 and 8 weeks post-irradiation), the endothelium did not react with TGF- $\beta$ 1. In the late phase (16 and 24 weeks post-irradiation), weak staining of the vascular endothelium was observed. The connective tissue and extracellular matrix were not labeled by TGF- $\beta$ 1 antibody.

Normal non-irradiated lung tissue exhibited non-homogeneous and variable TNF- $\alpha$  immunoreactivity in the bronchiolar epithelium (Fig. 1). In the lung parenchyma, only a few alveolar macrophages stained positive. In the walls of untreated blood vessels, TNF- $\alpha$  was not detected immunohistochemically. Unirradiated lung tissue exhibited TGF- $\beta$ 1

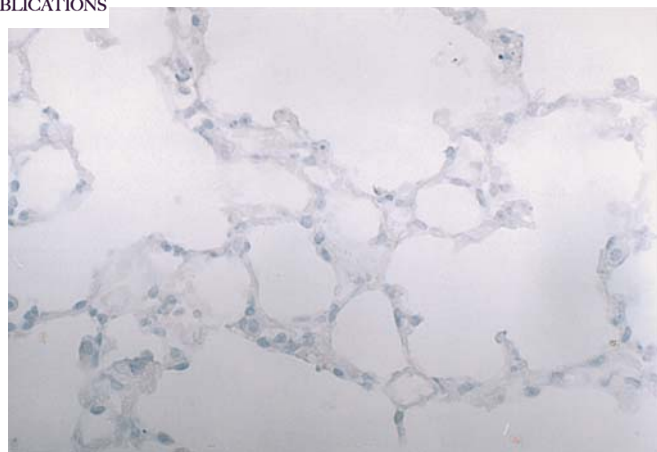
immunoreactivity in bronchiolar epithelium. In lung parenchyma, a very low number of alveolar macrophages stained positive. Vascular endothelium and *muscularis propria* did not stain positive for TGF- $\beta$ 1.

**Differences between experimental groups.** Non-irradiated groups (NT and AS) exhibited low levels of TNF- $\alpha$  protein expression with positive cell counts between 8 and 17 and low levels of TGF- $\beta$ 1 protein expression with positive cell counts between 9 and 31. There were significantly higher counts of TNF- $\alpha$ - and TGF- $\beta$ 1-positive inflammatory cells in the XRT group ( $P < 0.01$ ). The number of TNF- $\alpha$ - and TGF- $\beta$ 1-positive cells in the AS/XRT group is between those of the non-irradiated groups (NT and AS) and the radiation-only group (XRT), and the differences between the AS/XRT group and the XRT group were significant ( $P < 0.01$ ) (Figs. 2-4).

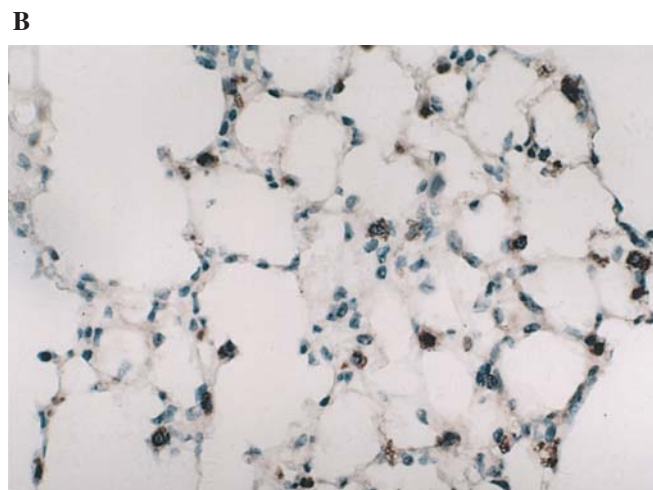
**RT-PCR analyses.** Real-time quantitative RT-PCR showed that the relative mRNA expression of cytokines TNF- $\alpha$  and TGF- $\beta$ 1 was significantly higher in the XRT group than in non-irradiated groups ( $P < 0.01$ ). It was interesting to note that irradiated mice treated with *Angelica Sinensis* showed only mild TNF- $\alpha$  and TGF- $\beta$ 1 responses compared with those exposed to radiation alone (XRT group). Overall, such differences were not statistically significant ( $P = 0.078$  for TNF- $\alpha$  and  $P = 0.054$  for TGF- $\beta$ 1). However, when data were analyzed for individual time-points, differences in TNF- $\alpha$  expression between the AS/XRT and XRT-only groups were revealed at 1 h, 8, 16 and 24 weeks post-irradiation, respectively ( $P < 0.01$ ) (Fig. 5). The same was also true for TGF- $\beta$ 1 expression at time-points of 4, 8 and 16 weeks, respectively ( $P < 0.01$ ) (Fig. 6). These results in our mouse model suggested that *Angelica Sinensis* played a down-regulatory role in radiation-induced lung inflammation in a time-dependent manner.

## Discussion

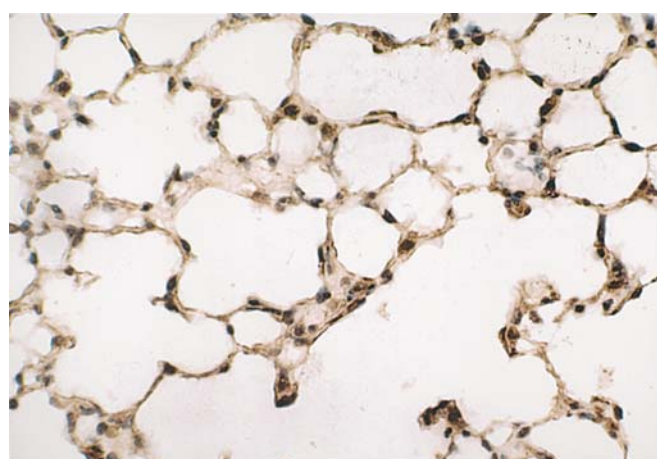
Radiation-induced pneumonitis is a particularly prominent problem for the lung in thoracic radiotherapy. Because the mechanism of radiation-induced pneumonitis is largely



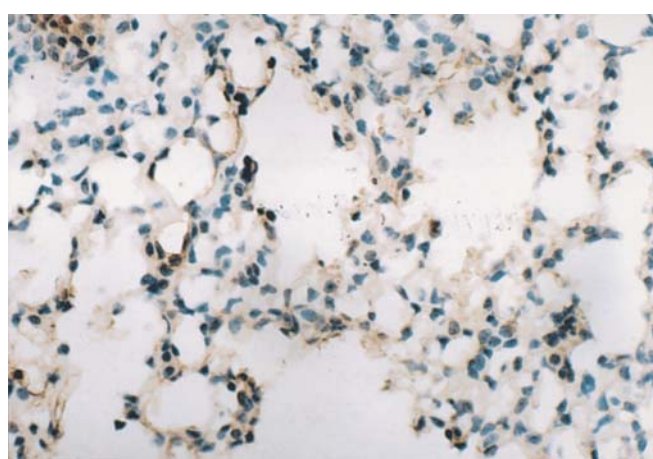
C



D



E



F

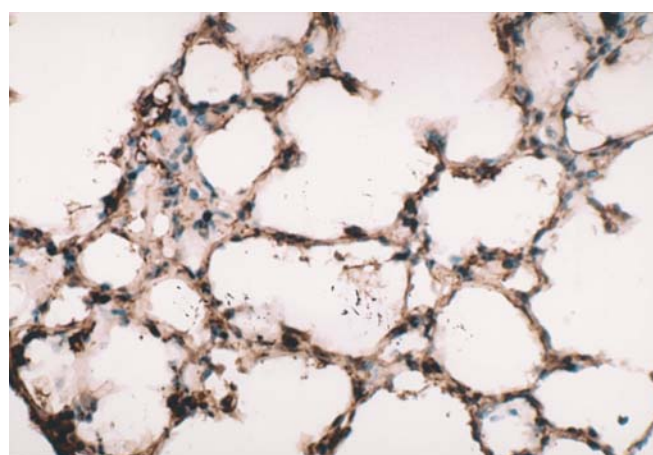
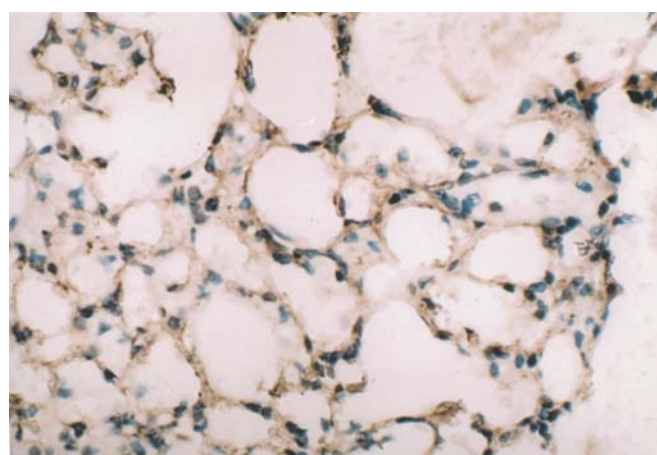


Figure 2. Differences in IHC stains are revealed for TNF- $\alpha$  and TGF- $\beta$ 1, respectively, in lung tissue at different time-points among experimental mouse groups with different treatments. A-C are stained for TNF- $\alpha$  and D-F are stained for TGF- $\beta$ 1. AS only (A), AS injection before and after irradiation [AS/XRT, (B)] or irradiation only [XRT, (C)]. At 2 weeks, differential stains are obvious among groups with different treatments. In AS (A), it can be seen that the alveoli septa are normal and tissue architecture remains intact with a few cells positive for TNF- $\alpha$  (brown-stain). In XRT (C), it can be seen that a great number of TGF- $\beta$ 1-positive cells appears in the lung parenchyma; however, in AS/XRT (B), the quantity of positive cells is fewer than those in XRT. The staining for TGF- $\beta$ 1 is similar to that for TNF- $\alpha$ . At 4 weeks, it is obvious that cells are differentially stained for AS mouse (D), AS/XRT mouse (E) and XRT mouse (F). There are few cells positive for TGF- $\beta$ 1 (brown-stain) in AS mouse (D). Most positive cells are seen in XRT mouse (F). Note that positive cells in AS/XRT mouse (E) are obviously fewer than those in XRT mouse (F).

unknown, little can be done to prevent it or treat it, resulting in a dilemma when radiotherapy is the only option.

Previous reports (27-30) have suggested that inflammatory and fibrogenic cytokines may play important roles in the

pathogenesis of radiation-induced lung damage. Among the cytokines studied, TNF- $\alpha$  appears to be a critical molecule in the acute phase of radiation-induced inflammation because of its consistent overexpression in areas of histopathological

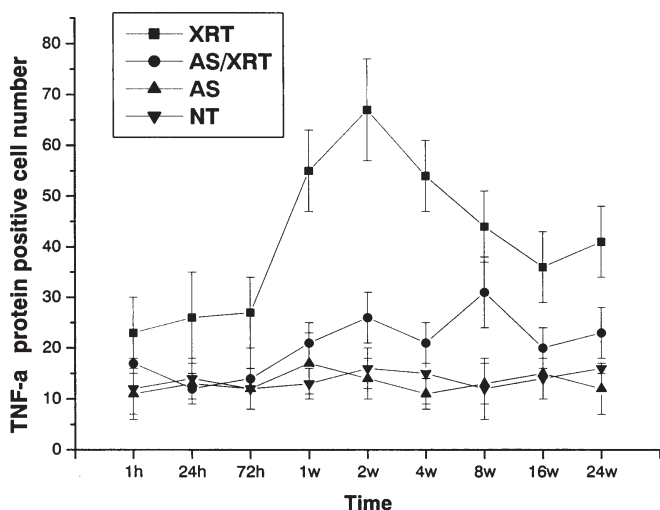


Figure 3. Time course of TNF- $\alpha$  protein expression (expressed as positive cell count) in the lung tissue of mice undergoing thoracic irradiation. The *Angelica Sinensis* plus radiation treatment group (AS/XRT group) showed a significant decrease ( $^*P<0.01$ ) in TNF- $\alpha$  protein expression from 1 week until 24 weeks after irradiation when compared with the radiation group (XRT group). All data are expressed as mean  $\pm$  SD.

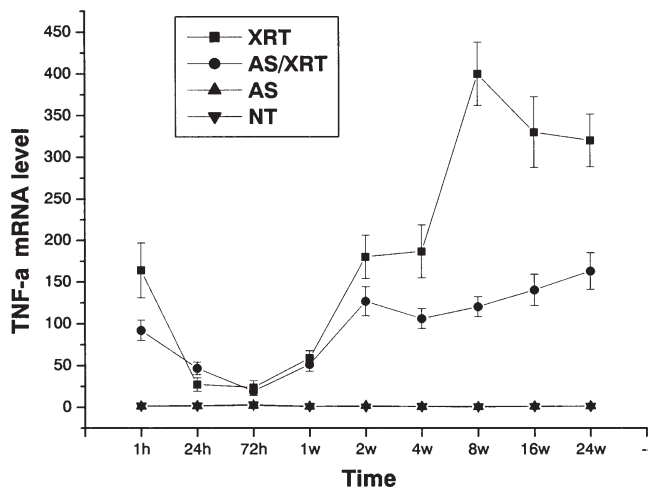


Figure 5. Time course of TNF- $\alpha$  mRNA expression in the lung tissue of mice undergoing thoracic irradiation. The *Angelica Sinensis* plus radiation treatment group (AS/XRT group) showed a significant decrease ( $^*P<0.01$ ) in TNF- $\alpha$  mRNA expression for time-points at 1 h and 8, 16 and 24 weeks post-irradiation when compared with the radiation group (XRT group). All data are expressed as mean  $\pm$  SD.

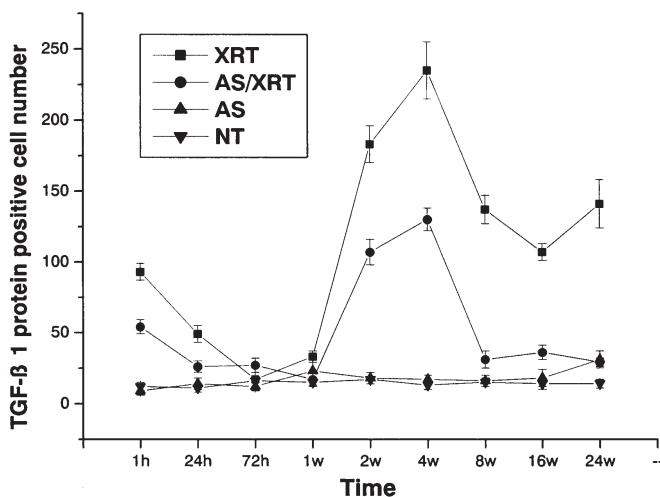


Figure 4. Time course of TGF- $\beta$ 1 protein expression (expressed as positive cell count) in the lung tissue of mice undergoing thoracic irradiation. The *Angelica Sinensis* plus radiation treatment group (AS/XRT group) showed a significant decrease ( $^*P<0.01$ ) in TGF- $\beta$ 1 protein expression for almost every time-point (except 72 h) post-irradiation when compared with the radiation group (XRT group). All data are expressed as mean  $\pm$  SD.

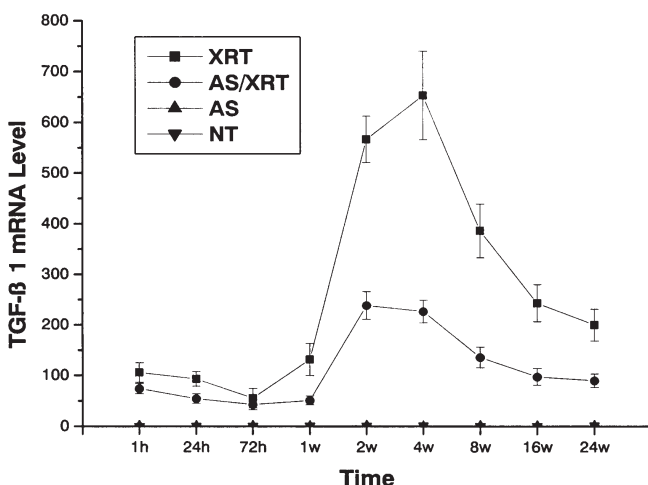


Figure 6. Time course of TGF- $\beta$ 1 mRNA expression in the lung tissue of mice undergoing thoracic irradiation. The *Angelica Sinensis* plus radiation treatment group (AS/XRT group) showed a significant decrease ( $^*P<0.01$ ) in TGF- $\beta$ 1 mRNA expression for time-points at 4, 8 and 16 weeks post-irradiation when compared with the radiation group (XRT). All data are expressed as mean  $\pm$  SD.

lesions. In the present study, we have shown that, as early as 1 h after thoracic irradiation, the bronchiolar epithelium in mouse lung tissue reveals intense staining for TNF- $\alpha$ , in keeping with previous findings.

Considering the cytokine network in radiation-induced lung injury, TNF- $\alpha$  which is initially overexpressed in pulmonary epithelial cells, probably initiates recruitment macrophages and other inflammatory cells into the sites of inflammation. Subsequently, TNF- $\alpha$  is also overexpressed by pulmonary macrophages in the lung parenchyma. It is known that TNF- $\alpha$  enhances the production of chemokines, of which many are

involved in recruiting monocytes/macrophages into the sites of inflammation. In addition, this study has shown that the endothelial lining of blood vessels is positively stained for TNF- $\alpha$  in a time-dependent manner after radiation. In the present study, the endothelial lining of blood vessels displayed TNF- $\alpha$  immunoreactivity as a function of time after radiation exposure. TNF- $\alpha$  induces the expression of cell surface adhesion molecules such as ICAM-1 and ELAM-1 (31). Expression of these endothelial cell adhesion molecules is crucial in binding leukocytes to the vessel wall at the site of inflammation.



SPANDIDOS PUBLICATIONS

previous study (32), the normal tracheobronchial epithelium, which has a relatively slow turn-over, may only require low levels of growth factors. However, under conditions of increased growth, such as those during the repair process after cell damage, increased synthesis and/or activation of TNF- $\alpha$  may be necessary to expedite cell proliferation and differentiation. Pulmonary epithelial hyperplasia in late stages of inflammatory lung diseases is associated with prolonged overexpression of TNF- $\alpha$ . Therefore, increased expression of TNF- $\alpha$  in the pneumonitic and fibrotic phases suggests that this cytokine is possibly involved in the proliferation as well as differentiation of lung cells following inflammation. Although the reason is unknown, we have observed that the medial smooth muscle cells can be stained for TNF- $\alpha$  at 72 h and remain positive until 24 weeks. Nevertheless, a previous study using IHC has reported transient, dose-dependent TNF- $\alpha$  induction in medial smooth muscle cells after combined intraoperative and external irradiation (33).

Excess expression of TGF- $\beta$ 1 has been suggested to be responsible for tissue damage in various pathological conditions, including fibrosis after radiotherapy and chemotherapy (12-14). In this study, mice exposed to radiation showed a pattern of TGF- $\beta$ 1 expression at late stages which had a peak at 2-4 weeks and continued until 24 weeks, when inflammatory cells constituted the majority of cells expressing TGF- $\beta$ 1. Our observations coincide with several previous reports (12-14,34), further indicating an important role played by TGF- $\beta$ 1 in pneumonitis and fibrosis induced by radiation.

*Angelica Sinensis* or 'Danggui' is a herbaceous perennial plant belonging to the Umbelliferae family (35). The root of *Angelica Sinensis* (Oliv.) Diels is the effective part widely used in Chinese medicine for treating anemia, menstrual irregularities and constipation (36). The use of *Angelica Sinensis* in cancer patients receiving radiotherapy is according to Chinese empirical practice, which shows clinical efficacy with little toxicity (26). Using a mouse model, we show here that, although moderate in action, *Angelica Sinensis* plays a down-regulatory role in the expression of both inflammatory cytokines, TNF- $\alpha$  and TGF- $\beta$ 1, at late phases of radiation-induced pneumonitis. In AS/XRT mice, the lower inflammatory responses induced by TNF- $\alpha$  and TGF- $\beta$ 1 in pneumonic and fibrotic phases (4-24 weeks) suggest that *Angelica Sinensis* may be beneficial at least in reducing the severity of fibrosis formation after acute inflammation induced by radiation, which would aid recovery in the late phase of disease. This is particularly relevant to the clinical efficacy of *Angelica Sinensis* in treating cancer patients who receive thoracic radiation. However, as *Angelica Sinensis* only shows moderate action in down-regulating TNF- $\alpha$  and TGF- $\beta$ 1, it is conceivable that its clinical efficacy in treating radiation-induced pneumonitis is achieved via multiple mechanisms. Therefore, other inflammatory mediators responsible for radiation-induced pneumonitis and fibrosis should be investigated in combination with *Angelica Sinensis*.

#### Acknowledgements

This study was supported by the National Science Foundation of China (NSFC) Grant No. 30472263.

#### References

- Molls M and van Beuningen D: Radiation injury of the lung: experimental studies, observations after radiotherapy and total body irradiation prior to bone marrow transplantation. In: Radiopathology of Organs and Tissues. Scherer E, Streffer C and Trott KR (eds). Springer-Verlag, Berlin, pp369-404, 1991.
- Rubin P, Johnston CJ, Williams JP, *et al*: A perpetual cascade of cytokines post-irradiation leads to pulmonary fibrosis. *Int J Radiat Oncol Biol Phys* 33: 99-109, 1995.
- Johnston CJ, Piedboeuf B, Baggs R, *et al*: Differences in correlation of mRNA gene expression in mice sensitive and resistant to radiation-induced pulmonary fibrosis. *Radiat Res* 142: 197-203, 1995.
- Johnston CJ, Piedboeuf B, Rubin P, *et al*: Early and persistent alterations in the expression of interleukin-1 $\alpha$ , interleukin-1 $\beta$  and tumor necrosis factor  $\alpha$  mRNA levels in fibrosis-resistant and sensitive mice after thoracic irradiation. *Radiat Res* 145: 762-767, 1996.
- Richter KK, Langberg CW, Sung CC, *et al*: Association of transforming growth factor  $\beta$ 1 (TGF- $\beta$ 1) immunoreactivity with specific histopathologic lesions in subacute and chronic experimental radiation enteropathy. *Radiother Oncol* 39: 243-251, 1996.
- Ruifrok ACC, Mason KA, Lozano G, *et al*: Spatial and temporal patterns of expression of epidermal growth factor, transforming growth factor alpha and transforming growth factor beta 1-3 and their receptors in mouse jejunum after radiation treatment. *Radiat Res* 147: 1-12, 1997.
- Skwarchuk MW and Travis EL: Changes in histology and fibrogenic cytokines in irradiated colorectum of two murine strains. *Int J Radiat Oncol Biol Phys* 42: 169-178, 1998.
- Litwin MS, Gamble JR and Vadas MA: Role of cytokines in endothelial cell function. In: Human Cytokines: Their Role in Disease and Therapy. Aggarwal BB and Pun RK (eds). Blackwell Science, Oxford, England, pp101-129, 1995.
- Ibelgauf H: TNF- $\alpha$ : tumor necrosis factor alpha. *Dictionary of cytokines*. VCH Verlagsgesellschaft mbH, Weinheim, 709-717, 1995.
- Rube CE, Wilfert F, Palm J and Konig J: Irradiation induces a biphasic expression of pro-inflammatory cytokines in the lung. *Strahlenther Onkol* 180: 442-448, 2004.
- Epperly MW, Travis EL, Sikora C, *et al*: Manganese (correction of Magnesium) superoxide dismutase (MnSOD) plasmid/liposome pulmonary radioprotective gene therapy: modulation of irradiation-induced mRNA for IL-1, TNF-alpha and TGF-beta correlates with delay of organizing alveolitis/fibrosis. *Biol Blood Marrow Transplant* 5: 204-214, 1999.
- Anscher MS, Crocker IR and Jirtle RL: Transforming growth factor- $\beta$ 1 expression in irradiated liver. *Radiat Res* 122: 77-85, 1990.
- Broekelmann TJ, Limper AH, Colby TV, *et al*: Transforming growth factor beta-1 is present at sites of extracellular matrix gene expression in human pulmonary fibrosis. *Proc Natl Acad Sci USA* 88: 6642-6646, 1991.
- Castilla A, Prieto J and Fausto N: Transforming growth factors beta-1 and alpha in chronic liver disease-effects of interferon alpha therapy. *N Engl J Med* 324: 993-940, 1991.
- Postlewaite AE, Keski-Oja J, Moses HL, *et al*: Stimulation of the chemotactic migration of human fibroblasts by transforming growth factor beta. *J Exper Med* 165: 251-256, 1987.
- Cromack DT, Sporn MB, Roberts AB, *et al*: Transforming growth factor beta levels in rat wound chambers. *J Surg Res* 42: 622-628, 1987.
- Mustoe TA, Pierce GF, Thomason A, *et al*: Accelerated healing of incisional wounds in rats induced by transforming growth factor beta. *Science* 235: 1333-1336, 1987.
- Roberts A, Sporn M, Assoian R, *et al*: Transforming growth factor type-beta: rapid induction of fibrosis and angiogenesis *in vivo* and stimulation of collagen formation *in vitro*. *Proc Natl Acad Sci USA* 83: 4167-4171, 1986.
- Sporn MB, Roberts AB, Shull JH, *et al*: Polypeptide transforming growth factors isolated from bovine sources and used for wound healing *in vivo*. *Science* 219: 1329-1331, 1983.
- Fine A and Goldstein RH: The effect of transforming growth factor beta on cell proliferation and collagen formation by lung fibroblasts. *J Biol Chem* 262: 3897-3902, 1987.
- Lund LR, Riccio A, Andreasen PA, *et al*: TGF- $\beta$  is a strong and fast-acting positive regulator of the level of Type 1 plasminogen activator inhibitor mRNA in WI-38 lung fibroblast. *EMBO J* 6: 1281-1286, 1987.

22. Yamada H, Kiyohara H, Cyong JC, *et al*: Studies on polysaccharides from *Angelica acutiloba*. *Planta Med* 50: 163-167, 1984.
23. Kim SH, Lee SE, Oh H, *et al*: The radioprotective effects of buzhong-yi-qi-tang: a prescription of traditional Chinese medicine. *Am J Chin Med* 30: 127-137, 2002.
24. Wang X, Wei L, Ouyang JP, *et al*: Effects of an angelica extract on human erythrocyte aggregation, deformation and osmotic fragility. *Clin Hemorheol Microcirculation* 24: 201-205, 2001.
25. Xie F, Li X, Sun K, *et al*: An experimental study on drugs for improving blood circulation and removing blood stasis in treating mild chronic hepatic damage. *J Tradit Chin Med* 21: 225-231, 2001.
26. Cai H-B and Luo R-C: Prevention and therapy of radiation-induced pulmonary injury with traditional Chinese medicine. *J First Mil Med Univ* 23: 958-960, 2003.
27. Finkelstein JN, Johnston CJ, Baggs R, *et al*: Early alterations in extracellular matrix and transforming growth factor  $\beta$  gene expression in mouse lung indicative of late radiation fibrosis. *Int J Radiat Oncol Biol Phys* 28: 621-631, 1994.
28. Franko AJ, Sharplin J, Ghahary A, *et al*: Immunohistochemical localization of transforming growth factor  $\beta$  and tumor necrosis factor  $\alpha$  in the lungs of fibrosis-prone and 'non-fibrosing' mice during the latent period and early phase after irradiation. *Radiat Res* 147: 245-256, 1997.
29. Yi ES, Bedoya A, Lee H, *et al*: Radiation-induced lung injury *in vivo*: expression of transforming growth factor-beta precedes fibrosis. *Inflammation* 20: 339-351, 1996.
30. Gauldie J, Jordana M and Cox G: Cytokines and pulmonary fibrosis. *Thorax* 48: 931-935, 1993.
31. Beck-Schimmer B, Schimmer RC, Warner RL, *et al*: Expression of lung vascular and airway ICAM-1 after exposure to bacterial lipopolysaccharide. *Am J Respir Cell Mol Biol* 17: 344-352, 1997.
32. Jetten AM: Growth and differentiation factors in tracheo-bronchial epithelium. *Am J Physiol* 260: 361-373, 1991.
33. Kallfass E, Krämling HJ and Schultz-Hector S: Early inflammatory reaction of the rabbit coeliac artery wall after combined intraoperative (IORT) and external (ERT) irradiation. *Radiother Oncol* 39: 167-178, 1996.
34. Yi ES, Bedoya A, Lee H, *et al*: Radiation-induced lung injury *in vivo*: expression of transforming growth factor  $\beta$  precedes fibrosis. *Acta Oncol* 38: 147-152, 1999.
35. Hsieh MT, Lin YT, Lin YH, *et al*: *Radix angelica sinensis* extracts ameliorate scopolamine- and cycloheximide-induced amnesia, but not p-chloroamphetamine-induced amnesia in rats. *Am J Chin Med* 28: 263-272, 2000.
36. Ye YN, Liu ESL, Li Y, *et al*: Protective effect of polysaccharides-enriched fraction from *Angelica sinensis* on hepatic injury. *Life Sci* 69: 637-646, 2001.