

Dysregulated expression of HOX and ParaHOX genes in human esophageal squamous cell carcinoma

OSAMU TAKAHASHI^{1,2}, JUN-ICHI HAMADA¹, MOTOKI ABE^{1,2}, SHINYA HATA¹,
TOSHIMICHI ASANO^{1,2}, YOKO TAKAHASHI¹, MITSUHIRO TADA¹,
MASAKI MIYAMOTO², SATOSHI KONDO² and TETSUYA MORIUCHI¹

¹Division of Cancer-Related Genes, Institute for Genetic Medicine, Hokkaido University; ²Department of Surgical Oncology, Division of Cancer Medicine, Hokkaido University Graduate School of Medicine, Sapporo 060-0815, Japan

Received September 26, 2006; Accepted November 27, 2006

Abstract. Homeobox genes function as master regulators in embryonic morphogenesis. We hypothesized that homeobox genes are essential to maintain tissue- or organ-specificity even in adult body and that the dysregulated expression of homeobox genes results in tumor development and progression. To better understand the roles of homeobox genes in development and progression of esophageal cancer, we analyzed the expression patterns of 39 HOX genes and 4 ParaHOX (CDX1, CDX2, CDX4 and PDX1) genes in esophageal squamous cell carcinoma (ESCC) and normal esophageal mucosa tissues. A total of 48 primary ESCC tissues and 7 normal esophageal mucosa tissues were resected from patients who underwent radical surgery without any preoperative chemotherapy or radiotherapy. The expression of HOX and ParaHOX genes were analyzed by a quantitative real-time RT-PCR method and immunohistochemistry. The expression levels of 24 HOX genes, CDX1, CDX2 and PDX1 were significantly higher in ESCC compared to normal mucosa ($p < 0.01$, Mann-Whitney U test). The Immunohistochemical study revealed that HOXA5 and D9 proteins were more cytoplasmic in ESCC than normal mucosa cells. Our data indicate that the disordered expression of HOX and ParaHOX genes are involved in the development of ESCC or its malignancy.

Introduction

Homeobox genes are master development-controlling genes that regulate the morphogenesis and cell differentiation in animals (1). The genes contain a common DNA motif of 180 bp, the homeobox, which encodes a highly conserved

60 amino-acid homeodomain. The homeodomain is responsible for recognition and binding of sequence-specific DNA motifs, and cis-regulates the transcription of genes relevant to formation of specific segmental architecture (2). Homeobox genes are subdivided into ~20 subgroups according to their primary sequences. HOX genes, one of the subgroups of homeobox genes, were originally identified in *Drosophila*. Human genome contains 39 HOX genes arranged in four clusters HOXA, HOXB, HOXC and HOXD located on different chromosomes. CDX and PDX genes are known as ParaHox genes, an evolutionary sister of the Hox clusters. CDX genes are human homologues of the *Drosophila Caudal* gene which is required for anterior-posterior regional identity. Some studies of CDX1 and CDX2 suggest that they are important in the early differentiation and maintenance of the intestinal epithelium. For example, *in vitro* experiments using rodent and human cell lines indicate that modification of CDX1 or CDX2 expression alters cell growth or the intestinal differentiation phenotype (3,4). *In vivo* observation of CDX genes and their products during mouse development or phenotypic analysis of CDX-gene-mutant mice identifies a role of CDX genes in the maintenance of the intestinal phenotype (5,6). PDX1 is another member of the ParaHox subgroup and plays a crucial role in the genesis and development of the pancreas and duodenum (7).

Recently, there is growing interest in investigating the relationship of abnormal expression of these homeobox genes with carcinogenesis or malignant progression. The deregulated expression of HOX genes has been observed in certain human solid cancers including kidney, colon, bladder and prostate cancers (8-11). It is also reported that HOX gene expression is different between metastatic and non-metastatic phenotype in lung and melanoma (12,13). CDX1 and/or CDX2 are often expressed in adenocarcinoma of the esophagus or stomach, but not in normal esophagus and stomach, whereas the expression of CDX1 and/or CDX2 are lost in primary colorectal cancers (14,15). PDX1 plays an important role in the development of pseudopyloric glands which may reflect a condition associated with gastric carcinogenesis (16).

Esophageal cancer ranks as the ninth most common malignancy worldwide and recent evidence shows that its incidence is increasing (17). There are two main forms of

Correspondence to: Dr Jun-ichi Hamada, Division of Cancer-Related Genes, Institute for Genetic Medicine, Hokkaido University, Kita-15, Nishi-7, Kita-ku, Sapporo 060-0815, Japan
E-mail: jhamada@igm.hokudai.ac.jp

Key words: homeobox gene, HOX, real-time RT-PCR, esophageal cancer, ParaHOX

esophageal cancer: squamous cell carcinoma (ESCC) and adenocarcinoma. In Western countries, the incidence of esophageal adenocarcinoma has been increasing, whereas in Japan no such tendency exists, and the majority of esophageal cancer is ESCC (18,19). Prognosis of esophageal cancer is relatively poor, despite the advances made in diagnosis and treatment (20,21). To improve the prognosis, it is essential to reveal the molecular mechanism for esophageal carcinogenesis and malignant progression. In the present study, to better understand the roles of homeobox genes in development and progression of esophageal cancer, we analyzed the expression patterns of 39 HOX genes, 3 CDX genes and PDX1 gene in normal esophageal mucosa and ESCC tissues.

Materials and methods

Patients and samples. A total of 48 primary ESCC tissues and 7 normal esophageal mucosa tissues were obtained from surgical specimens resected from patients who underwent radical surgery without any preoperative chemotherapy or radiotherapy at the Department of Surgical Oncology, Hokkaido University Hospital and 16 affiliated hospitals in Hokkaido, Japan, between 2001 and 2003. Only those patients who agreed with the aim and contents of this study and who provided their written informed consent were subjected to the study. Tumor tissue and normal mucosa samples of ~5 mm-size were immediately cut from the esophagus resected by a standard surgical procedure, snap frozen in liquid nitrogen, and stored at -80°C until use. A part of each tumor sample was cut and stained with hematoxylin and eosin for verification of the presence of squamous cell carcinoma cells, and the other part was used for RNA extraction. All procedures in this portion of the study were approved by the Ethics Committee of Hokkaido University and the independent internal ethics committees of the affiliated hospitals. Histological subclassification and staging of the tumors was done by reviewing the specimens taken for pathological diagnosis, according to the TNM classification. The tumor status of each case was categorized based on the pTNM pathological classification of the International Union Against Cancer. Pertinent major clinicopathological parameters are shown in Table I.

RNA extraction and cDNA preparation. Total RNA was extracted from powdery frozen tissues of each clinical

Table I. Clinicopathological parameters in the 48 cases of esophageal squamous cell carcinoma.

	Depth of invasion		
	pT1 (n=10)	pT2 (n=9)	pT3 (n=29)
Age (mean ± SD)	65.9±7.4	64.4±8.8	62.3±6.4
Gender			
Male	9	7	23
Female	1	2	6
pTNM N-status			
N0	6	3	15
N1	4	6	14
pTNM M-status			
M0	10	9	29
M1a	0	0	0
M1b	0	0	0
pTMN Stage			
I	6	0	0
IIA	4	3	15
IIB	0	6	0
III	0	0	14
IVA	0	0	0
IVB	0	0	0

The tumor status of each case was categorized based on the pTNM pathological classification of the International Union Against Cancer.

specimen which had been crushed in liquid nitrogen with a Cryo-Press compressor (Microtec Niton, Chiba, Japan) with Trizol reagent (Invitrogen, Carlsbad, CA) according to the manufacturer's instruction. For exclusion of contaminated genomic DNA, 50 µg of total RNA was incubated for 30 min at 37°C in 50 µl of reaction mixture containing 40 mM Tris-HCl (pH 7.2), 10 mM NaCl, 6 mM MgCl₂, 2 mM dithiothreitol, 0.04 U/µl Pq1 DNase (Promega, Madison, WI), and 0.4 U/µl RNase inhibitor. Reverse transcription reaction for real-time PCR was performed by the method described in our previous study (22).

Table II. Primers for quantitative real-time RT-PCR analysis of ParaHOX expression.

Genes	Accession no.	Primer sequence (5' to 3')		Primer concentration (µM)	Amplicon size (bp)
		Forward	Reverse		
CDX1	U51095	CACAATCCGGCGGAAATC	TCACTTTGCGCTCCTTTGC	0.9	103
CDX2	U51096	GCTGGAGAAGGAGTTTCACTACAGT	AACCAGATTTTAACCTGCCTCTCA	0.9	104
CDX4	AF003530	GGGAAAACCAGGACAAAAGA	TAAGTCCAGCTCTGATTTTCTC	0.9	126
PDX1	U35632	TGGATGAAGTCTACCAAAGCT	GTGAGATGTACTTGTGAATAGGAAC	0.9	159

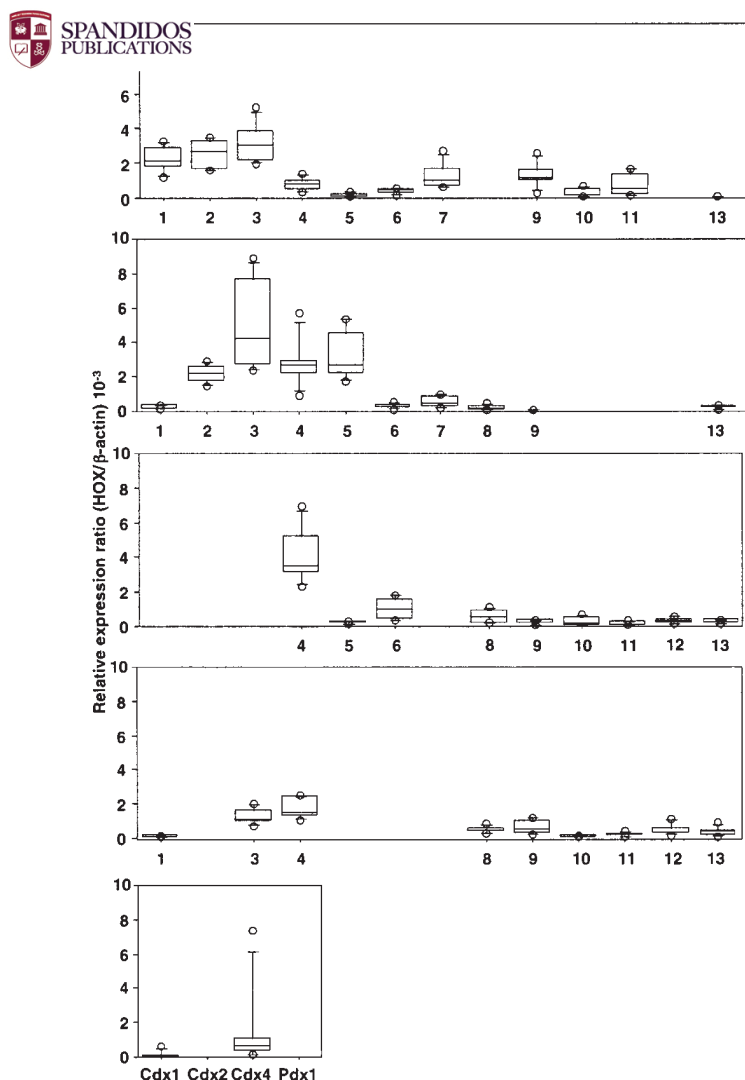


Figure 1. Expression profiling of 39 HOX genes and 4 ParaHOX genes in normal esophageal mucosa tissues. The relative levels of HOX mRNA determined by quantitative RT-PCR in 7 normal mucosa tissues. The graphs of HOX cluster A, B, C and D are lined from top to bottom. HOX gene paralogs 1 to 13 are lined from left to right of X-axis in each graph. The distribution of the relative expression ratio (HOX or ParaHOX/ β -actin) is summarized by using boxplots. The central box in each plot shows the interquartile (25th to 75th percentile) range. The line in the box shows the median. The whiskers (vertical bars) were drawn to the 90th and 10th percentiles. Extreme values greater than the 90th percentile and less than the 10th percentile were plotted individually.

Quantitative real-time PCR. Quantitative RT-PCR assays were carried out by using ABI PRISM 7900HT (Applied Biosystems) with SYBR-green fluorescence under the conditions described in our previous study (22). The primer sets for amplification of 39 HOX genes and β -actin gene were listed previously (22). The primer sets for amplification of ParaHOX genes (CDX1, CDX2, CDX4 and PDX1) were designed in the same manner as described previously (22), (Table II).

Immunohistochemistry. Sections (4 μ m-thick) of formalin-fixed, paraffin-embedded tissue specimens were deparaffinized and dehydrated. After antigen retrieval by heating in a pressure cooker for 10 min, the sections were incubated with 10% normal rabbit serum to block any non-specific reaction. Then,

the sections were incubated with a goat polyclonal antibody against human HOXA5 (dilution 1:200; Santa Cruz Biotechnology, Santa Cruz, CA) at 4°C overnight, followed by incubation with a biotinylated rabbit antibody against goat immunoglobulin (Nichirei, Tokyo, Japan) at room temperature for 30 min. In case of detection of HOXD9 protein, the sections were incubated with a rabbit polyclonal antibody against human HOXD9 (dilution 1:200; Santa Cruz Biotechnology) at 37°C for 32 min, followed by incubation with a biotinylated goat antibody against rabbit immunoglobulin at room temperature for 30 min. Immunohistochemical reactions were developed in freshly prepared 3,3'-diaminobenzidine tetrahydrochloride (Nichirei). The sections were counterstained in hematoxylin and coverslipped in a syatemic mounting medium. As a negative control, we used 10% normal goat serum or normal rabbit serum (Nichirei) for the primary antibody.

Statistical analysis. The relationship between the expression of each HOX and ParaHOX gene and each clinicopathological parameter was determined by the Mann-Whitney U test or the Kruskal-Wallis rank test. The statistical software package applied was Statview 5.0 for Macintosh (SAS Institute, Cary, NC). A P-value <0.01 was considered statistically significant.

Results

Expressions of homeobox genes in normal esophageal mucosa tissues. Expression levels of 39 HOX genes, 3 CDX genes and the PDX1 gene in 7 normal mucosa tissues are shown in Fig. 1. The normal mucosa tissues showed relatively high expressions of HOXA1, A2, A3, B2, B3, B4, B5 and C4 which located at 3'-side of each cluster. The expression of HOX genes belonging to cluster D was silent except HOXD3 and D4 which showed slight expressions. Abd-B family of HOX genes (paralog 9 to 13) which located at 5'-side of each cluster were not expressed except HOXA9 and A11 which were slightly expressed. The 3 CDX genes and PDX1 gene were not expressed in any of the normal mucosa tissues with one exception that expressed the CDX4 gene at a high level (relative expression ratio: 0.00736).

Difference in homeobox gene expression between normal mucosa and squamous cell carcinoma. The expression patterns of 39 HOX genes in 48 ESCCs and 7 normal mucosa specimens are shown in Fig. 2A. We found significant differences in the expression levels of 24 HOX genes ($p < 0.01$, Mann-Whitney U test). An increase in the expression of HOX genes in ESCC was remarkable, especially in Abd-B family of HOX genes. Of the 16 HOX genes belonging to Abd-B family, 12 HOX genes showed a significantly higher expression in ESCC than normal mucosa; the 4 other HOX genes had a tendency of increased expression in ESCC although there was no statistical difference between them. Comparing the increased expression of HOX genes in ESCC among 4 clusters, all the HOX genes belonging to cluster C and D, except HOXC4, C12 and D12, increased their expressions in ESCC whereas only about half the HOX genes belonging to cluster A and B did likewise. The expression levels of CDX genes and PDX1 in normal mucosa and SCCs are shown in




Figure 2. First part. See the second part for details.

Fig. 2B. The expression levels of CDX1, CDX2 and PDX1 were significantly higher in ESCC compared to normal mucosa.

Homeobox gene expression and clinicopathologic parameters. We next classified 48 ESCC specimens into three groups according to T categories: T1, T2 and T3 meant tumor invasion of lamina propria or submucosa, muscularis and adventitia, respectively, and compared the HOX, CDX and PDX1 gene expressions among the three groups. We found 7 HOX genes (HOXA5, A10, B13, C6, C10, C13 and D3) of which expression levels were significantly different among T1, T2 and T3 groups ($p < 0.01$, Kruskal Wallis test). There was a tendency that the expression levels of all the 7 HOX genes in T2 group were highest among the 3 groups, and the expression levels of the HOX genes in T3 group were significantly lower than those in T2 group. There was no difference in expression levels of CDX1, CDX2, CDX4 and PDX1 among the 3 groups (Fig. 3).

We examined the relationship between the expressions of HOX, CDX and PDX1 genes and other clinicopathological parameters such as lymph node involvement, lymphatic involvement, venous involvement, histological types, the location of tumors and tumor markers (CEA and SCC); however, we found no relation between them.

Immunohistochemical examination for HOXA5 and HOXD9 in ESCC specimens. We subjected ESCC tissues and their adjacent noncancerous mucosa tissues of 9 specimens to immunohistochemical staining to detect the protein expression of HOXA5 and D9 of which expression were higher at mRNA levels in ESCC than normal mucosa tissues. Fig. 4 shows representative results of the immunohistochemical staining. In normal mucosa, HOXA5 immunoreactivity was observed only in the cytoplasm of basal cells (Fig. 4A). In ESCC tissues, HOXA5 immunoreactivity was detected in cytoplasm of almost all the tumor cells (Fig. 4B). No detectable HOXD9 immunoreactivity was observed in normal mucosa whereas HOXD9 immunoreactivity was observed in cytoplasm of tumor cells but not stroma tissues in ESCC tissues (Fig. 4D and E). Intensity of immunoreactivity of both HOX proteins was consistent with the expression levels of mRNA for both HOX genes in the 9 samples examined (data not shown).

Discussion

In the present study, we tried to elucidate whether deregulated expressions of homeobox genes were involved in development and malignant progression of esophageal squamous cell carcinoma. Our comprehensive analysis of 39 HOX genes, 3

A (continued)

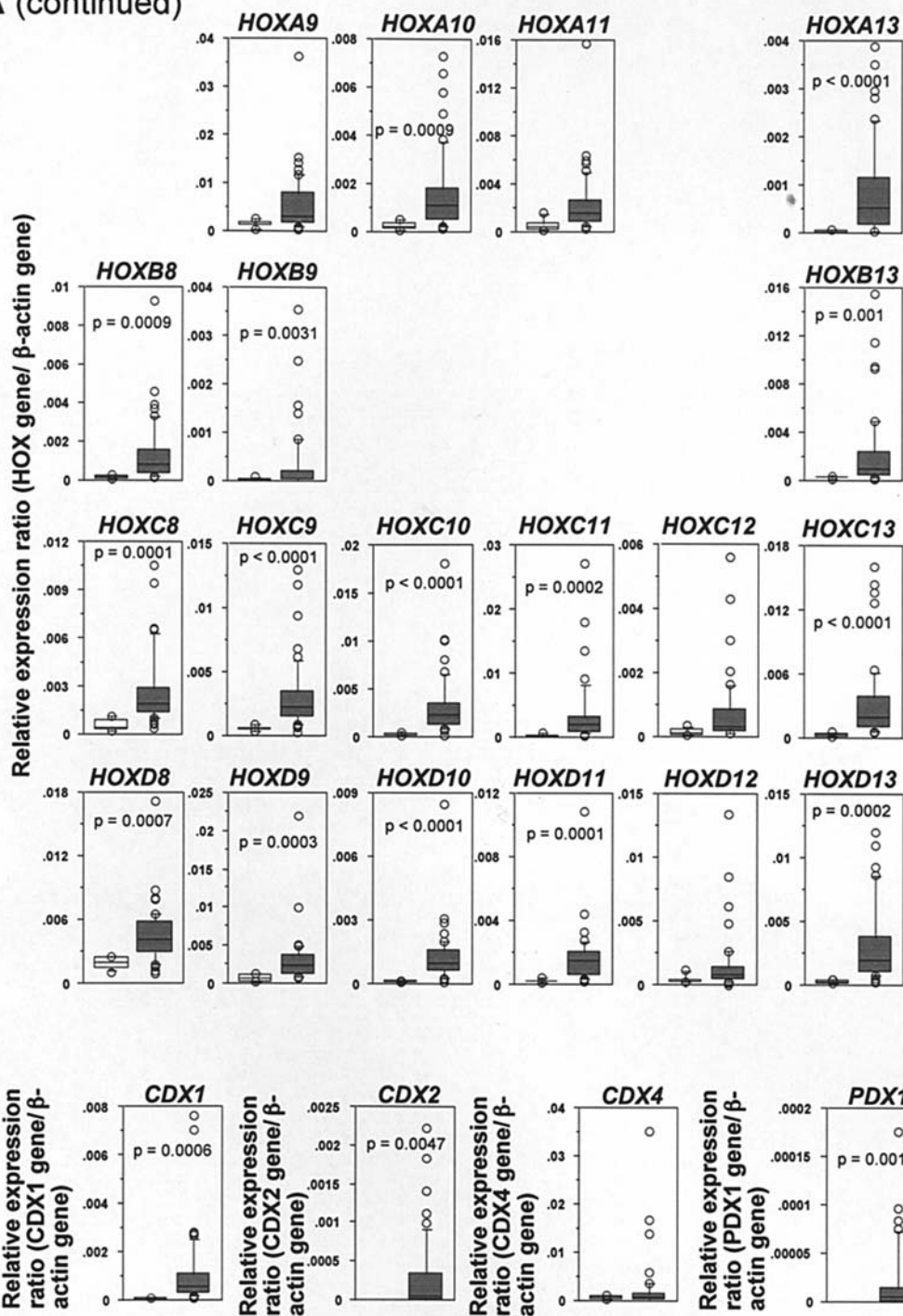


Figure 2. Second part. Different expression levels of HOX genes and ParaHOX genes between esophageal squamous cell carcinoma (ESCC) and normal mucosa tissues. The distribution of the relative expression ratio (HOX or ParaHOX/ β -actin) is depicted by using boxplots in the same manner as in Fig. 1. A, the graphs of HOX gene cluster A to D are lined from top to bottom; the graphs of HOX gene paralog 1 to 13 are lined from left to right. B, the graphs of ParaHOX genes (CDX1, CDX2, CDX4 and PDX1). Shaded boxes and open boxes represent SCC and normal mucosa tissues, respectively. P-values were determined by the Mann-Whitney U test.

CDX genes and PDX1 gene in 48 ESCC and 7 normal mucosa tissues uncovered the esophagus-characteristic expression pattern of these homeobox genes and its disordered pattern of ESCC.

In normal mucosa tissues, HOXA1, A2, A3, B2, B3, B4, B5 and C4 were highly expressed, and HOXD3 and D4 were also expressed although their expression levels were not so high as the 8 HOX genes. On the other hand, Abd-B family genes (paralog 9 to 13) were not expressed except HOXA9 and A11

which were slightly expressed. Thus, it is characteristic that in each cluster the 3'-located genes showed relatively high expression whereas the 5' located genes were silent. Yahagi *et al* reported position-specific expression of HOX genes along the human adult gastrointestinal tract (23). They showed that the first three paralogs in each cluster were highly expressed in the foregut-derived organs such as the esophagus and stomach. We have previously demonstrated that the expression patterns of HOX genes in lung, thyroid

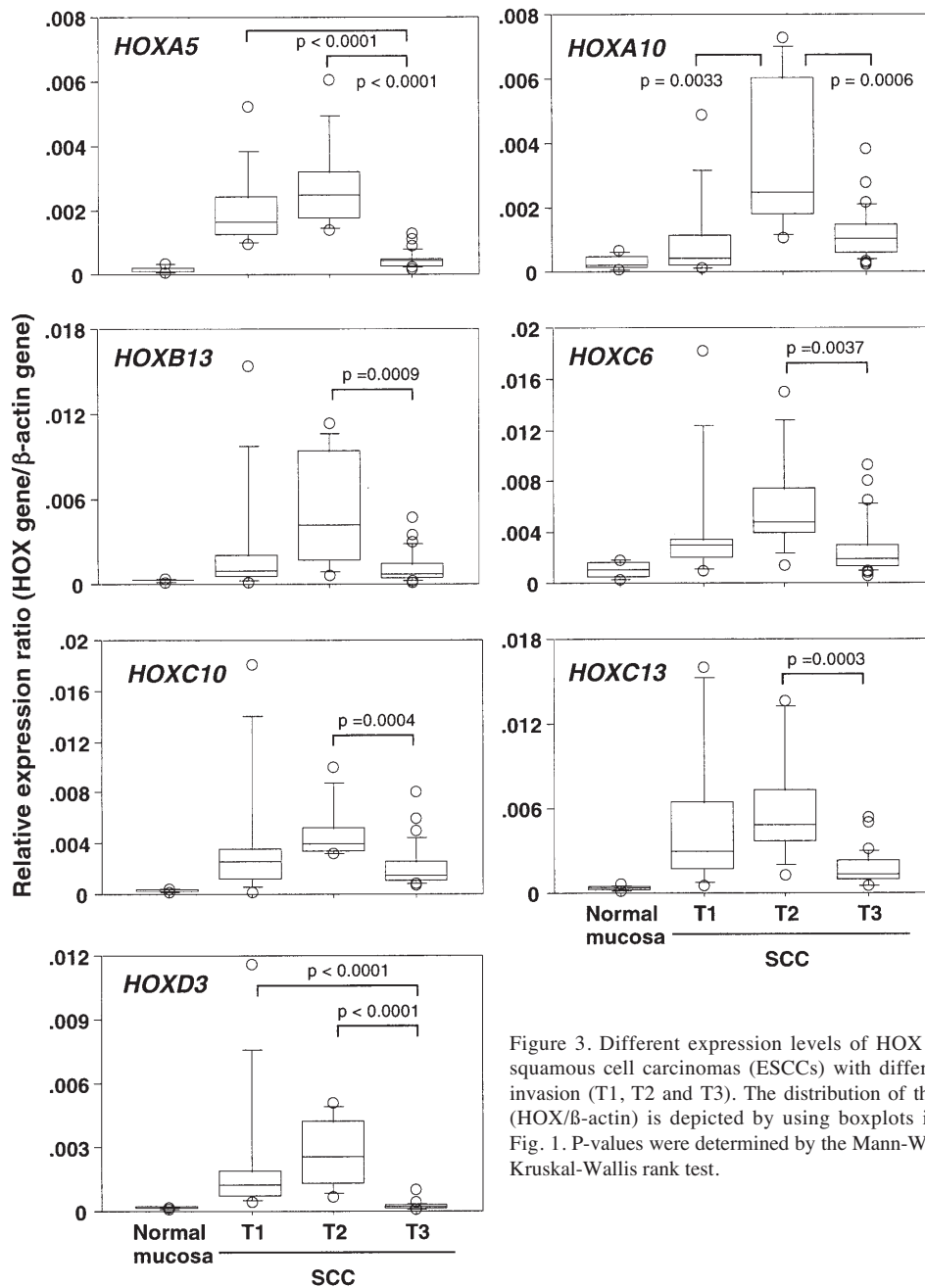


Figure 3. Different expression levels of HOX genes among esophageal squamous cell carcinomas (ESCCs) with different status of the depth of invasion (T1, T2 and T3). The distribution of the relative expression ratio (HOX/ β -actin) is depicted by using boxplots in the same manner as in Fig. 1. P-values were determined by the Mann-Whitney U test following the Kruskal-Wallis rank test.

and trachea which were at similar location to esophagus along the anteroposterior axis, were almost similar to those in the esophagus (22). Taken these results together with the observation of Hox expression patterns in gastrointestinal of mouse or chick embryo, this expression pattern presented herein recapitulates the expression pattern in the embryonic esophagus. The expression of 3 CDX genes or PDX1 gene was not detectable in any normal mucosa except one specimen expressing the CDX4 gene at a high level. This evidence suggests that CDXs and PDX1 are not essential to maintain the tissue architecture and/or function in adult esophagus.

Comparison of the expression levels between normal mucosa and SCC tissues presented different expressions of 24 HOX genes. Expression of all the 24 HOX genes increased in SCC. Chen *et al* documented 11 HOX genes of which expression was dysregulated in ESCCs (24). The 24

HOX genes presented herein contained the 11 genes. Discrepancy between our data and theirs may arise from differences in the method of analysis: we used a highly quantitative RT-PCR method whereas they used a semi-quantitative RT-duplex PCR method. Of the 24 HOX genes of which expressions increased in ESCCs, 20 genes were the adjacent genes on the same cluster (A5/A6, B6/B7/B8/B9/B13, C5/C6/C8/C9/C10/C11, and D1/D3/D4/D8/D9/D10/D11). This observation suggests the possibility that these adjacent HOX genes are cis-activated and controlled by common upstream regulatory components and that such regulatory components may be dysregulated in esophageal SCC.

The expression of several HOX genes such as HOXA5, A10, B13, C6, C10, C13 and D3 was down-regulated in samples of T3 (depth of invasion) compared to those of T1 and/or T2. As the expression levels of these 7 Hox genes in T1 and/or T2 were significantly higher than those in normal

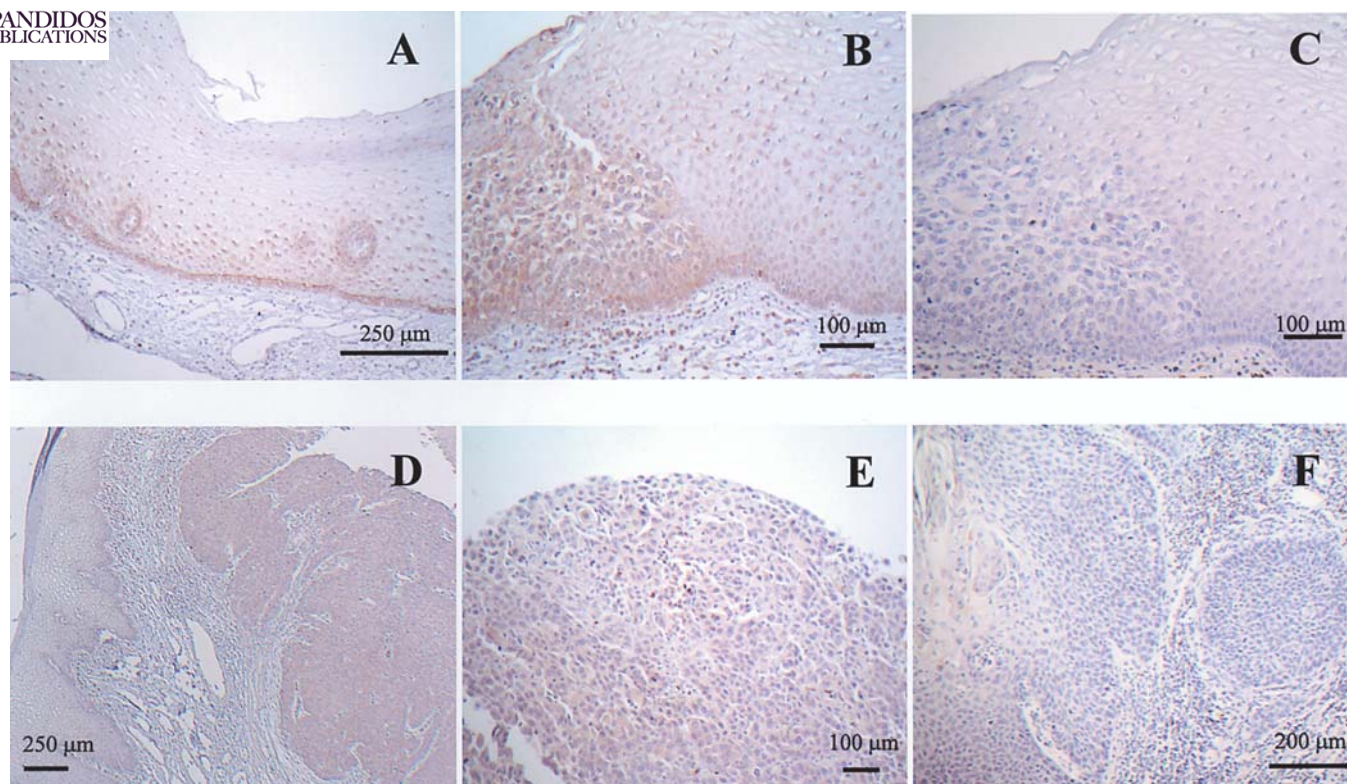


Figure 4. Immunohistochemical staining of HOXA5 and D9. In normal mucosa, immunoreactivity of HOXA5 was observed in cytoplasm of basal layer cells (A, original magnification x100). The HOXA5 immunoreactivity was observed in cytoplasm of almost all the tumor cells in ESCC tissues, and the adjacent right part was non-cancerous tissues where weak immunoreactivity was detected (B, original magnification x200). No immunoreactivity was detected in the same section as B, which was treated with normal goat IgG instead of anti-HOXA5 antibody (C, original magnification x200). The HOXD9 immunoreactivity was observed in tumor cells (right part) but not in non-cancerous mucosa (left part) (D, original magnification x100). The HOXD9 immunoreactivity was observed in cytoplasm of almost all the tumor cells in ESCC tissues (E, original magnification x200). No immunoreactivity was detected in the section which was treated with normal rabbit IgG instead of anti-HOXD9 antibody (F, original magnification x200).

mucosa, it was thought that these HOX genes played a positive role in development of esophageal SCC, but not its invasion of adventitia. It is of interest whether loss of the expression of these HOX genes gives tumor cells an advantage to invade adventitia or whether any microenvironmental changes to modify HOX gene expression occur in T3 tumors.

We also performed immunohistochemical analysis of the expressions of two HOX proteins, HOXA5 and D9, by using specific antibodies available commercially. Both HOX proteins were expressed in tumor cells at a high level compared to normal regions or tumor stroma. HOXA5 protein was also expressed in the basal cell layer. These observations are consistent with the data from HOX gene expressions by the real-time RT-PCR method: the expression levels of both HOX genes were higher in SCCs than in normal mucosa, and HOXA5 showed slight expression in normal mucosa. Surprisingly, both HOX proteins detected were mainly cytoplasmic but not nuclear. As HOXA5 is a potent transactivator of the p53, i.e., tumor suppressor gene (25), HOXA5 may be on standby in time of need to respond to DNA damage in proliferative cells such as normal basal layer cells and tumor cells. HOX proteins are reported to have other functions than as DNA binding transcription factors. For example, HOXA13 and D13 interact with Smad protein to modify Smad transcriptional activation (26). HOX proteins bind to CREB binding protein (CBP) through homeodomain and block its

acetyltransferase activity (27), indicating that HOX proteins modulate the transcriptional activity through interaction with other proteins in a non-DNA binding manner. Therefore, we need to consider the possibility that these HOX proteins interfere with the function of tumor suppressive molecules including p53 protein in tumor cells.

We found the deregulated expression not only of HOX genes but also of ParaHOX homeobox genes such as CDX1, CDX2, CDX4 and PDX1 in ESCC. The expression levels of the 3 genes other than CDX4 were high in ESCC compared to normal mucosa. So far, it has been considered that CDX1 and CDX2 are important in the transition from esophageal epithelium to intestinal-type metaplasia (14,28). We showed that CDX1 and CDX2 play a role in the development of not only intestinal metaplasia but also ESCC. The roles of CDX1 and CDX2 in carcinogenesis of digestive tract epithelium have been conflicting: there are reports indicating that they function as oncogenic or anti-oncogenic molecules (4,29). Our data may reflect oncogenic function of CDX1/CDX2 in the development of ESCC since the expression of both genes increased in ESCC. Further, murine Cdx protein is known to be a potent regulator of Hoxa5 expression (30). HOXA5 expression was higher in ESCC than normal mucosa, thus, it is possible that the increased expression of HOXA5 in ESCC may be induced by CDX1 and/or CDX2. We need to advance the study further to clarify the biological

function of each homeobox gene of which expression was elevated in ESCC and the detailed network between HOX and ParaHOX genes.

An important aspect of the present study is that for the first time we analysed quantitatively the expressions of all HOX and ParaHOX genes at the mRNA level in ESCC and normal mucosa and that we found the disorder of network of these genes in ESCC, which may be involved in ESCC carcinogenesis.

Acknowledgements

We wish to thank Ms. Masako Yanome for her help in preparing the study. This work was supported in part by Grant-in-Aid for Scientific Research (B) (J.H.) from the Ministry of Education, Culture, Sports, Science and Technology of Japan.

References

- Gehring WJ and Hiromi Y: Homeotic genes and the homeobox. *Annu Rev Genet* 20: 147-173, 1986.
- McGinnis W and Krumlauf R: Homeobox genes and axial patterning. *Cell* 68: 283-302, 1992.
- Soubeyran P, Andre F, Lissitzky JC, Mallo GV, Moucadel V, Roccabianca M, Rechreche H, Marvaldi J, Dikic I, Dagorn JC and Iovanna JL: Cdx1 promotes differentiation in a rat intestinal epithelial cell line. *Gastroenterology* 117: 1326-1338, 1999.
- Mallo GV, Soubeyran P, Lissitzky JC, Andre F, Farnarier C, Marvaldi J, Dagorn JC and Iovanna JL: Expression of the Cdx1 and Cdx2 homeotic genes leads to reduced malignancy in colon cancer-derived cells. *J Biol Chem* 273: 14030-14036, 1998.
- Silberg DG, Swain GP, Suh ER and Traber PG: Cdx1 and cdx2 expression during intestinal development. *Gastroenterology* 119: 961-971, 2000.
- Chawengsaksophak K, James R, Hammond VE, Kontgen F and Beck F: Homeosis and intestinal tumours in Cdx2 mutant mice. *Nature* 386: 84-87, 1997.
- Offield MF, Jetton TL, Labosky PA, Ray M, Stein RW, Magnuson MA, Hogan BL and Wright CV: PDX-1 is required for pancreatic outgrowth and differentiation of the rostral duodenum. *Development* 122: 983-995, 1996.
- Cillo C, Barba P, Freschi G, Bucciarelli G, Magli MC and Boncinelli E: HOX gene expression in normal and neoplastic human kidney. *Int J Cancer* 51: 892-897, 1992.
- De Vita G, Barba P, Odartchenko N, Givel JC, Freschi G, Bucciarelli G, Magli MC, Boncinelli E and Cillo C: Expression of homeobox-containing genes in primary and metastatic colorectal cancer. *Eur J Cancer* 29A: 887-893, 1993.
- Cantile M, Cindolo L, Napodano G, Altieri V and Cillo C: Hyperexpression of locus C genes in the HOX network is strongly associated *in vivo* with human bladder transitional cell carcinomas. *Oncogene* 22: 6462-6468, 2003.
- Waltregny D, Alami Y, Clausse N, De Leval J and Castronovo V: Overexpression of the homeobox gene HOXC8 in human prostate cancer correlates with loss of tumor differentiation. *Prostate* 50: 162-169, 2002.
- Hamada J, Omatsu T, Okada F, Furuuchi K, Okubo Y, Takahashi Y, Tada M, Miyazaki YJ, Taniguchi Y, Shirato H, Miyasaka K and Moriuchi T: Overexpression of homeobox gene HOXD3 induces coordinate expression of metastasis-related genes in human lung cancer cells. *Int J Cancer* 93: 516-525, 2001.
- Maeda K, Hamada J, Takahashi Y, Tada M, Yamamoto Y, Sugihara T and Moriuchi T: Altered expressions of HOX genes in human cutaneous malignant melanoma. *Int J Cancer* 114: 436-441, 2005.
- Silberg DG, Furth EE, Taylor JK, Schuck T, Chiou T and Traber PG: CDX1 protein expression in normal, metaplastic, and neoplastic human alimentary tract epithelium. *Gastroenterology* 113: 478-486, 1997.
- Mallo GV, Rechreche H, Frigerio JM, Rocha D, Zweibaum A, Lacasa M, Jordan BR, Dusetti NJ, Dagorn JC and Iovanna JL: Molecular cloning, sequencing and expression of the mRNA encoding human Cdx1 and Cdx2 homeobox. Down-regulation of Cdx1 and Cdx2 mRNA expression during colorectal carcinogenesis. *Int J Cancer* 74: 35-44, 1997.
- Sakai H, Eishi Y, Li XL, Akiyama Y, Miyake S, Takizawa T, Konishi N, Tatematsu M, Koike M and Yuasa Y: PDX1 homeobox protein expression in pseudopyloric glands and gastric carcinomas. *Gut* 53: 323-330, 2004.
- Munoz N: Epidemiological aspects of oesophageal cancer. *Endoscopy* 25: 609-612, 1993.
- Cameron AJ: Epidemiology of columnar-lined esophagus and adenocarcinoma. *Gastroenterol Clin North Am* 26: 487-494, 1997.
- Fujita H: Present status of esophageal cancer and its treatment in Japan. *Ann Thorac Cardiovasc Surg* 10: 135-139, 2004.
- Fujita H, Kakegawa T, Yamana H, Shima I, Toh Y, Tomita Y, Fujii T, Yamasaki K, Higaki K and Noake T: Mortality and morbidity rates, postoperative course, quality of life, and prognosis after extended radical lymphadenectomy for esophageal cancer. Comparison of three-field lymphadenectomy with two-field lymphadenectomy. *Ann Surg* 222: 654-662, 1995.
- Kodama M and Kakegawa T: Treatment of superficial cancer of the esophagus: a summary of responses to a questionnaire on superficial cancer of the esophagus in Japan. *Surgery* 123: 432-439, 1998.
- Takahashi Y, Hamada J, Murakawa K, Takada M, Tada M, Nogami I, Hayashi N, Nakamori S, Monden M, Miyamoto M, Katoh H and Moriuchi T: Expression profiles of 39 HOX genes in normal human adult organs and anaplastic thyroid cancer cell lines by quantitative real-time RT-PCR system. *Exp Cell Res* 293: 144-153, 2004.
- Yahagi N, Kosaki R, Ito T, Mitsuhashi T, Shimada H, Tomita M, Takahashi T and Kosaki K: Position-specific expression of Hox genes along the gastrointestinal tract. *Congenit Anom (Kyoto)* 44: 18-26, 2004.
- Chen KN, Gu ZD, Ke Y, Li JY, Shi XT and Xu GW: Expression of 11 HOX genes is deregulated in esophageal squamous cell carcinoma. *Clin Cancer Res* 11: 1044-1049, 2005.
- Raman V, Martensen SA, Reisman D, Evron E, Odenwald WF, Jaffee E, Marks J and Sukumar S: Compromised HOXA5 function can limit p53 expression in human breast tumours. *Nature* 405: 974-978, 2000.
- Williams TM, Williams ME, Heaton JH, Gelehrter TD and Innis JW: Group 13 HOX proteins interact with the MH2 domain of R-Smads and modulate Smad transcriptional activation functions independent of HOX DNA-binding capability. *Nucleic Acids Res* 33: 4475-4484, 2005.
- Shen WF, Krishnan K, Lawrence HJ and Largman C: The HOX homeodomain proteins block CBP histone acetyltransferase activity. *Mol Cell Biol* 21: 7509-7522, 2001.
- Phillips RW, Frierson HF Jr and Moskaluk CA: Cdx2 as a marker of epithelial intestinal differentiation in the esophagus. *Am J Surg Pathol* 27: 1442-1447, 2003.
- Domon-Dell C, Schneider A, Moucadel V, Guerin E, Guenet D, Aguillon S, Duluc I, Martin E, Iovanna J, Launay JF, Duclos B, Chenard MP, Meyer C, Oudet P, Kedinger M, Gaub MP and Freund JN: Cdx1 homeobox gene during human colon cancer progression. *Oncogene* 22: 7913-7921, 2003.
- Tabaries S, Lapointe J, Besch T, Carter M, Woollard J, Tuggle CK and Jeannotte L: Cdx protein interaction with Hoxa5 regulatory sequences contributes to Hoxa5 regional expression along the axial skeleton. *Mol Cell Biol* 25: 1389-1401, 2005.