

Impact of stereotactic body radiotherapy on colorectal cancer with distant metastases

MASAYUKI HIRAKI¹, JUNICHI NISHIMURA¹, MASAHISA OHTSUKA¹, HIROYA SHIOMI³,
MAMORU UEMURA¹, NAOTSUGU HARAGUCHI¹, TAISHI HATA¹, TARO HAYASHI⁴,
ICHIRO TAKEMASA¹, TSUNEKAZU MIZUSHIMA¹, FUMIAKI ISOHASHI²,
YASUO YOSHIOKA², KAZUHIKO OGAWA², YUICHIRO DOKI¹,
MASAKI MORI¹ and HIROFUMI YAMAMOTO¹

Departments of ¹Gastroenterological Surgery, ²Radiation Oncology, Graduate School of Medicine, Osaka University, Osaka 565-0871; Departments of ³Radiation Oncology, ⁴Surgical Oncology, Saito Yukoukai Hospital, Osaka 567-0085, Japan

Received September 2, 2013; Accepted October 11, 2013

DOI: 10.3892/or.2013.2871

Abstract. Stereotactic radiotherapy is a minimally invasive technique for delivering highly focused ionizing radiation with extreme precision. This technique was initially developed in neurosurgical practice and applied to extracranial lesions in the 1990s, and was termed stereotactic body radiotherapy (SBRT). Studies have reported that the resection of distant metastases from colorectal cancer (CRC) contributes to relatively long-term survival. However, the resection of pulmonary and liver metastases is not possible for various reasons. SBRT offers a therapeutic alternative to unresectable metastatic lesions. The present study describes three cases of distant metastasis from CRC that exhibited a complete response (CR) to SBRT. Case 1 is a 70-year-old man with recurrent liver metastases after surgery for rectal cancer with liver metastasis (S3: diameter 1.8 cm and volume 3.0 ml; S6: diameter 1.3 cm and volume 1.2 ml). Cases 2 and 3 were 65-year-old and 70-year-old men, respectively. Both patients had pulmonary metastasis after surgery for rectal and cecum cancer (Case 2: diameter 1.2 cm

and volume 0.9 ml; Case 3: diameter 0.8 cm and volume 0.27 ml). All cases were moderately differentiated adenocarcinomas. No serious adverse side-effects were observed during the therapy. CR was obtained in all patients on the basis of computed tomography 15-33 months after radiotherapy. Our experience supports that SBRT is a safe and alternative technique for resection in patients with distant metastasis from CRC who have small metastatic tumor volume.

Introduction

The accuracy of radiation treatment has improved with recent advances in the capacity for information processing. Neurosurgeon Lars Leksell developed the first stereotactic technique for brain lesions; he described the use of directed narrow beams of radiant energy to achieve local destruction of undesirable brain tumor tissue (1). This therapy differs from conventional radiotherapy, which involves exposing large areas of intracranial tissue to relatively broad fields of radiation over a number of sessions, and is a minimally invasive technique for the accurate delivery of highly focused ionizing radiation with a minimal effect on normal surrounding structures over a short treatment period.

This stereotactic technique was applied to extracranial lesions in the 1990s. Blomgren *et al* (2) first reported the successful use of hypofractionated, stereotactic, high-dose radiation therapy for the treatment of extracranial malignancies such as solitary tumors of the liver, lung or retroperitoneal space. Stereotactic body radiotherapy (SBRT) is increasingly indicated for various types of tumors, including primary or metastatic peripheral lung cancer, hepatocellular carcinoma, metastatic liver tumors, recurrent abdominal and pelvic tumors and bone metastases (3-5).

SBRT has already been reported to be safe and feasible for the curative treatment of patients with operable stage I non-small cell lung cancer (NSCLC). Local control and the overall survival rate in 5 years after SBRT were potentially comparable to surgery (6). Local control rates in

Correspondence to: Dr Hirofumi Yamamoto, Department of Gastroenterological Surgery, Graduate School of Medicine, Osaka University, 2-2 Yamada-oka, Suita-City, Osaka 565-0871, Japan
E-mail: hyamamoto@gesurg.med.osaka-u.ac.jp

Abbreviations: SBRT, stereotactic body radiotherapy; CRC, colorectal cancer; NSCLC, non-small cell lung cancer; CR, complete response; S3, ventrolateral segment of left hepatic lobe; S6, posteroinferior segment of right hepatic lobe; CT, computed tomography; PET, positron emission tomography; GTV, gross tumor volume; CTV, clinical target volume; ITV, internal target volume; PTV, planning target volume; SLAR, super-low anterior resection; PD, progressive disease; PR, partial response; TPE, total pelvic exenteration

Key words: stereotactic body radiotherapy, colorectal cancer, distant metastasis, local control

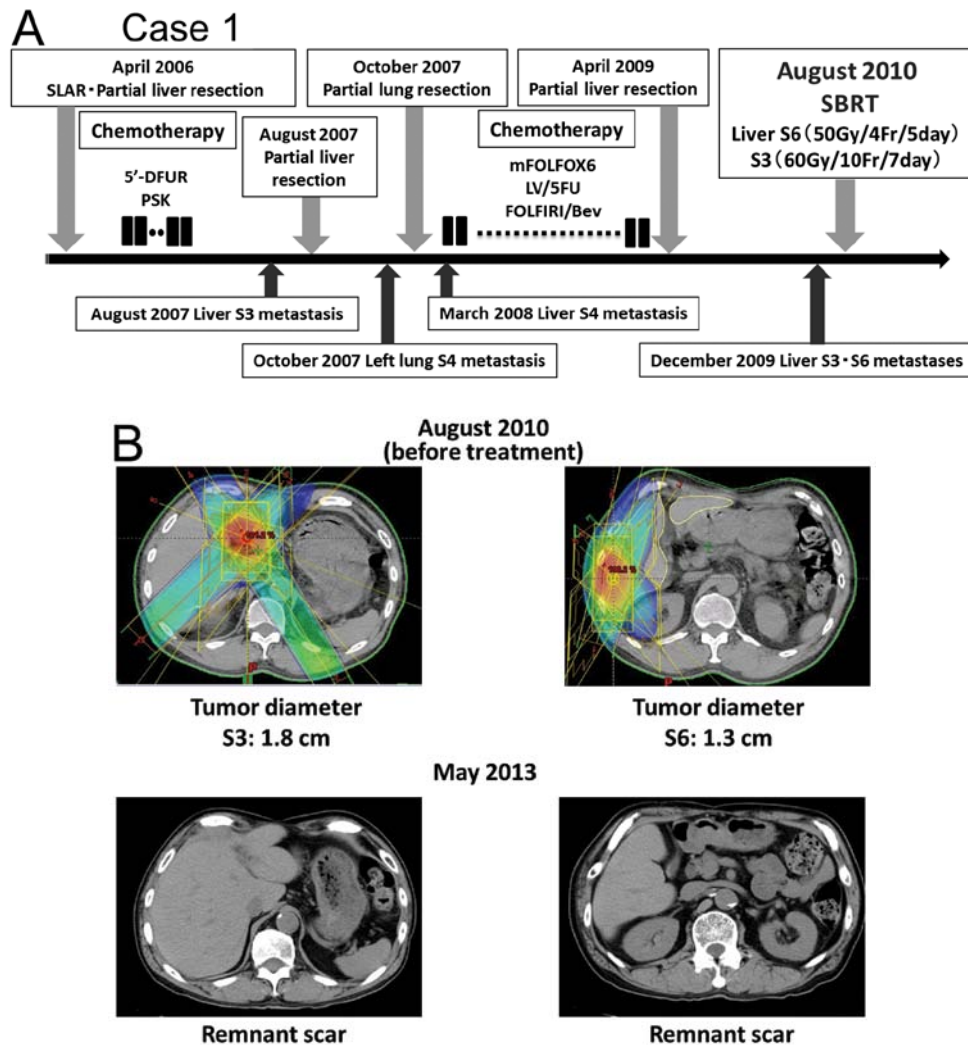


Figure 1. Summary of Case 1. (A) Course of treatment after surgical resection. (B) CT scan image shows that the two liver metastases on S3 (tumor diameter, 1.8 cm) and S6 (tumor diameter, 1.3 cm) were absent after SBRT. SBRT, stereotactic body radiotherapy.

pulmonary oligometastases range from 67 to 96% at 2 years (7). Habermehl *et al* (8) reported that local control rates in liver metastases, including colorectal adenocarcinoma, breast cancer, pancreatic adenocarcinoma and ovarian cancer are 87, 69 and 59% after 6, 12, and 18 months, respectively.

Studies have reported that complete resection of pulmonary and liver metastases derived from CRC is associated with relatively long-term survival (9-11); thus, sequential resection is warranted in a select group of patients. However, surgical treatment may be difficult for various reasons, such as repeated surgery, poor general condition of the patient and refusal of surgery. SBRT offers a minimally invasive and precise alternative for such cases. We report the successful treatment of three patients with four CRC metastases using SBRT. SBRT is a safe and alternative technique with which to resect pulmonary and liver metastases.

Materials and methods

At our institute, the indications for SBRT treatment of colorectal oligometastases using a linac system (Siemens Industry Inc., ONCOR Impression Plus: Osaka University;

Varian Inc., Trilogy: Saito Yukoukai Hospital) are histologically confirmed colorectal adenocarcinoma, radical resection of the primary tumor, inoperable tumors as assessed by a trained surgeon, tumors not amenable to another local treatment or patient refusal to undergo surgery, progression or stable disease after chemotherapy for recurrence, the presence of one to three lesions confined to one organ as determined by CT or PET/CT, and the maximum diameter of the largest lesion is 5 cm on CT.

Gross tumor volume (GTV) was identified and contoured on each axial CT image. GTV was considered to be equal to the clinical target volume (CTV). Next, we determined the internal target volume (ITV) by summing the CTVs of all CT scan images, including both the CVT in the inspiratory phase and in the expiratory phase. Planning target volume (PTV) was defined as the ITV plus a setup margin of 5 mm in all directions. The maximum moving distance of the tumor was determined in the x-, y- and z-axis directions using four-dimensional CT. When the maximum value was >1 cm, we often use respiratory gating. The tumor must be within the PTV under the on-board image (OBI) before irradiation and the beam must irradiate the target tumor in the expiratory

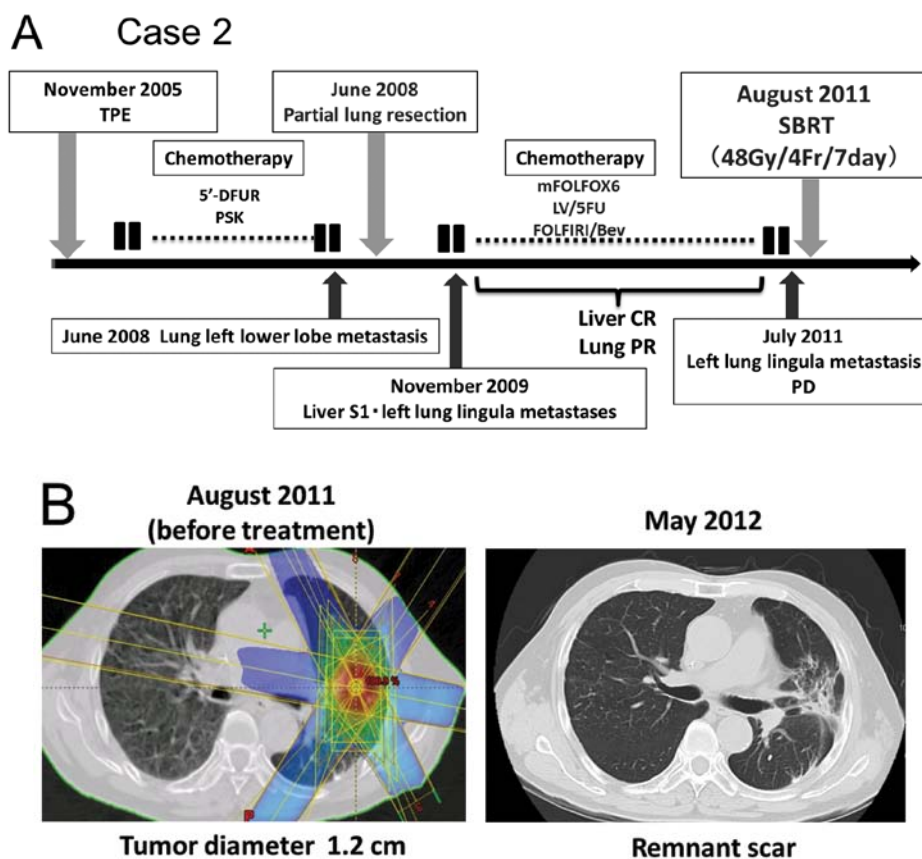


Figure 2. Summary of Case 2. (A) Course of treatment after surgical resection. (B) CT scan image shows that the left lung metastasis (tumor diameter, 1.2 cm) was absent after SBRT. SBRT, stereotactic body radiotherapy.

phase. Critical structures, such as the esophagus, spinal cord and trachea, are avoided by contouring. The radiation dose varies according to lesion site.

Results

Case 1. A 70-year-old man with lower rectal cancer and liver metastasis (stage IV) underwent super-low anterior resection (SLAR) and partial liver resection for S6 in April 2006 (Fig. 1A). The tumor was a moderately differentiated adenocarcinoma. Adjuvant chemotherapy with 5'-DFUR and PSK was administered after surgery. During chemotherapy, the recurrent tumor appeared on S3 in the liver, and the patient underwent a second partial liver resection. Two months after surgery, the metastatic tumor appeared on S4 in the left lung, and the patient underwent a partial lung resection. Five months later, the metastatic tumor appeared on S4 in the liver. Systemic chemotherapy with mFOLFOX6, followed by LV/5FU and FOLFIRI/bevacizumab, was administered. Because the tumor exhibited progressive disease (PD), the patient underwent a third partial liver resection. In December 2009, the patient had two liver metastases on S3 (tumor diameter 1.8 cm and volume 3.0 ml) and S6 (tumor diameter 1.3 cm and volume 1.2 ml) (Fig. 1B). Due to repeated surgery and the patient's refusal to undergo surgery, SBRT (60 Gy/10 Fr and 50 Gy/4 Fr) was performed for the liver metastases in August 2010. No adverse events were observed during the radiotherapy and the patient completed the treatment. In May 2013, 33 months after

the therapy, a CT scan revealed CR of the liver metastases (Fig. 1B). As of June 2013, the patient has not had a recurrent tumor.

Case 2. In November 2005, a 65-year-old man with advanced upper rectal cancer infiltrating the bladder and seminal vesicles (stage IIIC) underwent total pelvic exenteration (TPE) with complete resection (Cur A) (Fig. 2A). The tumor was a moderately differentiated adenocarcinoma. Adjuvant chemotherapy with 5'-DFUR and PSK was administered after surgery. Seven months after surgery, pulmonary metastasis appeared on the left lower lobe and the patient underwent partial lung resection. In November 2009, metastatic tumors appeared on S1 in the liver and the lingula of the left lung. After systemic chemotherapy with mFOLFOX6, followed by LV/5FU and FOLFIRI/bevacizumab for approximately 12 months, the patient experienced CR of the liver metastasis and PR of the lung metastasis. However, in July 2011, CT showed that the left lung metastasis volume had increased (tumor diameter 1.2 cm and volume 0.9 ml) (Fig. 2B). Due to repeated surgery and PD in the metastatic pulmonary tumor after systemic chemotherapy, SBRT (48 Gy/4 Fr) was performed for the lung metastasis in August 2011. In May 2012, 9 months after the therapy, CT showed CR of the lung tumor (Fig. 2B). As of July 2013, the patient has not had a recurrent tumor.

Case 3. In July 2007, a 70-year-old man with advanced cecum cancer underwent ileocecal resection (Fig. 3A). The tumor

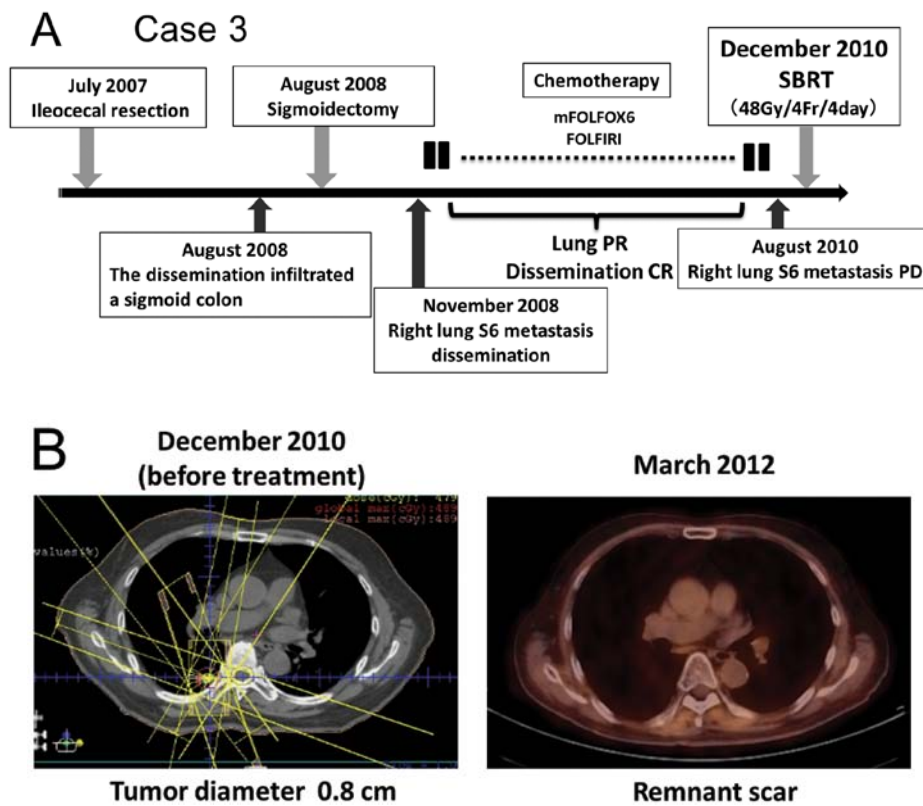


Figure 3. Summary of Case 3. (A) Course of treatment after surgical resection. (B) PET/CT scan image shows that the right lung metastasis (tumor diameter 0.8 cm) was absent after SBRT. SBRT, stereotactic body radiotherapy.

was a moderately differentiated adenocarcinoma (stage II). In August 2008, a dissemination lesion that infiltrated the sigmoid colon developed and the patient underwent sigmoidectomy. Seven months after surgery, recurrent dissemination and right lung metastasis appeared on S6. After systemic chemotherapy with mFOLFOX6, followed by FOLFIRI, the patient experienced CR of the dissemination and PR of the lung metastasis. However, in August 2010, CT showed that the volume of the right lung metastasis increased (tumor diameter 0.8 cm and volume 0.27 ml) (Fig. 3B). Due to the patient's refusal of surgery and PD in the metastatic lung tumor after systemic chemotherapy, SBRT (48 Gy/4 Fr) was performed for the lung metastasis in December 2010. A PET/CT scan 15 months after therapy revealed CR of the lung tumor (Fig. 3B). The patient died of CRC in December 2012.

Discussion

SBRT is a minimally invasive radiation technology that can provide a large dose of highly focused ionizing radiation to the target tumor and reduce normal tissue toxicity. The therapy for CRC oligometastasis was performed using fractionated irradiation of 50 Gy/4 Fr and 60 Gy/10 Fr for Case 1, 48 Gy/4 Fr for Case 2, and 48 Gy/4 Fr for Case 3. SBRT was performed in three patients with distant metastases after surgical resection for primary CRC, one liver metastases and two pulmonary metastases. All patients had CR during a follow-up period of 15 to 33 months as evidenced by CT. No adverse events were detected during the therapy.

Oligometastasis is described as a distant extension of a primary cancer at an isolated site or less than five sites of metastasis (12). Hellman *et al* (13) reported that the control of both the primary tumor and the oligometastatic lesion leads to long-term survival in various types of cancers. Thus, the local control of metastatic focus is particularly important.

To date, surgical resection has been the standard therapy for liver and lung oligometastases. As for CRC, Salah *et al* (14) reported that the 5-year survival rate is 52% for patients who have one metastasectomy for pulmonary metastasis and 57.9% for patients who have a second metastasectomy. In addition, Kobayashi *et al* (9) reported that patients with metastases derived from CRC who undergo both pulmonary and hepatic resection have a 3-year survival rate of 36±8%, a 5-year survival rate of 31±8% and an 8-year survival rate of 23±9%. A significant difference was found in the cumulative survival of patients with a solitary pulmonary metastasis compared to patients with multiple pulmonary metastases. Thus, the resection of CRC oligometastases is associated with long-term survival.

However, surgical resection may be difficult for various reasons, such as repeated surgery, the poor general condition of the patient and refusal of surgery. According to the National Comprehensive Cancer Network (NCCN) guidelines, SBRT should not be used in place of surgical resection for CRC (15). However, SBRT was recently reported to be useful for CRC oligometastases and to offer a new treatment alternative for cases of repeated surgery, systemic complications and refusal to undergo surgery (16-18). According to the Japanese Society

for Therapeutic Radiology and Oncology (JASTRO), the adaptation of SBRT in metastatic liver or pulmonary tumors requires a diameter <5 cm and fewer than three sites for other lesions (19). Our three cases of CRC oligometastasis adapted well to SBRT.

Bae *et al* (16) retrospectively compared the local control rate and overall survival of patients with distant CRC metastases who were treated with SBRT and reported that only a cumulative GTV <17 ml is a significantly favorable prognostic factor for the local control rate, and that no significant factor affects overall survival. A phase II study of SBRT in CRC metastases was conducted by Hoyer *et al* (17), who showed that actuarial local control was 86 and 63% at 2 years in a tumor- and patient-based analysis, respectively, and that overall survival was 67, 38, 22, 13 and 13% after 1, 2, 3, 4 and 5 years, respectively. The largest metastasis being <35 mm was significantly related to better overall survival. However, patients with a tumor diameter <35 mm did not have a significantly increased risk of local recurrence compared to patients with smaller metastases. Kang *et al* (18) retrospectively evaluated the feasibility and efficacy of SBRT for CRC oligometastases and reported that the 5-year overall survival and local control rates were 29 and 19%, respectively, and that a cumulative GTV <23 ml was a significantly favorable prognostic factor for the local control rate and overall survival. Thus, SBRT provides therapeutic benefits to select patients.

In our cases, the oligometastatic volume in the liver and lung was much smaller than 17 ml and the diameter was less than 35 mm. The eligibility criteria of SBRT for distant CRC metastases must be defined by large-scale clinical trials.

In conclusion, SBRT is a promising treatment associated with a more favorable prognosis for patients with distant CRC metastases that are unresectable due to repeated surgery, poor general condition of the patient, or refusal to undergo surgery. This therapy may be one of the feasible treatments for CRC with distant metastases.

References

1. Leksell L: The stereotaxic method and radiosurgery of the brain. *Acta Chir Scand* 102: 316-319, 1951.
2. Blomgren H, Lax I, Naslund I and Svanstrom R: Stereotactic high dose fraction radiation therapy of extracranial tumors using an accelerator. Clinical experience of the first thirty-one patients. *Acta Oncol* 34: 861-870, 1995.
3. Wulf J, Hadinger U, Oppitz U, Olshausen B and Flentje M: Stereotactic radiotherapy of extracranial targets: CT-simulation and accuracy of treatment in the stereotactic body frame. *Radiother Oncol* 57: 225-236, 2000.
4. Herfarth KK, Debus J, Lohr F, *et al*: Stereotactic single-dose radiation therapy of liver tumors: results of a phase I/II trial. *J Clin Oncol* 19: 164-170, 2001.
5. Uematsu M, Shioda A, Suda A, *et al*: Computed tomography-guided frameless stereotactic radiotherapy for stage I non-small cell lung cancer: a 5-year experience. *Int J Radiat Oncol Biol Phys* 51: 666-670, 2001.
6. Onishi H, Shirato H, Nagata Y, *et al*: Stereotactic body radiotherapy (SBRT) for operable stage I non-small-cell lung cancer: can SBRT be comparable to surgery? *Int J Radiat Oncol Biol Phys* 81: 1352-1358, 2011.
7. Siva S, MacManus M and Ball D: Stereotactic radiotherapy for pulmonary oligometastases: a systematic review. *J Thorac Oncol* 5: 1091-1099, 2010.
8. Habermehl D, Herfarth KK, Bermejo JL, *et al*: Single-dose radiosurgical treatment for hepatic metastases - therapeutic outcome of 138 treated lesions from a single institution. *Radiat Oncol* 8: 175, 2013.
9. Kobayashi K, Kawamura M and Ishihara T: Surgical treatment for both pulmonary and hepatic metastases from colorectal cancer. *J Thorac Cardiovasc Surg* 118: 1090-1096, 1999.
10. Lehnert T, Knaebel HP, Duck M, Bulzebruck H and Herfarth C: Sequential hepatic and pulmonary resections for metastatic colorectal cancer. *Br J Surg* 86: 241-243, 1999.
11. Hamy A, Baron O, Bennouna J, Roussel JC, Paineau J and Douillard JY: Resection of hepatic and pulmonary metastases in patients with colorectal cancer. *Am J Clin Oncol* 24: 607-609, 2001.
12. Milano MT, Katz AW, Zhang H and Okunieff P: Oligometastases treated with stereotactic body radiotherapy: long-term follow-up of prospective study. *Int J Radiat Oncol Biol Phys* 83: 878-886, 2012.
13. Hellman S and Weichselbaum RR: Oligometastases. *J Clin Oncol* 13: 8-10, 1995.
14. Salah S, Watanabe K, Park JS, *et al*: Repeated resection of colorectal cancer pulmonary oligometastases: pooled analysis and prognostic assessment. *Ann Surg Oncol* 20: 1955-1961, 2013.
15. Clinical Practice Guidelines in Oncology (version 3.2013) provided by the National Comprehensive Cancer Network (NCCN). http://www.nccn.org/professionals/physician_gls/pdf/colon.pdf.
16. Bae SH, Kim MS, Cho CK, *et al*: High dose stereotactic body radiotherapy using three fractions for colorectal oligometastases. *J Surg Oncol* 106: 138-143, 2012.
17. Hoyer M, Roed H, Traberg Hansen A, *et al*: Phase II study on stereotactic body radiotherapy of colorectal metastases. *Acta Oncol* 45: 823-830, 2006.
18. Kang JK, Kim MS, Kim JH, *et al*: Oligometastases confined one organ from colorectal cancer treated by SBRT. *Clin Exp Metastasis* 27: 273-278, 2010.
19. SBRT guideline provided by Japanese Society for Therapeutic Radiology and Oncology (JASTRO). <http://www.jastro.or.jp/guideline/>.