

Primary non-Hodgkin's lymphoma of the spine with neurologic compression treated by radiotherapy and chemotherapy alone or combined with surgical decompression

XINSHENG PENG¹, YONG WAN¹, YINGMING CHEN², LIYAN CHEN¹, AISHAN HE¹, WEIMING LIAO¹, JINGNAN SHEN¹, QIZHEN FU¹, SHIYING HAN¹, FOBAO LI¹ and XUENONG ZOU¹

Departments of ¹Orthopaedic Surgery and ²Radiology, The First Affiliated Hospital of Sun Yat-sen University, 510080 Guangzhou, Guangdong Province, P.R. China

Received January 2, 2009; Accepted February 23, 2009

DOI: 10.3892/or_00000350

Abstract. Neurologic compression is a disastrous consequence for the patients with primary non-Hodgkin's lymphoma (NHL) of the spine, and such a condition has not been carefully taken into account in the treatment guidelines. The aim of this study was to compare the effect of radiotherapy and chemotherapy alone or combined with surgical decompression on primary NHL of the spine with neurologic compression. Sixteen patients with primary NHL in the vertebrae of the spine were treated between 1994 and 2006. Thirteen patients had neurologic compression. The neurologic deficits in 11 patients involved soft tissue extension from the vertebral tumors and 3 had vertebral fractures with motor signs and 5 had radicular pain. Five patients were treated by radiotherapy and chemotherapy alone while 8 were combined with surgical decompression. The decompression operation for tumors resulted in neurologic recovery in 6 patients. Five patients were not operated on but three received emergent radiotherapy before chemotherapy, 4 of whom had complete recovery in their neurologic symptoms. Of all patients, 3 relapsed. At average follow-up of 61.5 months (range 2-156 months), 4 patients had died after an average interval of 23.3 months from treatment (range 3-71 months). The 5-year overall survival rate was 82% with 60% for the patients in the surgical group, 100% for the patients in the non-surgical group. There was no difference between the groups ($\chi^2=3.559$, $P=0.059$). The 5-year overall survival was 100% for the 8 patients who completed CHOP chemotherapy and radiotherapy. It appears that optimum treatment in these patients depends on the cause of the neurologic deficits, whereas the survival is not influenced by the surgical or non-

surgical treatment. The results suggest that chemotherapy and radiotherapy alone is the ideal treatment for these patients whose neurologic compression was only due to soft tissue extension. The authors emphasize the importance of chemotherapy and radiotherapy followed by surgical decompression depending on individual priorities in the indications for operation on primary NHL of spine with neurologic compression.

Introduction

Primary non-Hodgkin's lymphoma (NHL) of the bone, often more simply referred to as primary lymphoma of bone (PLB), is a rare disease (1). The first case series with PLB was presented in 1939 by Parker and Jackson (2). The incidence of PLB is 7% of all malignant bone tumors, 4-5% of all extra-nodal NHL and less than 1% of all malignant lymphomas (3-5). PLB was found in bone and primary NHL of the spine from 9% (6) to 32% (7) of all PLB. Some authors reported neurologic compression occurring rarely in primary NHL of the spine (8); while others reported half of 42 patients with primary NHL of spine presented with spinal cord compression (7). However, the neurologic compression is a disastrous consequence for the patients with primary NHL of the spine and such a condition has to be taken carefully into account.

Various therapeutic regimens for primary NHL of PLB have been proposed, included irradiation alone, combination of irradiation and chemotherapy, and operative excision of the tumor combined with irradiation or chemotherapy. The optimum therapeutic regimen of this tumor when it occurs as a primary lesion of the spine is not known (9), especially for primary NHL of the spine with neurologic compression. In such a situation, most authors recommended surgical excision of the tumor in combination of irradiation and/or chemotherapy (7,9-14); a few recommended chemotherapy and/or radiotherapy (15). Because the investigations and therapeutic regimens have been formulated in case reports (12-18) and small case series in retrospective studies (9,11), it is still unclear which treatment is more suitable for the patients of primary NHL of the spine with neurologic compression.

Correspondence to: Dr X. Peng, The First Affiliated Hospital of Sun Yat-sen University, 58# Zhongshan 2nd Rd., 510080 Guangzhou, Guangdong Province, P.R. China
E-mail: pengxs66@tom.com

Key words: spine, non-Hodgkin's lymphoma, neurologic compression, chemotherapy, radiotherapy, surgery, survival

We report on a relatively large case series of 13 patients of primary NHL of the spine with neurologic compression who accepted either surgical excision in combination of chemotherapy and radiotherapy or non-surgical treatment modality of chemotherapy and radiotherapy. The purpose of the present study was to evaluate the outcome of these two therapeutic regimens, and to emphasize the implication of both surgical and non-surgical treatment modality on such conditions.

Materials and methods

Patients. All 16 patients of primary NHL of the spine at the First Affiliated Hospital of Sun Yat-sen University, Guangzhou, China, from January 1994 to December 2006 were retrospectively reviewed, and 13 patients of primary NHL of the spine with neurologic deficits were identified. Primary NHL of the spine was confirmed by the histopathologic diagnosis with spinal involvement as the primary site of disease. The patients were excluded if they had i) distant-site bone marrow involvement; ii) lymph node involvement on the other side of the diaphragm from the involved bone; and iii) other extranodal involvement such as peripheral blood, lung, liver or other organs not intimately involved with the known site of bone involvement where the patients had less than two years of follow-up. This study was approved by the institutional review boards of the individual institutions.

The clinical information from patients' medical records was reviewed. We collected data on the clinical presentation and neurologic function; peripheral complete blood cell counts, lactate dehydrogenase level and urinalysis; imaging features included primary site of disease, presence of a pathological fracture, spinal cord (including cauda equina or nerve root) compression, metastasis and stage; pathological diagnosis, treatment modality, the date of diagnosis and last follow-up, as well as cause of death if the patients died. Imaging investigation included plain radiographic and magnetic resonance imaging of the primary site, posteroanterior and lateral chest radiography, computed tomography of the chest, abdomen, and pelvis, and ultrasound of abdominal and pelvic as well. Most patients also underwent radionuclide technetium bone scanning. Pathologic examination was done with iliac crest bone marrow biopsy and biopsy from the involved spine.

Staging. Staging investigations performed varied over time and patients were staged retrospectively according to Ann Arbor staging classification (19). The patients were defined as stage IE disease with a single localized bone lesion, stage IIE disease with a single bony site and contiguous or closely associated lymph nodes, stage III disease with distant nodal disease, and stage IV disease with multiple sites of spine or bone involvement.

Treatment. With respect to various treatment strategies including radiotherapy, chemotherapy and surgery in various combinations, the treatment selection for patients were depended on their diagnosis, cause of spinal cord (including cauda equina or nerve root) compression (soft tissue, fracture

Table I. CHOP chemotherapeutic regimens.

Agent	Dose and usage
Cyclophosphamide	750 mg/m ² (d 1), i.v.
Vincristine	1.4 mg/m ² (d 1), i.v.
Adriamycin or pirarubicine	40-60 mg/m ² (d 1), i.v.
Prednisolone	80-100 mg/day (d 1-5), Oral

mg/m², dose per body surface area; i.v., intravenous.

or instability), and neurologic function. Except for the acceptance of the CHOP chemotherapy (Table I) and radiotherapy, the patients were divided into a group combined with surgery (n=8) or non-surgery (n=5). The patients who needed surgical treatment were determined by the progressive neurological deficits based on physician discretion.

Assessment of the response to the treatment was done clinically and radiologically. Patients who had a complete disappearance of their lesions or did not show an increase in the size of their lesions or an appearance of new lesions were considered to be 'complete clinical remission'. Patients presenting an increase in the size of their lesions or with an appearance of new lesions were considered to have a progressive disease.

Survival analysis. Overall survival time was calculated from the date of diagnosis until the date of last follow-up or until time of death from any cause. Patients alive without evidence of disease were censored on the date of their last follow-up and patients who died due to causes unrelated to lymphoma were censored at time of death. Survival curves were calculated according to the Kaplan and Meier method; survival analysis was performed using the log-rank test. Differences were considered significant at P<0.05 (two tailed). All survival analyses were performed using the SPSS software package for Windows (version 15, SPSS, Inc., Chicago, IL).

Results

Patient presentation. Clinical features of the 13 patients are summarized in Table II. The patients consisted of 12 males and 1 female. The age of the patients varied from 16 to 73 years (median 41.4). They presented in single vertebral involvement (7 patients) and multifocal spinal involvement (6 patients). The main involved site localized in the cervical spine (1 patient), thoracic spine (7 patients), and lumbar spine (5 patients). Eight patients received an open surgical biopsy (including 2 patients failed with CT-guided core needle biopsy), and 5 patients received CT-guided core needle biopsy.

The most common presenting complaints were pain and neurologic symptoms without antecedent trauma in all patients. The neurologic symptoms included paraplegia, paraparesis, radiculopathy and radicular pain. In surgical group, pathologic fracture developed in 4 patients at the primary site before treatment, and 2 patients were considered to have spinal

Table II. Clinical data on primary non-Hodgkin's lymphoma of spine with neurologic symptoms.

Patient	Age/Sex	Lesion sites (main site)	Neurologic symptoms	Cause of neurologic symptoms	Stage	Surgery	Chemotherapy	Irradiation (Gy)	Follow-up (m)	Clinical results
1	M/35	T8	Paraplegia (Frankel C)	STE	IE	Yes	CHOPx2	-	71	Died
2	M/20	T12	Paraplegia (Frankel C)	STE	IE	Yes	CHOPx6	40	135	Alive/NR
3	M/49	T5,8,11,12,L1,S1 (T12)	Paraplegia (Frankel A)	STE + Fracture	IV	Yes ^a	CHOPx1	-	8	Died
4	M/64	L5	Right radicular pain Radiculopathy of L5	STE	IE	Yes ^a	CHOPx7	-	12	Died ^b
5	M/71	L3	Radicular pain and paraplegia (Frankel C)	STE + Fracture	IE	Yes	CHOPx3	-	64	Alive/NR
6	F/73	T11-12,L2,5 (L5)	Radicular pain	STE	IV	Yes		-	2	Died
7	M/23	T9	Radicular pain and paraplegia (Frankel D)	STE + Fracture	IE	Yes	CHOPx6	20	59	Alive/NR
8	M/34	T3	Paraplegia (Frankel D)	STE	IE	Yes	CHOPx7	42	25	Alive/NR
9	M/21	C2	Paraplegia (Frankel C)	STE	IE	No	CHOPx6	45	156	Alive/NR
10	M/35	T11-12 (T11)	Paraplegia (Frankel C)	STE	IE	No	CHOPx6	45	90	Alive/NR
11	M/29	T6-12 (T7)	Paraplegia (Frankel B)	STE	IV	No	CHOPx5	40	83	Alive ^c
12	M/52	L1-3 (L2)	Radicular pain	STE	IE	No	CHOPx7	40	51	Alive/NR
13	M/16	T6,9,11,L2-5 (L5)	Weakness of legs (4/5)	STE	IV	No	CHOPx7	15	44	Alive/NR

STE, soft tissue extension. ^aOther Hospital. ^bNon-related disease. NR, neurologic normal. ^cParaplegia (Frankel B).

instability. The neurologic status was paraplegia in 6 patients (Frankel A in 1, Frankel C in 3, Frankel D in 2) with radicular pain in 2 patients, and radicular pain with radiculopathy in 1 patient. One patient only had radicular pain. Neurologic symptoms were mainly caused by soft tissue extension in 5 patients, and soft tissue extension and fracture in 3 patients (Fig. 1A). In non-surgical group, all patients presented soft tissue extension of their tumor, and pathologic fracture occurred in 1 patient; paraplegia in 3 patients (Frankel B in 1, Frankel C in 2) and weakness of lower extremity (4/5) in 1 patient. One patient only had radicular pain. Neurologic symptoms in all patients were mainly caused by soft tissue extension (Fig. 2A).

Clinical staging and recurrence. All patients of the clinical stage could be assigned. Nine patients presented with stage IE disease and 4 patients with stage IV disease (Table II). Three patients (patients 1, 11 and 12) recurred (Table III). One patient (patient 1) only received two cycles of chemotherapy after surgery. After relapse the patient was given four cycles of CHOP chemotherapy. This patient died 71 months from date of diagnosis. Although patients 11 and 12 completed chemotherapy and radiotherapy, the patients had no emergency radiotherapy, they only received radiotherapy following CHOP chemotherapy. With further combined treatments, the patients were in complete clinical remission at the latest follow-up.

Response to treatment and survival. In surgical group, 4 patients received anterior decompression and reconstruction; whereas another 4 patients only received posterior decompression. Two patients had their operation in other institutes (anterior decompression and reconstruction in patient 3 and posterior decompression in patient 4). Of this group, 7 patients combined with CHOP chemotherapy, received one cycle in 1 patient, two cycles in 1 patient, three cycles in 1 patient, six cycles in 2 patients, and seven cycles in 2 patients. Radiotherapy was added in 3 of those 7 patients. Total doses ranged from 20 to 42 Gy. One patient gave up further management after surgery. The neurologic function of 6 patients gradually recovered after neurologic decompression. The patients, except for patient 6 who gave up either radiotherapy or chemotherapy postoperatively, recovered to normal neurologic function 6 months after treatment. The other 2 patients (patients 3 and 4), who had operation in other institutes, did not get neurologic recovery. Patient 3 gave up treatment after first chemotherapy cycle.

In non-surgical group, all patients received CHOP chemotherapy and radiotherapy, five cycles in 1 patient, six cycles in 2 patients, and seven cycles in 2 patients. Total doses of radiotherapy ranged from 15 to 45 Gy. The regimens of chemotherapy and radiotherapy were different in individual patients. Three patients with neurologic deficits (patients 9, 10 and 13) received total doses, from 12 to 15 Gy, of radiotherapy to first release the neurologic compression and dexamethasone (20-30 mg per day x 5) to prevent and reduce swelling of spinal cord. Following radiotherapy, chemotherapeutic drugs were given. The doses of radiotherapy were boosted in 2 patients (patients 9 and 13). The boost dose of radiotherapy in patient 10 was given between

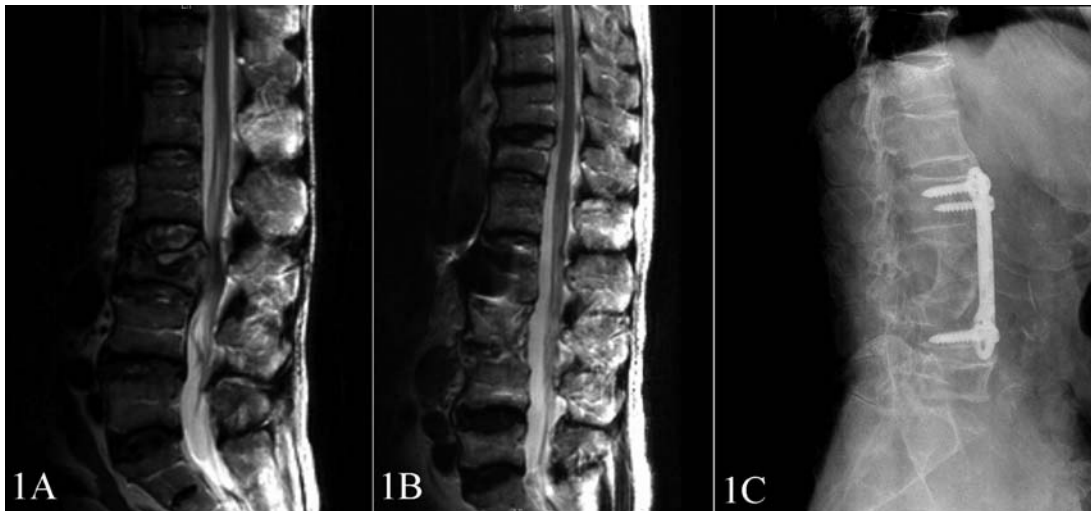

Figure 1. Results of primary non-Hodgkin's lymphoma of L3 treated by surgery and chemotherapy (case 5). (A) MRI views (T2-weighted) show the prominent fracture vertebra with soft tissue mass intruding the spinal canal and compressing the equina cauda. (B) MRI views (T2-weighted) show equina cauda is decompressed completely and no evidence of tumor exists 5 years after treatment. (C) Radiogram shows bone fuse and no evidence of tumor exists 5 years after treatment.

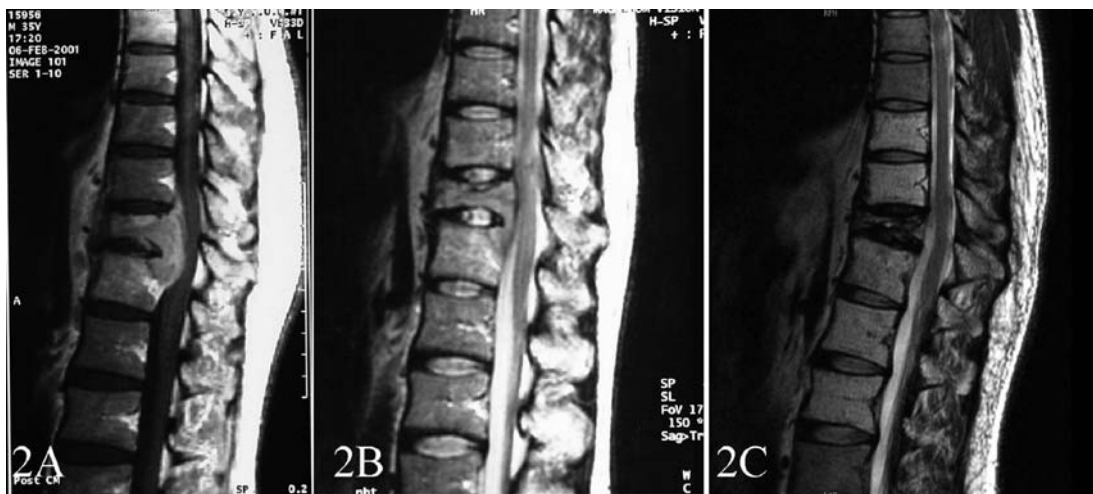


Figure 2. Results of primary non-Hodgkin's lymphoma of T11-12 treated by radiotherapy and chemotherapy (case 10). (A) MRI views (T1-weighted with gadolinium enhanced image) show the prominent extension of soft tissue into the spinal canal and compression of the spinal cord. (B) MRI views (T2-weighted) show spinal cord is decompressed 24 days after radiotherapy and chemotherapy. (C) MRI views (T2-weighted) show spinal cord is decompressed completely and no evidence of tumor exists 6 years after treatment.

chemotherapy cycles. Two patients (patients 11 and 12) received only radiotherapy following CHOP chemotherapy. This was because the diagnosis of patient 11 was delayed until three weeks after severe neurologic deficit (Frankel B) and patient 12 only had radicular pain. There was no patient transferred to surgical treatment in non-surgical group. Patients 9, 10 and 13 made a gradual remission from the neurologic deficits after emergency radiotherapy and achieved complete remission 6 months after treatment. The radicular pain of patient 12 relieved after the first chemotherapy cycle. The MRI image showed that the soft tissue extension disappeared and spinal cord was decompressed after the chemotherapy and radiotherapy (Fig. 2B). The neurologic function of patient 11 had no recovery.

The median follow-up of all patients was 61.5 months, ranging from 2 to 156 months. The 5-year overall survival rate was 82% with 60% for the patients in the surgical group, 100% for the patients in the non-surgical group (Fig. 3). There was no difference between the groups ($\chi^2=3.559$, $P=0.059$). Nine patients are alive at the latest follow-up (69.2%), in whom 8 patients completed at least five cycles of CHOP chemotherapy and radiotherapy. The 5-year overall survival was 100% for the 8 patients who completed CHOP chemotherapy and radiotherapy. Four patients died during follow-up. The cause of death was primary refractory disease, in which 3 patients (patients 1, 3 and 6) did not receive regular chemotherapy and radiotherapy, and unrelated to primary NHL of spine in 1 patient (patient 4). All living patients achieved complete clinical remission at the latest follow-up (Figs. 1B, C and 2C).

Table III. Clinical data of three recurrent patients.

Patient	Primary site	Relapse site	Relapse time (m)	Treatment after relapse
1	T8	T8, S1-2	24	CHOPx4
11	T6-12 (T7)	T10-12	54	CHOPx6, RT=50 Gy
12	L1-3 (L2)	L1-3, bone marrow	12	R-CHOPx6, RT=20 Gy marrow transplantation

RT, radiotherapy; R, rituximab; M, months.

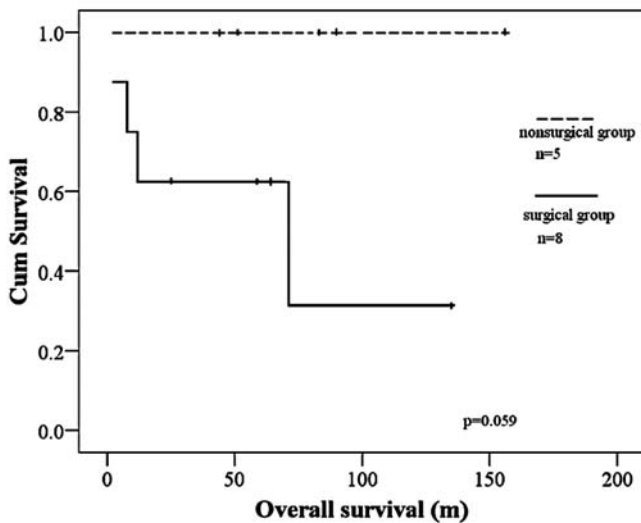


Figure 3. Overall survival in patients with primary NHL of the spine with neurologic compression treated by chemotherapy and radiotherapy alone or combined with surgical decompression.

Discussion

Primary NHL of the spine is a rare extranodal lymphoma. There is no optimum treatment guideline for this tumor (9), especially with neurologic compression. In this study, we showed that the non-surgical treatment with chemotherapy and radiotherapy was able to rapidly reduce spinal cord and nerve root compression due to intraspinal soft tissue extension. Four of 5 patients had complete recovery of the neurologic function and radicular pain release. The 5-year overall survival was 100% for the patients in the non-surgical group. In combination of surgical decompression and/or chemotherapy and radiotherapy, 6 out of 8 patients gradually recovered neurologic function and had reduced radicular pain after neurologic decompression. The 5-year overall survival was 60%. There was no difference between the groups.

For primary NHL of the spine with neurologic compression, most authors recommended surgical excision of the tumor combined with irradiation and/or chemotherapy. Delamarter *et al* (10) reported on two cases who had excision of the tumor in combination with irradiation and chemotherapy for the treatment of histiocytic lymphoma of the spine. Shehata *et al* (17) described a patient suffering from a

small-cell lymphocytic lymphoma of the spine treated with local resection, stabilization of the spine using of a ribstrut graft and methylmethacrylate, and radiochemotherapy. The patient had a stable spine eleven years after the operation. Vaughan *et al* (9) reported 3 patients with neurological abnormalities as well as severe destruction and collapse of a vertebral body at the time of presentation. The patients were managed with decompression and reconstruction and had a pain-free, stable spine with no or only slight neurological abnormalities at the most recent follow-up. Ford *et al* (11) reported 2 patients with vertebral disease who received spinal decompression and stabilization before chemotherapy and radiotherapy. Although Ramadan *et al* (7) retrospectively reported the outcomes of 131 patients with PLB including 21 patients who presented with spinal cord compression; they did not indicate how to treat the patients with spinal cord compression. In this study, our experience is that surgery is necessary when the neurologic function can not be recovered shortly after chemotherapy and radiotherapy, due to spinal instability, or neurologic deficits caused by fracture. After surgery, combined chemotherapy and radiotherapy needs to be performed. To the best of our knowledge, this is the largest case series to address treatment of primary NHL of the spine with neurologic compression.

Although the combination of chemotherapy and radiotherapy was proposed as optimum treatment for PLB lesions and lymph system involvements (6,20-23), there was no evidence whether the combined modality is a good option in the management of primary NHL of the spine with neurologic compression. The clinical results in this series indicate that the non-surgical combination of chemotherapy and radiotherapy is effective to treat patients with primary NHL of the spine with neurologic compression by soft tissue extension. These results are consistent with other reports. Székely *et al* (24) managed 4 patients of epidural malignant lymphomas with a non-surgical method. Of the chemotherapy and radiotherapy treated cases, three out of the four experienced improvement in neurological symptoms, which in proportion was no worse than the operative cases (10 out of 13). Pels *et al* (25) treated a primary lymphoplasmacytoid lymphoma of the thoracic cord with focal radiotherapy (30 Gy) and three cycles of chemotherapy consisting of procarbazine, lomustine and vincristine. Complete tumor response and partial recovery of neurologic symptoms were achieved. Baar *et al* (15) reported one primary NHL of the spine with spinal cord compression treated with radiotherapy to the primary lesion, followed by chemotherapy. The patient is alive 7 months from the beginning of treatment. Although Laing *et al* (26) reported all 13 patients of NHL with epidural compression were treated with surgical decompression, they concluded that major decompressive surgery should be avoided in elderly patients, and treatment should consist of steroids and radiotherapy alone.

In the current study, we showed a combination of chemotherapy and radiotherapy is important to manage primary NHL of the spine with neurologic compression. To release the spinal cord compression quickly, radiotherapy needs to be used first, followed by chemotherapy. Using this regimen, we treated 3 patients who all recovered neurologic function completely. Rubin *et al* (27) reported rapid high doses of

irradiation alone could achieved spinal cord decompression of epidural lymphoma. The degree of neurologic deficits and causes of compression are the other factors that need to be considered when opting for non-surgical management modality. In our non-surgical group, one patient's neurologic function had no recovery due to delayed diagnosis with severe neurologic deficit (Frankel B) for three weeks. He did not receive radiotherapy. This indicated that rapid initiation of combined treatment is essential to achieve recovery of neurologic function.

Besides neurologic decompression, the fundamental goal of treatment is life extension of the patients with the best quality of life (24). As it was impossible to resect the lesion entirely, the role of surgery in primary lymphoma of bone is limited. Surgical resection of the primary bone neoplasm was not necessary for local control (28). Surgery was performed on an acute basis to obtain biopsy samples, to decompress the cord, to remove the majority of tumor masses, and to stabilize the spine (13). Our results also showed that surgical treatment could not improve survival time compared to non-surgical treatment. Although 3 patients had surgery, the consequence of the disease can be severe if the patients did not complete chemotherapy and radiotherapy. Of the 3 patients, 1 patient who presented stage IE disease only received two cycle chemotherapy after surgery and relapsed two years later at primary site and sacrum. This patient died 71 months after primary surgery. The other two presented stage IV disease. They gave up further treatment and died shortly after operation. Of the patients who completed at least five cycles of CHOP chemotherapy and radiotherapy, 8 of 9 are alive at the latest follow-up, and their 5-year overall survival was 100% regardless of surgical treatment. The results suggested that combined treatment modality is necessary and a combination of chemotherapy and radiotherapy was the ideal treatment for patients of primary NHL of the spine with neurological compression.

Several studies have supported that a combination of chemotherapy and radiotherapy was the optimal treatment for patients with PLB (29). Zinzani *et al* (20) reported an improvement in recurrence/survival with the use of chemotherapy versus radiation therapy alone. Rathmell *et al* (21) reported an improvement in recurrence/survival and overall survival with the use of combined modality therapy versus radiation therapy alone. Fidiyas *et al* (22) also reported on a group of 37 patients all treated with combined modality therapy and demonstrated an improved disease-free survival and overall survival when compared with historical controls who were treated with radiation therapy alone. Beal *et al* (6) reported on a group of 82 patients and concluded that PLB patients treated with a combination of chemotherapy and radiotherapy were found to have a significant better survival than the patients treated with single modality therapy (chemotherapy or radiotherapy alone). Baiocchi *et al* (23) emphasized the importance of combined-modality therapy for primary bone lymphoma.

The largest case series address treatment of primary NHL of the spine with neurologic compression. The results demonstrate that combined treatment modality is necessary and effectiveness to treat the patients of primary NHL of spine with neurologic compression by soft tissue extension.

The patients with the combined treatment modality can achieve a high 5-year survival rate. Surgical decompression is probably not necessary for the patients with intraspinal involvement by soft tissue extension alone. The results suggest that the combination of chemotherapy and radiotherapy is the ideal treatment for the patients with primary NHL of spine with neurologic compression by soft tissue extension, regardless of the surgical treatment.

Acknowledgements

This study was financially supported by the Provincial Nature Science Foundation of Guangdong, China (No. 06021290). The study was approved by the Institutional Ethical board (IRB) and written informed consent was obtained from the patients.

References

1. Glotzbecker MP, Kersun LS, Choi JK, Wills BP, Schaffer AA and Dormans JP: Primary non-Hodgkin's lymphoma of bone in children. *J Bone Joint Surg Am* 88: 583-594, 2006.
2. Parker F Jr and Jackson JH Jr: Primary reticulum cell sarcoma of bone. *Surg Gynecol Obstet* 68: 45-53, 1939.
3. Unni KK and Hogendoorn PCW: Malignant lymphoma. In: *World Health Organization Classification of Tumours: Pathology and Genetics of Tumours of Soft Tissue and Bone*. Fletcher CDM, Unni KK and Mertens F (eds). IARC Press, Lyon, pp306-308, 2002.
4. Freeman C, Berg J and Cutler S: Occurrence and prognosis of extranodal lymphomas. *Cancer* 29: 252-260, 1972.
5. Isaacson P and Norton A: Extranodal lymphoma in miscellaneous sites. In: *Extranodal Lymphomas*. Isaacson P and Norton A (eds). Churchill Livingstone, New York, pp289-298, 1994.
6. Beal K, Allen L and Yahalom J: Primary bone lymphoma: treatment results and prognostic factors with long-term follow-up of 82 patients. *Cancer* 106: 2652-2656, 2006.
7. Ramadan KM, Shenkier T, Sehn LH, Gascoyne RD and Connors JM: A clinicopathological retrospective study of 131 patients with primary bone lymphoma: a population-based study of successively treated cohorts from the British Columbia Cancer Agency. *Ann Oncol* 18: 129-135, 2007.
8. Vanneuville B, Janssens A, Lemmerling M, De Vlam K, Mielants H and Veys EM: Non-Hodgkin's lymphoma presenting with spinal involvement. *Ann Rheum Dis* 59: 12-14, 2000.
9. Vaughan JJ, Winter RB, Lonstein JE, Johnson JR and Dunnington JE: Non-Hodgkin lymphoma of the spine: a report of three cases with a minimum ten-year follow-up. *J Bone Joint Surg Am* 80: 104-110, 1998.
10. Delamarter RB, Sachs BL, Thompson GH, Bohlman HM, Maldey JT and Carter JR: Primary neoplasms of the thoracic and lumbar spine. An analysis of 29 consecutive cases. *Clin Orthop* 256: 87-100, 1990.
11. Ford DR, Wilson D, Sothi S, Grimer R and Spooner D: Primary bone lymphoma - treatment and outcome. *Clin Oncol (R Coll Radiol)* 19: 50-55, 2007.
12. Becker S, Babisch J, Venbrocks R, Katenkamp D and Wurdinger S: Primary non-Hodgkin lymphoma of the spine. *Arch Orthop Trauma Surg* 117: 399-401, 1998.
13. Klezl Z, Krbec M, Gregora E and Stritesky J: Rare presentation of non-Hodgkin lymphoma of the thoracolumbar spine in pregnancy with 7 years' survival. *Arch Orthop Trauma Surg* 122: 308-310, 2002.
14. Bassi G, Berlanda P, Pellegrino M and Roberto F: A rare case of primary lymphoma of bone of cervical localization. *Ital J Orthop Traumatol* 16: 405-409, 1990.
15. Baar J, Burkes RL, Bell R, Blackstein ME, Fernandes B and Langer F: Primary non-Hodgkin's lymphoma of bone. A clinicopathologic study. *Cancer* 73: 1194-1199, 1994.
16. Ebus SC, Bernsen HJ, Norel Van GJ and Donk R: Primary non-Hodgkin's lymphoma in multiple vertebrae presenting as a lumbar radicular syndrome: a case report. *Spine* 27: E271-E273, 2002.

17. Shehata WM, Meyer RL, Panke TL, Tew JM, Rath RK and Sammarco GJ: Primary lymphocytic lymphoma of the dorsal spine apparently cured by radiochemotherapy. *Spine* 11: 1035-1036, 1986.
18. Toussaint D, Massager N, Mathy L, Finet C, Vanderick J and Monseu G: Primary malignant lymphoma of the spine: clinical aspects and therapeutic advances [in French]. *Acta Orthop Belg* 65: 23-32, 1999.
19. Carbone PP, Kaplan HS, Musshoff K, Smithers DW and Tubiana M: Report of the committee on Hodgkin's disease staging. *Cancer Res* 31: 1860-1861, 1971.
20. Zinzani PL, Carrillo G, Ascani S, *et al*: Primary bone lymphoma: experience with 52 patients. *Haematologica* 88: 280-285, 2003.
21. Rathmell AJ, Gospodarowicz MK, Sutcliffe SB and Clark RM: Localized lymphoma of bone: prognostic factors and treatment recommendations. The Princess Margaret Hospital Lymphoma Group. *Br J Cancer* 66: 603-606, 1992.
22. Fidas P, Spiro I, Sobczak ML, *et al*: Long-term results of combined modality therapy in primary bone lymphomas. *Int J Radiat Oncol Biol Phys* 45: 1213-1218, 1999.
23. Baiocchi OC, Colleoni GW, Rodrigues CA, *et al*: Importance of combined-modality therapy for primary bone lymphoma. *Leuk Lymphoma* 44: 1837-1839, 2003.
24. Székely G, Miltényi Z, Mezey G, *et al*: Epidural malignant lymphomas of the spine: collected experiences with epidural malignant lymphomas of the spinal canal and their treatment. *Spinal Cord* 46: 278-281, 2008.
25. Pels H, Vogt I, Klockgether T and Schlegel U: Primary non-Hodgkin's lymphoma of the spinal cord. *Spine* 25: 2262-2264, 2000.
26. Laing RJ, Jakubowski J, Kunkler IH and Hancock BW: Primary spinal presentation of non-Hodgkin's lymphoma. A reappraisal of management and prognosis. *Spine* 17: 117-120, 1992.
27. Rubin P and Poulter C: spinal cord decompression of epidural lymphoma by rapid high doses of irradiation alone. *Radiol Clin North Am* 6: 106-109, 1968.
28. Marshall DT, Amdur RJ, Scarborough MT, Mendenhall NP and Virkus WW: Stage IE primary non-Hodgkin's lymphoma of bone. *Clin Orthop Relat Res* 405: 216-222, 2002.
29. Horsman JM, Thomas J, Hough R and Hancock BW: Primary bone lymphoma: a retrospective analysis. *Int J Oncol* 28: 1571-1575, 2006.