

Figure S1. Representative computed tomography imaging prior and subsequent to 2 cycles of chemotherapy in patients with lung cancer. Patient 1 was sensitive to chemotherapy. Patient 2 was resistant to chemotherapy.

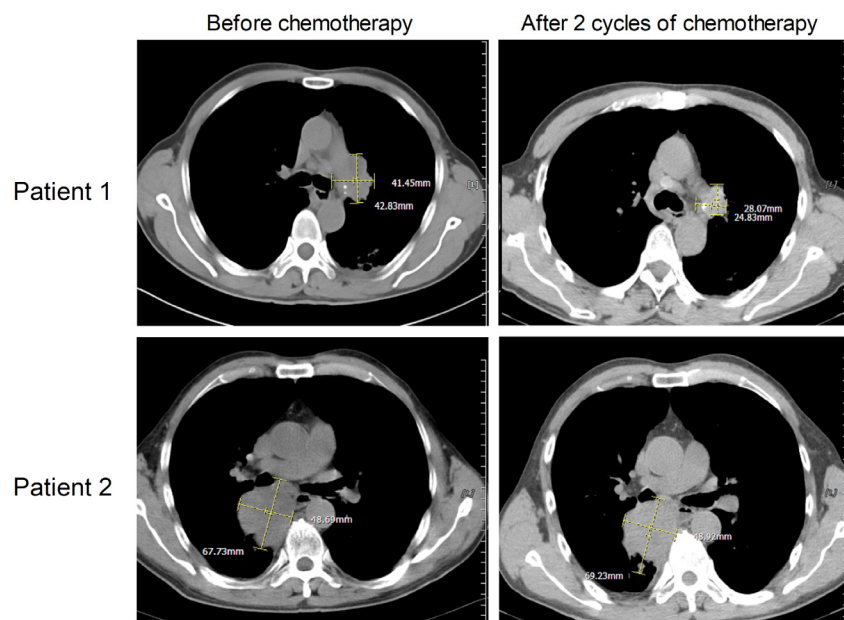


Figure S2. Representative immunohistochemical staining results of CA916798 prior and subsequent to 2 cycles of chemotherapy in lung cancer tissues. The positive staining of CA916798 protein was located in the cytoplasm with brown/yellow particles. Patient 3 was sensitive to chemotherapy and the positive staining of CA916798 protein was decreased after 2 cycles of chemotherapy. Patient 4 was resistant to chemotherapy and CA916798 protein was positively detected before and after chemotherapy.

