

Figure S1. CPS1 expression pattern in gastric carcinogenesis. Among the IM cases, 121 (100%) exhibited strong CPS1 expression; in low-grade IN, 70% (21/30) cases had strong positive and 9 (30%) cases had partially positive CPS1 expression; in high-grade IN, 4 (12.5%) cases exhibited strong, 7 (21.8%) exhibited focal positive, 7 (21.8%) exhibited weak and 14 (43.8%) exhibited no CPS1 expression. Among 172 patients with intestinal-type GC, 14 (8%) presented with strong positive, 14 (8%) had focal positive, 37 (22%) had weak and 107 (62%) had negative CPS1 expression. CPS1, carbamoyl phosphate synthetase 1; IM, intestinal metaplasia; IN, intraepithelial neoplasia; GC, gastric cancer.

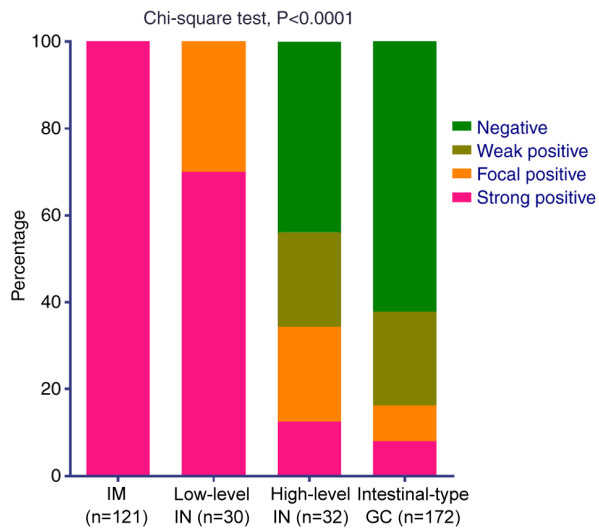


Figure S2. (A-C). OS of patients with (A) total, (B) intestinal-type and (C) diffuse-type GC according to CPS1 mRNA expression levels using probe 217564\_s\_at from the KMplot database. (D-F) PFS of patients with (D) total, (E) intestinal-type and (F) diffuse-type GC according to CPS1 mRNA expression levels using probe 217564\_s\_at from the KMplot database. CPS1, carbamoyl phosphate synthetase 1; GC, gastric cancer; KMplot, the Kaplan-Meier plotter; OS, overall survival; PFS, progression-free survival; HR, hazard ratio.

