

Figure S1. Sex and CT categorical characteristics were analyzed and compared in PAs, WTs and PCas. *P<0.05; **P<0.01; ***P<0.001. PA, pleomorphic adenoma; WT, Warthin tumor; PCa, parotid carcinoma; U/B, unilateral/bilateral; SL/DL, superficial lobe/deep lobe; VM, vascular marginalization; NINS, nodule-in-nodule sign; ELN, enlarged lymph nodes.

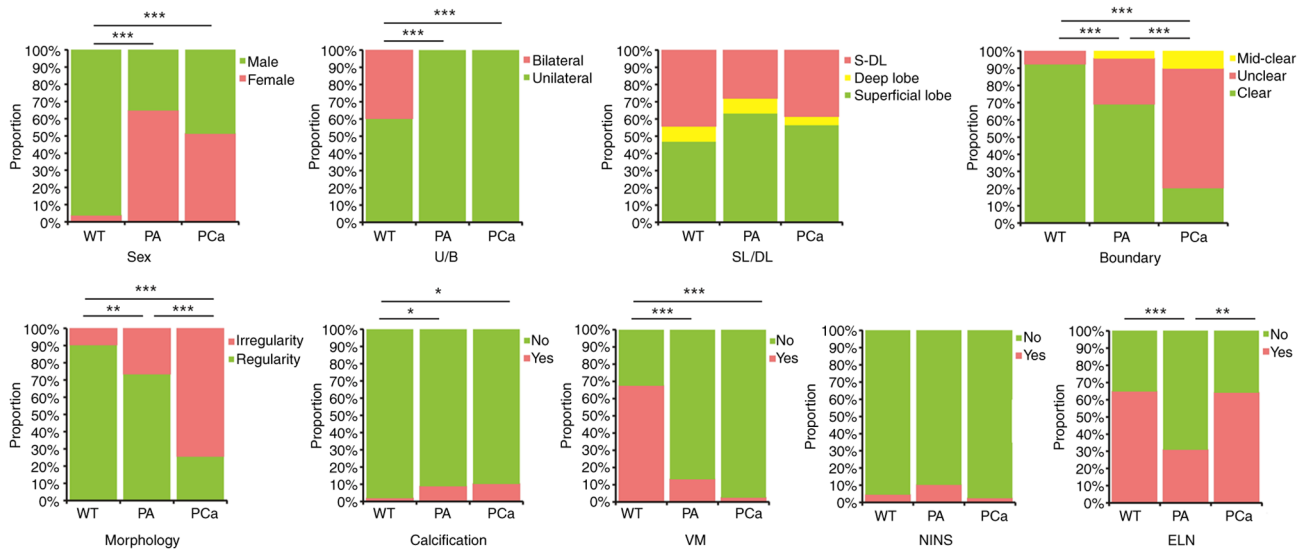


Figure S2. age and CT continuous characteristics were analyzed and compared among PAs, WTs and PCAs. *P<0.05; **P<0.01; ***P<0.001. PA, pleomorphic adenoma; WT, Warthin tumor; PCa, parotid carcinoma.

