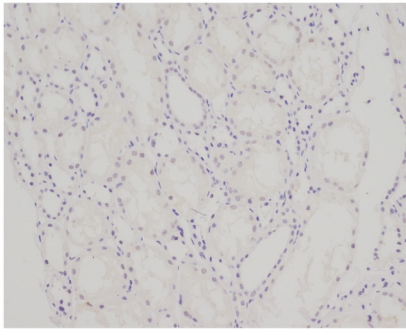
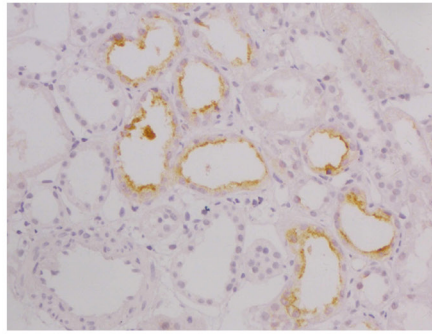


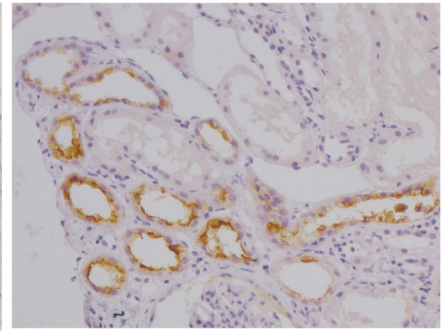
Figure S1. Representative KIM-1 immunohistochemistry images for T0, T1 and T2 stages (magnification x400; counterstained with hematoxylin; brown areas indicate positive staining). KIM-1, kidney injury molecule-1.



T0



T1



T2