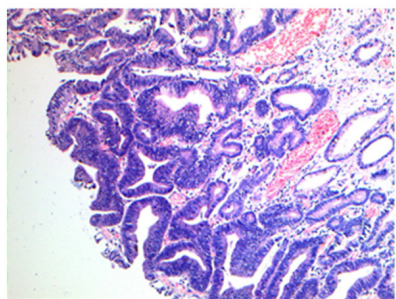
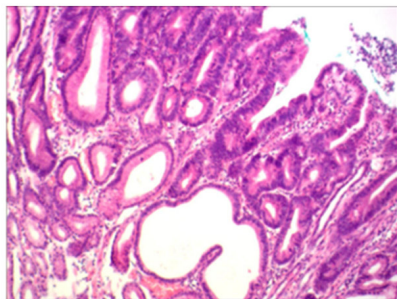


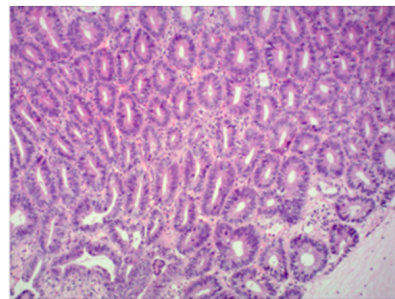
Figure S1. Pathological examination images of 5 patients with GHGIN. GHGIN, gastric high-grade intraepithelial neoplasia.



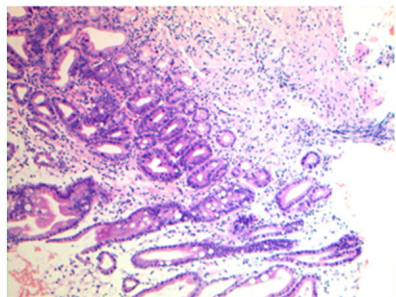
GHGIN1



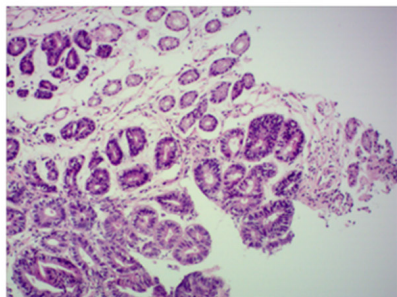
GHGIN2



GHGIN3



GHGIN4



GHGIN5