

Figure S1. Brain MRA scans obtained after (A) the first admission (day 1) and (B) the second admission (day 46). Brain MRA did not reveal any evidence of intracranial arterial stenosis or occlusion. MRA, magnetic resonance angiography.

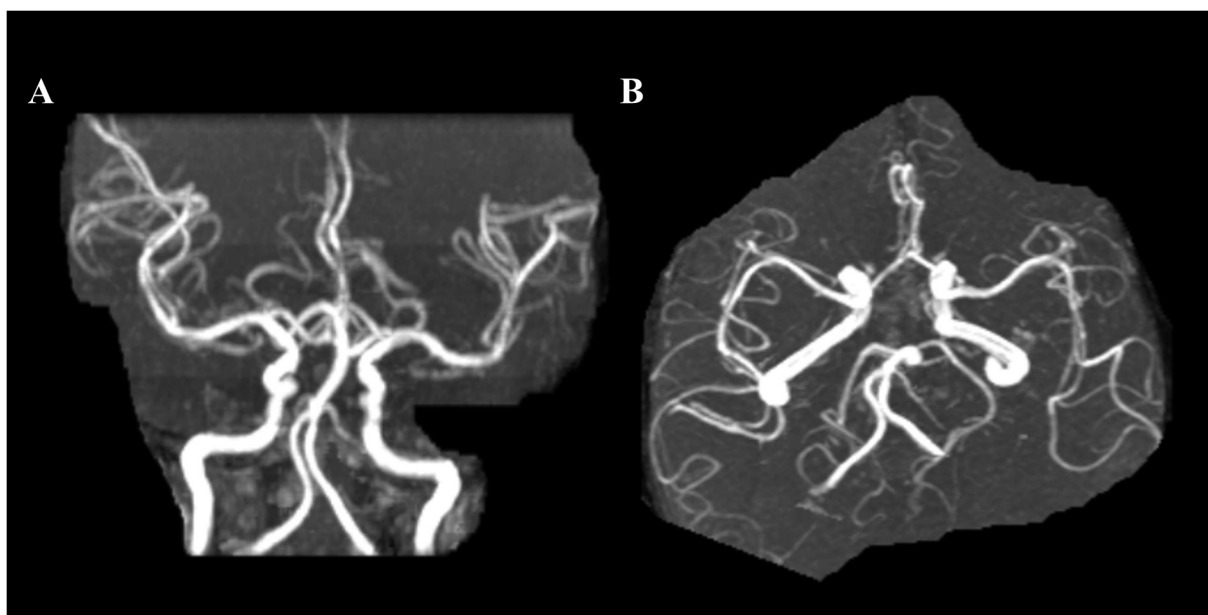


Figure S2. Genome analysis. Genome analysis demonstrated an adenine to guanine conversion at mitochondrial genome 3243.

