

Figure S1. Expression of Ki67 in case 2 and 3. (A) Initial surgery in case 2. (B) Recurrence of GCTB in case 2. (C) Malignant component in case 2. (D) Initial biopsy of case 3. (E) After embolization of case 3. (F) Recurrence of GCTB in case 3. (G) Malignant component in case 3. (H) Lung metastasis in case 3. Bar: 50 μ m. Arrowheads, Ki67-positive cells. GCTB, giant cell tumor of bone.

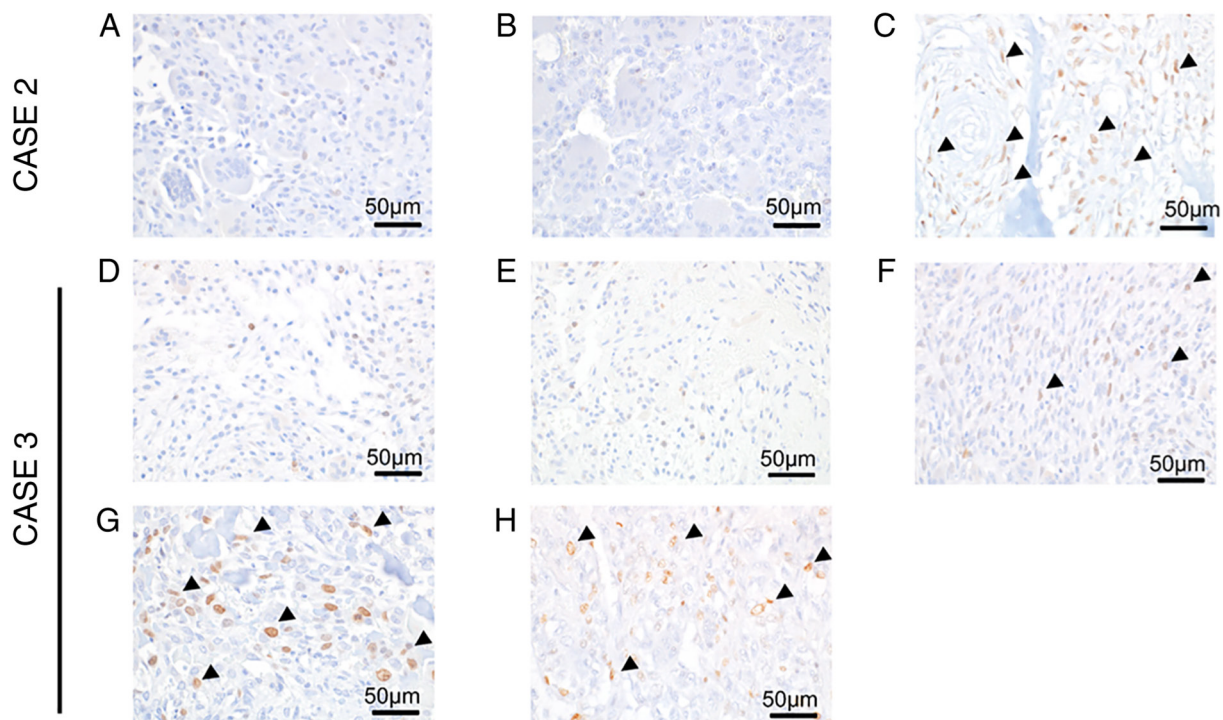


Figure S2. Expression of p53 in case 2 and 3. (A) Initial surgery in case 2. (B) Recurrence of GCTB in case 2. (C) Malignant component in case 2. (D) Initial biopsy of case 3. (E) After embolization of case 3. (F) Recurrence of GCTB in case 3. (G) Malignant component in case 3. (H) Lung metastasis in case 3. Bar: 50 μ m. Arrowheads, p53-positive cells. GCTB, giant cell tumor of bone.

