

Video S1: Video of hysteroscopy prior to tumor resection.

Video S2: Postoperative follow-up hysteroscopy video.

Figure S1. Positive staining of glycipan-3 (magnification, x10; scale bar, 100 μ m; immunohistochemical staining).

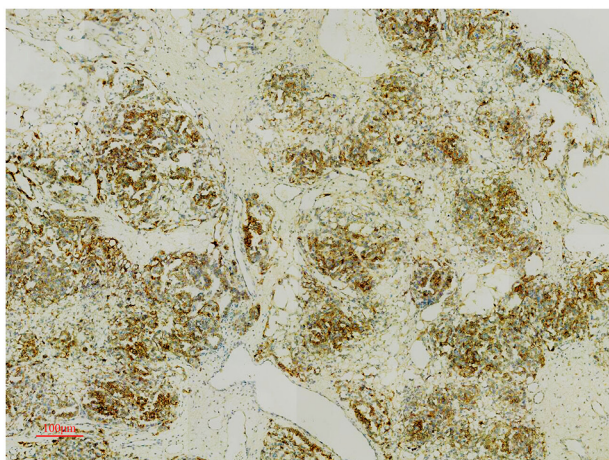


Figure S2. Positive staining of β -human chorionic gonadotropin (magnification, $\times 10$; scale bar, $100\ \mu\text{m}$; immunohistochemical staining).

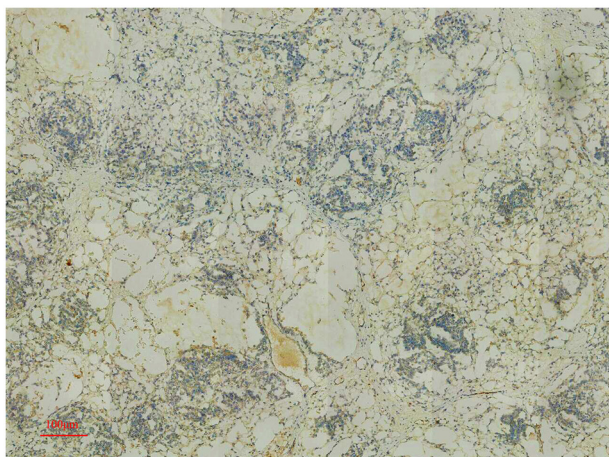


Figure S3. Positive staining of Sal-like protein 4 (magnification, x10; scale bar, 100 μ m; immunohistochemical staining).

