

Figure S1. Endoscopic ultrasound-guided fine needle aspiration image.

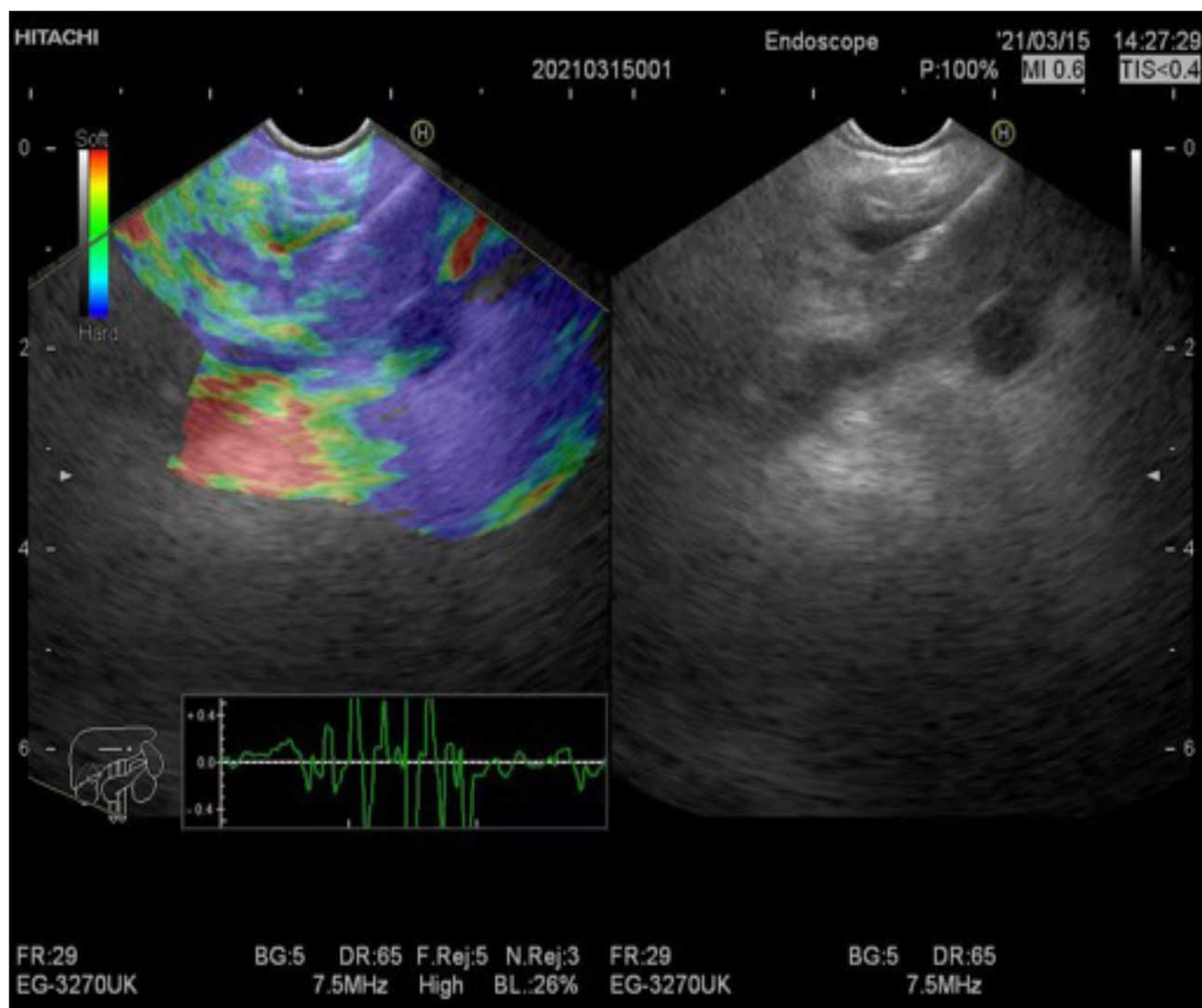


Figure S2. Histopathology of the endoscopic ultrasound-guided fine needle aspiration sample in a patient with pancreatic cancer (H&E; magnification, x200).

