

Figure S1. Color chest ultrasound, MRI and CT scan images. The areas circled in red are suspected tumor areas). Color chest ultrasound of the (A) left intramammary nodule, (B) Pre-operative changes in the left breast and (C) left breast lesion. (D) MIR images of the breast (E) Magnetic resonance dynamic enhancement silhouette of the patient. (F) Magnetic resonance dynamic enhancement time-one signal intensity curves in patients. (G) Chest CT scan. MRI, magnetic resonance imaging; CT, computed tomography.

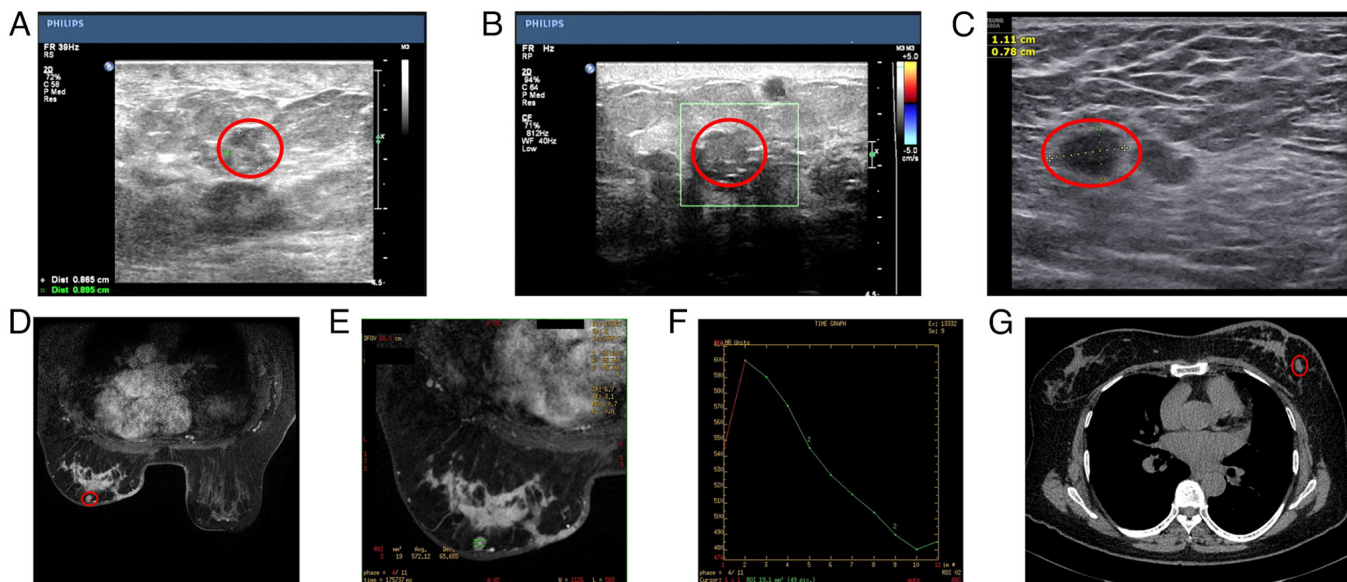


Figure S2. Chest CT and MRI results. (A) Multiple microscopic nodules in the lungs. (B) Review of multiple microscopic nodules in the lungs. (C) Lumbar spine MRI. (D) Chest CT. Nodes circled in red are suspected secondary metastases. MRI, magnetic resonance imaging; CT, computed tomography.

