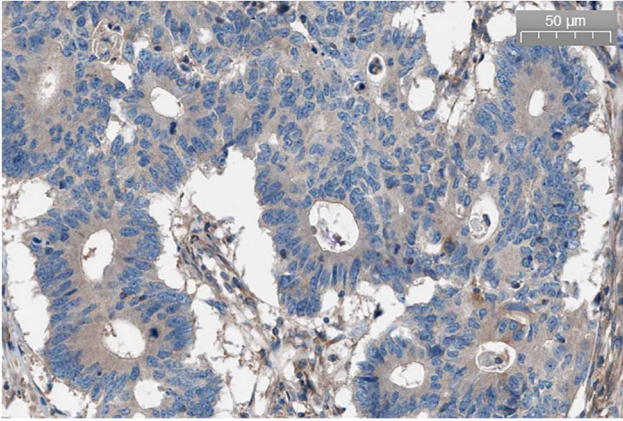


Figure S1. Representative staining images of AE1/AE3 immunohistochemistry. (A) Negative expression and (B) positive expression.

A



B

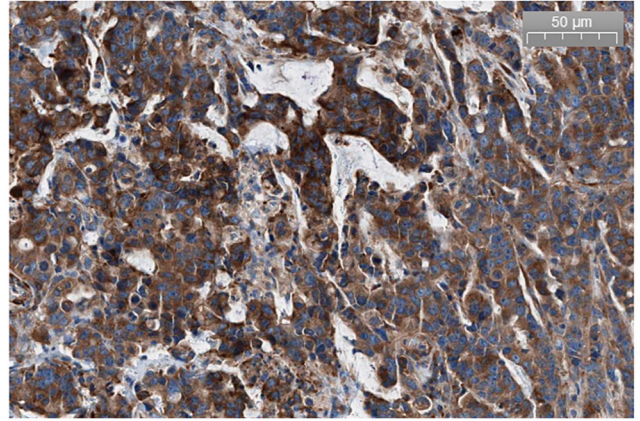


Figure S2. Survival curves of patients with colorectal neuroendocrine carcinoma in different age groups. (A) Disease free survival and (B) overall survival curves.

