

Figure S1. Additional grayscale abdominal ultrasound images of the gallbladder. The upper panel shows a longitudinal view of the gallbladder, again demonstrating the non-shadowing, non-mobile hyperechoic lesions of gallbladder polyposis for confirmation. The lower panel presents a transverse view of the gallbladder and adjacent hepatic parenchyma, showing no evidence of biliary tract dilatation or additional focal lesions.

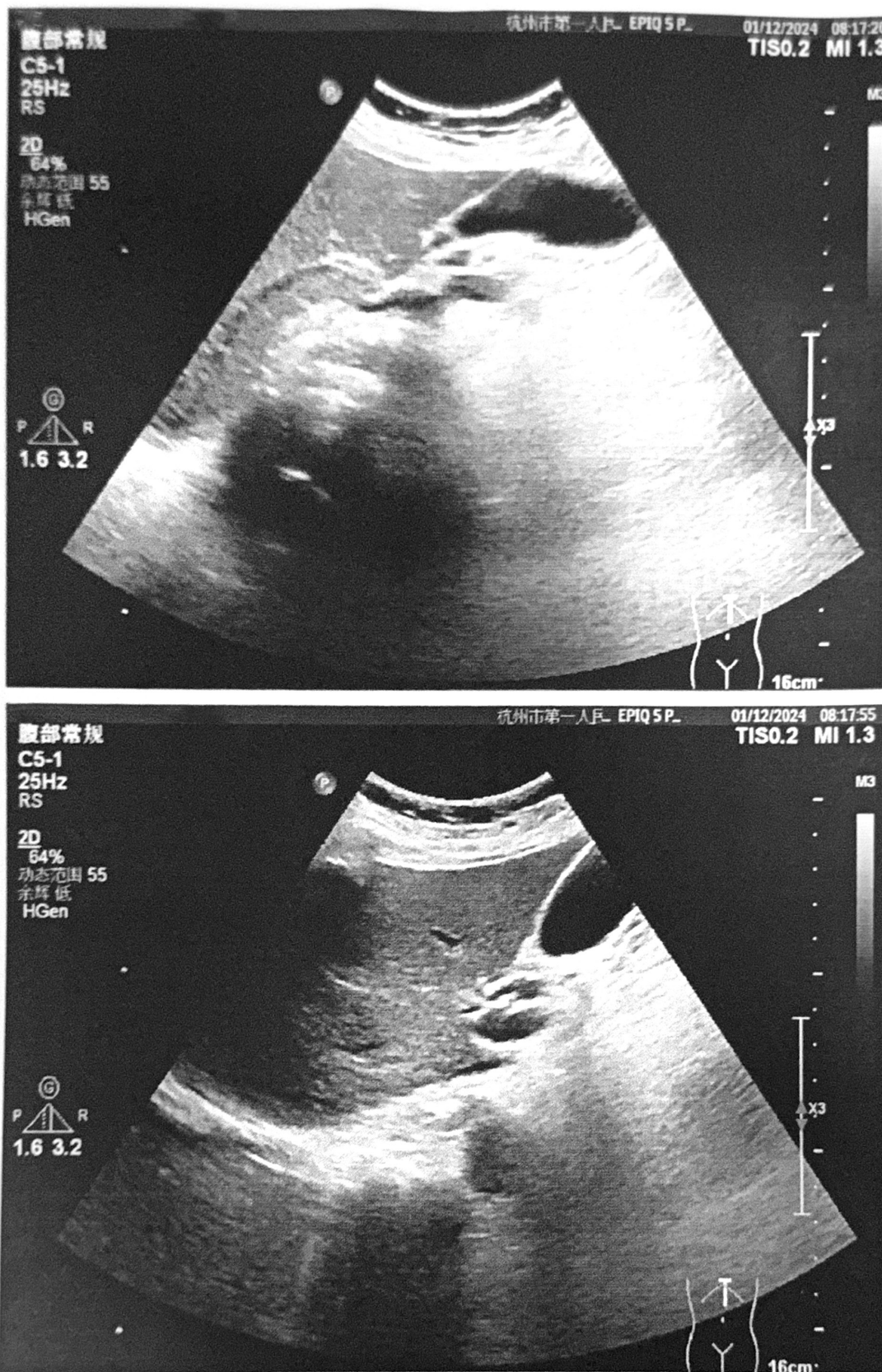


Figure S2. Grayscale abdominal ultrasound images of the gallbladder and right kidney. The upper panel shows a longitudinal view of the gallbladder, demonstrating non-shadowing, non-mobile hyperechoic lesions attached to the gallbladder mucosa, consistent with gallbladder polyposis. The lower panel presents a transverse view of the right kidney, with hyperechoic foci within the renal collecting system suggestive of nephrolithiasis, and a small anechoic fluid collection in the right costophrenic angle consistent with mild pleural effusion.

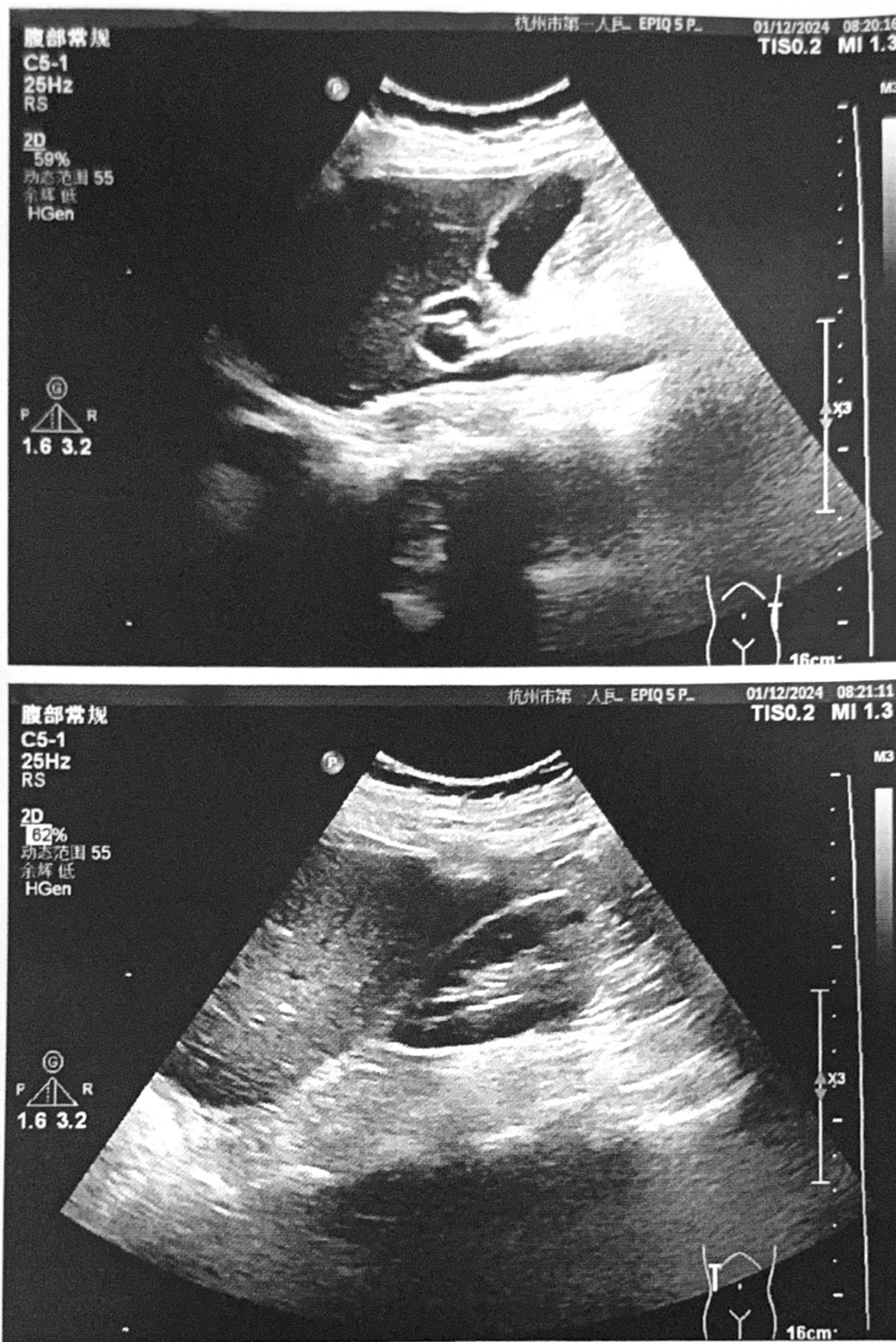


Figure S3. Chest CT showing bilateral lung lesions. This axial view at the level of the trachea demonstrates multiple infectious lesions distributed in both lungs, with some lesions showing a tendency toward chronic fibrosis. A focal area of increased attenuation is visualized in the left lower lobe, consistent with the described pathological changes. The central airways and mediastinal structures appear unremarkable at this slice level. CT, computed tomography.

